



Prophylactic heme arginate therapy in acute intermittent hepatic porphyria – a case report

Profilaktička terapija hem arginatom u akutnoj intermitentnoj hepatičkoj porfiriji

Žarko Krnetić*, Tatjana Pešić*, Željka Savić*†, Tatiana Jocić*, Olgica Latinović Bošnjak*, Vladimir Vračarić*, Dimitrije Damjanov*†

*University Clinical Center of Vojvodina, Clinic for Gastroenterology and Hepatology, Novi Sad, Serbia; †University of Novi Sad, Faculty of Medicine, Novi Sad, Serbia

Abstract

Introduction. Among the acute hepatic porphyrias, a small percentage of patients, predominantly female, present with recurrent cyclic attacks of acute intermittent porphyria that occur more than three times a year and sometimes at intervals of less than a month. In women, the attacks are typically related to the menstrual cycle, requiring several days of hospitalization and administration of heme arginate. For these patients, prophylactic heme arginate therapy may be the optimal treatment modality. **Case report.** We presented a 40-year-old female patient who has been suffering from porphyria for seventeen years. The first attack occurred in 2003, presenting with severe neurological symptoms, requiring the use of heme arginate (Normosang[®], Orphan Europe), which resulted in a favorable therapeutic response. In 2004 and 2007, gonadorelin analogue goserelin (Zoladex[®]) was used, but without beneficial effects on the course of the disease. In 2008, a preventive administration of heme arginate was initiated. The patient received heme arginate in the early phase of symptoms, every month in the premenstrual phase of the cycle, which resulted in milder symptoms, full recovery within 24 hours, lower doses of Normosang[®] (1-2 ampoules), and fewer hospital days (1-2 days) per month. This regimen has significantly improved the patient's quality of life and reduced the risk of potential adverse effects. **Conclusion.** Preventive use of Normosang[®] is the optimal therapeutic modality in patients with frequent, recurrent severe attacks that are unresponsive to other therapeutic regimens. As a result, patients have a better quality of life due to an effective, short-term, targeted treatment regimen.

Key words:

hem arginate; porphyrias; tertiary prevention; treatment outcome.

Apstrakt

Uvod. Među bolesnicima sa akutnim hepatičkim porfirijama niži procenat obolelih, uglavnom ženskog pola, ispoljava rekurentne ciklične napade akutne intermitentne porfirije, koji se javljaju više od tri puta godišnje, a ponekad i u intervalima kraćim od mesec dana. Kod žena su napadi uglavnom povezani sa menstrualnim ciklusom, zahtevaju po nekoliko dana hospitalizacije i terapiju hem arginatom. Za te bolesnike, preventivni režim davanja hem arginata može biti optimalan terapijski modalitet. **Prikaz bolesnika.** Prikazana je 40-godišnja bolesnica koja je 17 godina bolovala od porfirije. Prvi napad bolesti desio se 2003. godine i prezentovao se teškim neurološkim simptomima, što je zahtevalo primenu hem arginata (Normosang[®], Orphan Europe) sa povoljnim terapijskim odgovorom. Tokom 2004. i 2007. godine sprovedena je terapija analogom gonadorelina, goserelinom (Zoladex[®], Astrazeneca), ali bez povoljnog odgovora na tok bolesti. Tokom 2008. godine započeto je preventivno davanje hem arginata. Lek je davan u ranoj fazi simptoma, svakog meseca u premenstrualnoj fazi ciklusa, što je dovelo do ublažavanja simptoma bolesti, punog oporavka u toku 24 časa, uz smanjenje doza leka Normosang[®] (1–2 ampule) i kraćeg trajanja hospitalizacije (1–2 dana) mesečno. Tim režimom je značajno poboljšan kvalitet života bolesnice i snižen rizik od eventualnih neželjenih efekata leka. **Zaključak.** Preventivno davanje hem arginata je optimalan terapijski modalitet kod bolesnika sa čestim, rekurentnim, teškim napadima koji ne reaguju na druge terapijske mere. Kao rezultat, zahvaljujući kratkom i ciljanom terapijskom režimu, bolesnici imaju bolji kvalitet života.

Ključne reči:

hem arginat; porfirija; prevencija, tercijarna; lečenje, ishod.

Introduction

One of the precipitating factors of an attack in acute intermittent hepatic porphyria may be the physiological oscillation of female sex hormones during the premenstrual or luteal phase of the menstrual cycle¹. A small percentage of women have acute cyclical attacks occurring every month on average a few days before menstruation²⁻⁴. These are commonly severe forms of attacks that may be life-threatening and require hospitalization, intensive monitoring, and intravenous heme arginate therapy (Normosang®, Orphan Europe). In such patients, preventive administration of heme arginate may be the optimal therapeutic modality^{5,6}.

Case report

We presented a 40-year-old female patient who has been suffering from acute intermittent hepatic porphyria since 2003. The disease initially presented with severe acute seizure and neurological symptoms (grand mal epileptic seizures, status epilepticus, and coma). The patient's positive family history (mother had porphyria) indicated a qualitative urine test for porphobilinogen (Watson-Schwartz), and it was positive. A urinary porphyrin test was also done, showing elevated levels (15–25 times) of delta-aminolevulinic acid, coproporphyrin, uroporphyrin, and porphobilinogen (Table 1).

Genetic testing of HMBS and PEPT2 genes is unavailable in Serbia. It can be done only abroad, and it is extremely expensive; for that reason, and given the clear clinical picture, it was not done.

The patient was treated in the Intensive Care Unit with all supportive measures. Specific treatment with intravenous heme arginate (Normosang®) was initiated, which resulted in a favorable therapeutic response and complete recovery. After discharge, the patient had recurrent attacks in the premenstrual phase of the cycle, including myalgia and abdominal pain, requiring hospitalization. Since the problems continued despite administration of hypertonic glucose infusions and symptomatic replacement therapy, heme arginate treatment was continued. In the further course of the

disease, heme arginate appeared as the only effective treatment. The average duration of an acute attack was 5–7 hospital days per month, with the administration of 2–4 doses of heme arginate (one per day). Since the seizures were related to the luteal phase of the menstrual cycle, the use of gonadorelin analogue goserelin (Zoladex®, Astrazeneca) was attempted in order to induce amenorrhea but without beneficial effects on the course of the disease (the patient received a subcutaneous Zoladex® implant at a dose of 3.6 mg, once per month for 6 months, on two occasions in 2004 and 2007).

After five years of heme arginate treatment, a preventive application of the drug was initiated in 2008, every month in the premenstrual phase of the cycle and in the early phase of symptoms. This therapeutic regimen resulted in milder symptoms, lower urinary porphyrin levels (Tables 1 and 2), full recovery within 24 hours, and lower doses of Normosang® (1–2 ampoules). The patient received a dose of 250 mg of heme arginate, according to the manufacturer's instructions, through a Port-A-Cath system implanted in the jugular vein. Heme arginate was not given with albumin, nor was the heme/albumin molar ratio calculated. There were no complications such as phlebosclerosis or thrombophlebitis. This therapeutic response allowed a hospital stay of 1-day, with a lower dose of the drug. In this way, the patient's quality of life was significantly improved in the last ten years and reduced the risk of potential adverse effects.

All parameters of potential drug toxicity are documented and presented in annual reports to the manufacturer (Orphan Europe) (Tables 3 and 4) without complications related to the application of the drug, such as thrombophlebitis and phlebosclerosis.

The preventive regimen has proven to be more effective in several aspects. In the first five-year period of preventive use of heme arginate (2009–2013), the patient had 49 seizures that required 202 hospital days of treatment and 117 ampoules of Normosang®. In the second five-year period of preventive regimen (2014–2018), the patient had 52 seizures which required 227 days of hospitalization and 130 ampoules of Normosang®, as opposed to the five-year period (2004–

Table 1

Urinary porphyrin levels in the presented patient during the first attack and attack in the heme arginate treatment regimen

Porphyrins	First attack	Attack in treatment	Reference value
Coproporphyrin, mol/d	958	643	20–274
Delta aminolevulinic acid, mol/d	1,354	931	11.4–57.2
Uroporphyrin, mmol/d	107.8	483	4.8–60
Porphobilinogen	253	113.4	< 9

d – daily diuresis (24 h urine).

Table 2

Urinary porphyrin levels during the attack in the heme arginate preventive treatment regimen

Porphyrins	Prior to heme arginate use	After the first heme arginate dose
Coproporphyrin, (mol/d)	266	192.1
Delta aminolevulinic acid, (mol/d)	331	90.8
Uroporphyrin, (nmol/d)	186.5	148
Porphobilinogen, (nmol/d)	88.6	42.9

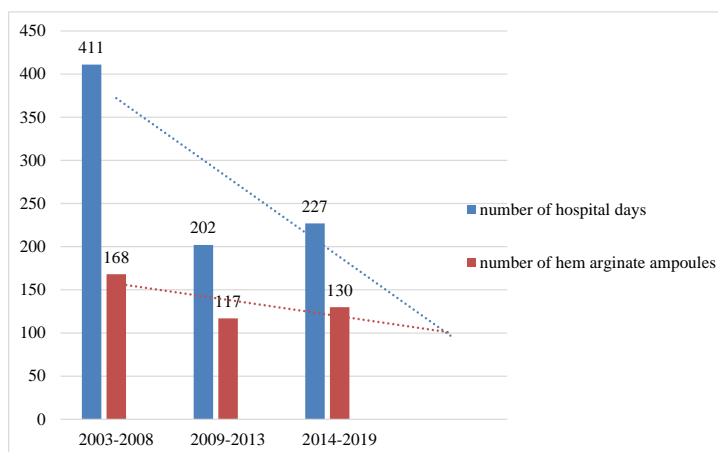
For porphyrins reference values see in Table 1.

Table 3**Biological parameters in the serum during preventive application of heme arginate**

Parameter	Average value	Reference values
Ferritin, µg/L	64.8	10–120
C-reactive protein, mg/L	0.3	0–5
Transferrine saturation, g/L	2.46	2–3.6
Iron, mmol/L	18.1	12.5–32.2
Gamma-glutamyltransferase, IU/L	10	1–55
Alanine aminotransferase, IU/L	16	5–40
Creatinine, mmol/L	91	30–127

Table 4**Cumulative dose and side effects of heme arginate given preventively**

Parameter	Values
Dose <i>per</i> infusion, mg	250
Number of courses	27
Total number of ampoules <i>per</i> year	28
Adverse drug reaction	No
Iron overload	No

**Fig. 1 – Total number of hospital days and heme arginate dosage during the three five-year periods (therapeutic and preventive regimens).**

2008) when heme arginate was the treatment regimen, which resulted in 56 seizures and 411 hospital days during which the patient received 168 ampoules of Normosang® (Figure 1).

Discussion

Cyclical attacks of acute intermittent hepatic porphyria associated with the menstrual cycle affect a small number of patients. Therefore, there is a lack of literature on the long-term treatment of such patients. Inducing amenorrhea in order to prevent seizures is one of the therapeutic modalities that may be applied^{4, 7, 8}. In the case of our patient, this therapy did not give favorable results in preventing seizures. In patients with cyclic forms of the disease who require intravenous administration of heme arginate during the attacks, there is a possibility of applying a preventive heme arginate regimen immediately before the expected period of discom-

fort²⁻⁴, which can give satisfactory therapeutic results in terms of reducing the intensity of attacks, shortening the hospital stay, and decreasing the total dose of heme arginate⁹. This regimen significantly reduces the risks of adverse drug reactions.

Conclusion

The presented case leads to the conclusion that preventive heme arginate therapy may be the optimal therapeutic modality in patients with cyclic attacks of acute intermittent porphyria precipitated by physiological hormonal oscillations during the premenstrual phase of the cycle, as well as in case of negative therapeutic response to other treatments. This therapeutic approach significantly reduces the intensity of seizures and improves the quality of life of patients due to shorter hospital stay and reduced risk of potential side effects of the drug.

R E F E R E N C E S

1. *Džambas D. Porphyrrias*. Novi Sad: Faculty of Medicine; 1988.
2. *Sassa S*. Modern diagnosis and management of porphyrias. *Br J Haematol* 2006; 135(3): 281–92.
3. *Anderson KE, Bloomer JR, Bonkowsky HL, Kushner JP, Pierach CA, Pimstone NR*, et al. Recommendations for the diagnosis and treatment of acute porphyrias. *Ann Intern Med* 2005; 142(6): 439–50.
4. European porphyria network. Treatment of the acute attack [Internet]. [cited 2020 Jun 28]. Available from: <https://porphyria.eu/en/content/treatment-acute-attack>
5. Recordati Rare Diseases. Normosang [Internet]. [cited 2020 Jun 28]. Available from: https://www.recordatirarediseases.com/sites/www.recordatirarediseases.com/files/inline-files/NOR_SmPC.pdf
6. *Ventura P, Cappellini MD, Rocchi E*. The acute porphyrias: a diagnostic and therapeutic challenge in internal and emergency medicine. *Intern Emerg Med* 2009; 4(4): 297–308.
7. *Anderson KE*. LHRH analogues for hormonal manipulation in acute intermittent porphyria. *Semin Hematol* 1989; 26(1): 10–5.
8. *Anderson KE, Spitz IM, Bardin CW, Kappas A*. A gonadotropin releasing hormone analogue prevents cyclical attacks of porphyria. *Arch Int Med* 1990; 150(7): 1469–74.
9. *Yarra P, Faust D, Bennett M, Rudnick S, Bonkowsky HL*. Benefits of prophylactic heme therapy in severe acute intermittent porphyria. *Mol Genet Metab Rep* 2019; 19: 100450.

Received on June 29, 2020
Revised on November 1, 2020
Accepted on February 1, 2021
Online First February 2021