



Traumatic mesenteric pseudocyst

Traumatska mezenterijalna pseudocista

Saša Micković*, Mihailo Bezmarević*, Irena Nikolić-Micković†,
Miroslav Mitrović*, Ivana Tufegdžić‡, Darko Mirković*§, Leposava Sekulović*||, Bratislav Trifunović*§

*Clinic for General Surgery, †Institute for Pathology, ‡Institute for Radiology, Military
Medical Academy, Belgrade, Serbia; †University Children's Hospital Belgrade,
Belgrade, Serbia; §Faculty of Medicine of the Military Medical Academy, University of
Defence, Belgrade, Serbia

Abstract

Introduction. Mesenteric pseudocysts have rarely been described in literature. They belong to a group of mesenteric cysts that are very rare intra-abdominal pathology regardless of the origin. The diagnosis is often difficult to make, because of the diversity of clinical symptoms. The definitive histopathological diagnosis determines the origin and further course of treatment. **Case report.** We reported a patient with post-traumatic mesenteric pseudocyst. It was localised on the mesenteric side, in the direct contact with the small intestine. We surgically removed the pseudocyst along with a part of the small intestine with success. The patient's recovery was eventless, with no complications. **Conclusion.** Only by complete cyst removal, the definitive, accurate histopathological diagnosis and classification can be made.

Key words:
mesentery; cystis; diagnosis, differential; digestive
system surgical procedures.

Apstrakt

Uvod. Pseudociste mezenterijuma veoma su retko opisivane u literaturi. One pripadaju grupi cista mezenterijuma koje su, bez obzira na poreklo nastanka, veoma retka intrabdominalna patologija. Dijagnoza je često teška zbog različitosti kliničke simptomatologije. Krajnja patohistološka dijagnoza određuje poreklo i dalji tok lečenja. **Prikaz bolesnika.** Prikazali smo bolesnika sa posttraumatskom mezenterijalnom pseudocistom, lokalizovanom na mezenterijalnoj strani u neposrednom kontaktu sa tankim crevom. Hirurški smo uspešno odstranili pseudocistu zajedno sa delom tankog creva. Oporavak bolesnika bio je uspešan. **Zaključak.** Definitivnu i tačnu patohistološku dijagnozu moguće je postaviti samo posle potpunog odstranjivanja ciste.

Ključne reči:
mezenterijum; ciste; dijagnoza, diferencijalna; hirurgija
digestivnog sistema, procedure.

Introduction

Mesenteric cysts are true rarities of intra-abdominal tumor pathology. They can be found along the entire mesentery of the small intestine, colon and rectum¹. Fluid-filled cysts are usually solitary, but may be multiple and/or multilocular also². The preoperative diagnosis is often difficult and unclear³. Clinically, they are usually presented as tumor mass in the abdomen. The most common symptoms are abdominal pain and disturbance of intestinal passage such as constipation and/or vomiting^{4,5}. The most common complications are ileus and volvulus⁶. Multi-slice computed tomography (MSCT) scan and ultrasonography (US) are proved to be the most successful diagnostic procedures⁷. There are many divisions and classifications of these cysts, but the most important and accurate one is histopathological^{8,9}. A successful method of treatment is surgery, either laparoscopic or open approach^{4,10}.

We presented a case with large mesenteric cyst caused by blunt abdominal injury in a car accident.

Case report

A 55-year-old man came to the internist due to a hypertensive crisis, with an arterial blood pressure (BP) value of 230/120 mmHg. The patient knew about his arterial hypertension, yet did not go to recall examinations nor took drugs regularly. Since he complained about mild abdominal pain, an abdominal US examination was performed revealing a tumor formation. Physical examinations confirmed the existence of the tumor in the left side of the abdomen, occupying the space of the left hypochondrium and the lateral quadrant of the mesogastrium. It was determined by palpation to be round-shaped, about 15 cm in diameter, slightly sensitive and painful. The laboratory findings including complete

blood count and clinical biochemistry tests were within normal range, with exception of cholesterol and triglycerides which were elevated. The patient started receiving antihypertensive therapy followed by normalization of BP. Repeated US confirmed tumor formation, which was seen as a hypoechoic cyst approximately 15×12 cm in diameter, with a hyperechoic wall and posterior amplification. MSCT scan showed a hypodense circular formation with hypoechoic content, which was in direct contact with the jejunal loops, unevenly thin with partially calcified wall, without a change in postcontrast attenuation. In the peritoneum and retroperitoneum no enlarged lymph nodes were found nor the presence of free intraperitoneal fluid (Figure 1). Irrigography excluded the possibility of infiltration of the colon, external compression of the caudal part of the transverse colon was seen, without lumen narrowing. The patient had no previous surgery. The patient stated a traffic accident two years ago, in which he received a blunt impact in the abdomen, without any significant consequences.

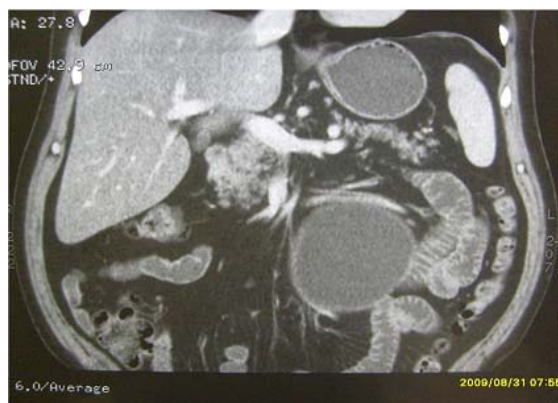

Fig. 1 – Cystic round formation in the close contact with jejunal loops on the frontal sections of multislice computed tomography abdominal scan.

The patient was operated on under general anaesthesia, with an open surgical approach, medial laparotomy. A tense, cystic and oval tumours change was found intraperitoneally, and a slightly tense wall, and direct contact to the proximal part of the jejunal mesentery (Figure 2). The unilocular cyst

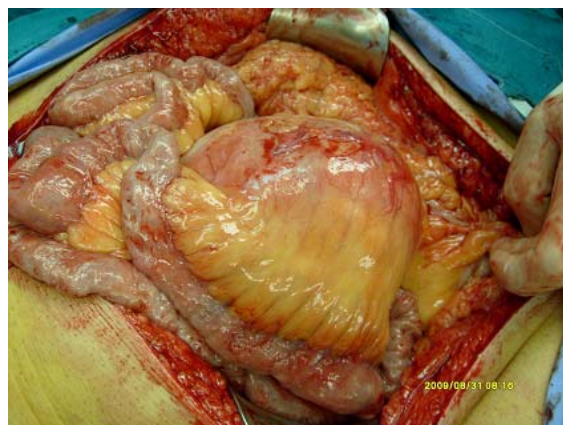


Fig. 2 – Intraoperative findings of a solitary unilocular mesenteric cyst.

contained a residual viscous mass similar to milk. An attempt of enucleation was compromised by the vascularization of the jejunum, so partial resection of the jejunum along with the cyst was performed (Figure 3). The continuity of the small intestine was established by end-to-end anastomosis. The postoperative course was eventless. The patient was introduced to peroral food intake on the postoperative day 2 and abdominal drain was removed 4 days after the surgery. The biochemical content of the cysts showed no presence of amylase, while the level of cholesterol and triglycerides was high, and the microbiological culture was sterile.

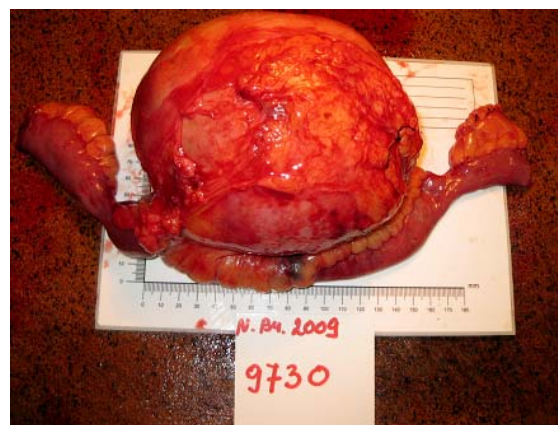

Fig. 3 – A specimen of extirpated unilocular mesenteric cyst with a jejunal loop and thin and smooth wall.

The definitive histopathological examination showed that the wall of macroscopic tumor formation was formed from multiplied acellular connective tissue, and on its outer side an adipose tissue were found. The connective tissue was impregnated with small groups of lymphocytes, as well as foci of calcification. Groups of foamy histiocytes were located on the inner surface. The presence of epithelium was not found (Figure 4). Amorphous eosinophilic material impregnated with small groups of lymphocytes siderophages was located in the lumen. The findings corresponded to the mesenteric pseudocyst.

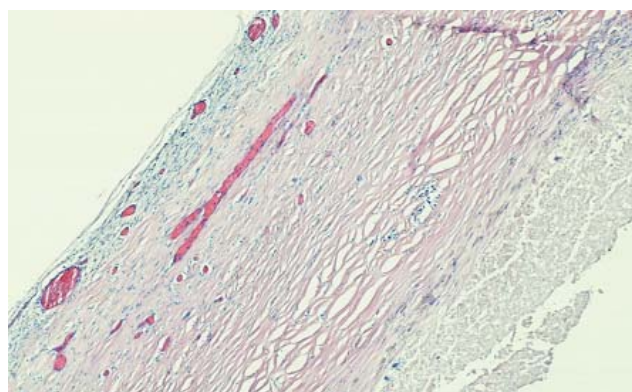


Fig. 4 – Pseudocyst wall consists of multiplied acellular connective tissue, and on its outer side, adipose tissue, while the connective tissue is impregnated with small groups of lymphocytes, as well as foci of calcification. The epithelium was not found (HE, $\times 5$).

Discussion

Benivieni, a Florentine anatomist, first described a mesenteric cyst in 1507, during the autopsy of an 8-year-old boy¹¹. The first resection of a cyst was performed in 1880 by Tillaux and Millard¹². The first successful laparoscopic resection was presented in 1993 by Mackenzie et al¹³. The original classification divides cysts into 4 categories¹⁴: embryonic, traumatic, neoplastic and infectious. This division clearly indicates the etiology of cyst formation. There are different classifications of cysts, but certainly, the most reliable are histological and immune histopathological classifications, which divide cysts into several groups^{8,9}. In 2000 de Perot et al.⁸ proposed a 6-group classification based on histopathology: lymphatic cysts (simple lymphatic cyst and lymphangioma); mesothelial cysts (simple mesothelial cyst, benign cystic mesothelioma, and malignant cystic mesothelioma); enteric cysts (including enteric duplication cyst); urogenital cysts; mature cystic teratoma (dermoid cysts); and pseudocysts (infectious and traumatic cysts).

Several years later a new classification was proposed, based on immunohistochemical findings, as a better prognostic predictor of biological behaviour⁹.

Traumatic cysts are relatively rare in intact blunt abdominal traumas, and only several cases are described in the literature¹⁵⁻¹⁷. They are the result of mesenteric lymphangitis and rupture or hematoma with subsequent resorption and cystic degeneration in most cases¹⁵. They can be found along the entire mesentery of the small intestine, colon and rectum. They can also be found in the omentum and retroperitoneum. Cysts are usually solitary, but may be multiple and/or multilocular. In any case, whether they are mesenteric, omental or retroperitoneal, the cysts originate from the same embryonic structures^{2,3,18}. The content of the cyst can be chylous, bloody or purulent^{6,14,15,18}. It is clear that only traumatic and infectious pseudocysts do not have epithelium, resemble a pancreatic pseudocyst. The size of cysts may range from a few centimeters up to 10–15 cm⁷, as in the presented case, with the literature refers the size of up to 36 cm in diameter².

The incidence of mesenteric and omental cysts is low; it is higher in the cases of paediatric hospitalized patients and it is approximately 1/20,000, comparing to the adult population which is about 1/140,000^{2,19,20}. In cases of traumatic pseudocysts, considering the incidental etiology, the frequency is unknown. Clinical symptoms are nearly always nonspecific, and presented as intra-abdominal tumor formation which is often incidentally discovered during abdominal US, with exception of uncomplicated cysts. Depending on localisation, they can mimic a pancreatic pseudocyst often, small intestine tumor, or paraovarian cyst^{4,5}. The most common symptoms are abdominal pain and disturbance of intestinal passage, while the most common complications are cyst torsion, rupture and ileus of the small intestine or the colon⁶. In such cases, acute abdominal condition exists, where it is almost impossible to determine the preoperative diagnosis. Unlike adults who can have asymptomatic cysts, children usually have symptomatic cysts which are often presented as an acute abdominal condition

²¹. US is certainly the most reliable method for preoperative diagnosis⁷, but CT scan is very helpful and should be the integral part of preoperative staging. Magnetic resonance imaging can also be helpful in unclear cases¹⁵.

The method of successful treatment is surgical one, which can be open or minimally invasive, such as laparoscopic approach. This kind of surgical method can be applied even in emergency cases when the preoperative diagnosis is accurate^{4,10}. The classical surgical way of cyst solving involves simplex drainage, enucleation, resection or marsupialisation (not suitable because of the possibility of infection and relapse)². Applied surgical method depends on urgency, cyst's localisation, surgeon's experience and the existence of complications such as rupture or volvulus. In our case, we applied the open surgical approach, since the preoperative findings showed that the cyst's wall was in direct contact with the wall of the small intestine. Intraoperatively, we excluded enucleation due to compromising vascularisation of the small intestine. The most favourable surgical procedure for cyst solving is enucleation, but in every third case resection is required. Resection is necessary in adults usually, while in children it is required in 50% of cases of mesenteric cysts^{2,18,22}. However, resection is a method of curative treatment and the laparoscopic approach is the method of choice, as a minimally invasive technique^{10,23}. In most cases, complete resection of cysts usually ends up without intraoperative and postoperative complications. Cyst recurrence is possible in cases with partial resection. The literature describes cases of cyst recurrence after laparoscopic approach²⁴. A case of malignant transformations of mesenteric cysts has also been described^{2,25}. In these cases, surgical treatment is undoubtedly needed.

The presented patient informed us about abdominal injury that indicated the traumatic origin of abdominal mass formation. Mesenteric injury probably caused a rupture of small blood vessels with bleeding which spontaneously stopped. After a subsequent resorption of hematoma the pseudocyst remained. Another possible cause of the pseudocyst could be a rupture of lymph vessels with gradual chylous leakage. However, macroscopical findings of viscous fluid similar to milk into pseudocyst, and the presence of siderophages on histopathological examination in the pseudocyst's lumen supported the first pathophysiologic mechanism of pseudocyst evolution. Imaging procedures were helpful, although the definitive diagnosis was made only after cyst extirpation and histological examination.

Conclusion

A traumatic mesenteric cyst is a very rare abdominal pathological finding. Surgical treatment is the method of choice, either open or by the laparoscopic approach. Both techniques are used with equal success. The definite and accurate histopathological diagnosis can be made only by complete cyst removal as in the presented case.

Conflict of interest statement

There was no conflict of interest among the authors.

R E F E R E N C E S

1. Saviano MS, Fundaro S, Gelmini R, Begossi G, Perrone S, Farinetti A, et al. Mesenteric cystic neoformations: Report of two cases. *Surg Today* 1999; 29(2): 174–7.
2. Kurtz RJ, Heimann TM, Beck RA, Holt J. Mesenteric and Retroperitoneal Cysts. *Ann Surg* 1986; 203(1): 109–12.
3. Steinreich OS. The Diagnosis of Mesenteric Cysts. *Ann Surg* 1955; 142(5): 889–94.
4. Theodoridis TD, Zepiridis L, Athanatos D, Tzeveleakis F, Kellartzis D, Bontis JN. Laparoscopic management of mesenteric cyst: a case report. *Cases J* 2009; 2(1): 132.
5. Mickovic S, Mitrovic M, Stankovic N, Bezmarevic M, Jovanovic M, Mirkovic D, et al. Splenic artery pseudoaneurysm as a complication of pancreatic pseudocyst. *Vojnosanit Pregl* 2011; 68(7): 602–6.
6. Losanoff JE, Kjossev KT. Mesenteric cystic lymphangioma: unusual cause of intra-abdominal catastrophe in an adult. *Int J Clin Pract* 2005; 59(8): 986–7.
7. Sato M, Ishida H, Konno K, Komatsuda T, Konno S, Watanabe S, et al. Mesenteric cyst: sonographic findings. *Abdom Imaging* 2000; 25(3): 306–10.
8. de Perrot M, Bründler M, Totsch M, Mentha G, Morel P. Mesenteric Cysts. *Dig Surg* 2000; 17(4): 323–8.
9. Hitti IF, Savicki JL, Powers CJ, Heimowitz H, Ward RJ. A new classification for mesenteric omental cysts. *Contemporary surgery* 2008; 64(11): 529–34.
10. Trompetas V, Varsamidakis N. Laparoscopic management of mesenteric cysts. *Surg Endosc* 2003; 17(12): 2036.
11. Braquehay J. Des kystes du mesentery. *Arch Gen* 1892; 170: 291.
12. Tilau P, Millard P. Cyst du mesentere chez une home. *Bull Acad Med* 1880; 7: 831.
13. Mackenzie DJ, Shapiro SJ, Gordon LA, Ress R. Laparoscopic excision of a mesenteric cyst. *J Laparoendosc Surg* 1993; 3(3): 295–9.
14. Beabrs OH, Judd ESJ, Dockerty MB. Chylous cysts of the abdomen. *Surg Clin North Am* 1950; 30(4): 1081–96.
15. Falidas E, Mathionlakis S, Vlachos K, Pavlakis E, Anyfantakis G, Villias C. Traumatic mesenteric cyst after blunt abdominal trauma. *Int J Surg Case Rep* 2011; 2(6): 159–62.
16. Sozi TA, Levin IR. A case of gigantic post-traumatic multichambered cyst of the sigmoid mesentery in a 10-year-old child. *Vestn Rentgenol Radiol* 1970; 45(5): 95–6.
17. Sikora Z, Rybski J. Case of traumatic cyst of intestinal mesentery in a child. *Pol Przegl Chir* 1977; 49(2): 157–8. (Polish)
18. Gmijovic D, Jeremic M, Stojanovic M, Radojkovic M. Mesenteric cysts. *Acta Fac Med Naiss* 2007; 24: 189–94.
19. Takiff H. Mesenteric Cysts and Intra-abdominal Cystic Lymphangiomas. *Arch Surg* 1985; 120(11): 1266–9.
20. Vanek VW, Phillips AK. Retroperitoneal, Mesenteric, and Omental Cysts. *Arch Surg* 1984; 119(7): 838–42.
21. Porras-Ramirez G, Hernandez-Herrera HM. Hemorrhage into mesenteric cyst following trauma as a cause of acute abdomen. *J Pediatr Surg* 1991; 26(7): 847–8.
22. Kosir MA, Sonnino RE, Gauderer ML. Pediatric abdominal lymphangiomas: A plea for early recognition. *J Pediatr Surg* 1991; 26(11): 1309–13.
23. Dequanter D, Lefebvre JC, Belva P, Takieddine M, Vaneukem P. Mesenteric cysts. A case treated by laparoscopy and a review of the literature. *Surg Endosc* 2002; 16(10): 1493.
24. Shamiyeh A, Rieger R, Schrenk P, Wayand W. Role of laparoscopic surgery in treatment of mesenteric cysts. *Surg Endosc* 1999; 13(9): 937–9.
25. Bury TF, Pricolo VE. Malignant transformation of benign mesenteric cyst. *Am J Gastroenterol* 1994; 89(11): 2085–7.

Received on November 16, 2012.

Revised on April 19, 2013.

Accepted on April 22, 2013.

OnLine-First April, 2014.