



The relationship between perifoveal capillary ring alterations and visual acuity in diabetic retinopathy

Povezanost promena perifovealnog kapilarnog prstena i oštine vida u dijabetesnoj retinopatiji

Nenad Petrović*†, Dušan Todorović*†, Sunčica Srečković*†, Tatjana Šarenac Vulović*†, Svetlana Jovanović*†, Svetlana Paunović*, Dejan Vulović‡§, Danijela Randjelović^{||}

University Clinical Center Kragujevac, *Clinic for Ophthalmology, †Center for Plastic Surgery, Kragujevac, Serbia; University of Kragujevac, Faculty of Medical Sciences, ‡Department of Ophthalmology, §Department of Surgery, Kragujevac, Serbia; ^{||}Aero Medical Institute, Clinic for Ophthalmology, Zemun, Serbia

Abstract

Background/Aim. The relationship between the foveal avascular zone (FAV) and visual acuity (VA) in retinal diseases remains a matter of discussion. The aim of this study was to determine the impact of diabetic macular ischemia (DMI) on VA through the analysis of the perifoveal capillary network in various stages of diabetic retinopathy - DR (non-proliferative diabetic retinopathy – NPDR and proliferative diabetic retinopathy – PDR). **Methods.** Qualitative and quantitative analysis of 143 angiograms of patients with different stages of DR was performed. The degree of macular ischemia was assessed by the analysis of 2 parameters: perifoveal capillary ring, *z*, the FAZ outline irregularity, and capillary loss. Finally, a comparison was made between the degree of macular ischemia with the best-corrected VA, depending on macular thickness. **Results.** In the eyes with mild and moderate NPDR, without significant macular thickening, no statistically significant decrease in VA caused by macular ischemia was noticed ($p = 0.81$). Opposite, in a subgroup with severe NPDR and PDR, without significant macular thickening, a statistically significant difference was presented among eyes with moderate and severe macular is-

chemia compared to eyes with lower grades of macular ischemia ($p = 0.021$ and $p = 0.018$, respectively). In the eyes with moderate NPDR and mild macular ischemia, the increase in macular thickness resulted in a statistically insignificant decrease in VA compared to eyes with a normal macular thickness ($p = 0.088$). However, in the eyes with severe NPDR, every pathological increase in macular thickness caused a statistically significant decrease in VA, regardless of the degree of macular ischemia ($p = 0.018$ – 0.040). A similar relationship was also found in the eyes with PDR ($p = 0.017$ – 0.042). In the eyes with a statistically significant decrease in VA, most of the examined eyes (98%) had the FAZ outline irregularity in the nasal perifoveal subfield. **Conclusion.** In the absence of significant macular thickening, the destruction of one-half of the perifoveal capillary network, or greater, is associated with reduced VA. The location of macular ischemic changes in the nasal parts of the perifoveal capillary ring plays a crucial role in its effects on visual function.

Key words: diabetic retinopathy; fluorescein angiography; ischemia; macula; retina; visual acuity.

Apstrakt

Uvod/Cilj. Povezanost fovealne avaslarne zone (FAZ) i oštine vida (OV) u bolestima mrežnjače i dalje je predmet debata. Cilj rada bio je da se utvrdi uticaj dijabetesne makularne ishemije (DMI) na OV, analizom perifovealne kapilarne mreže u različitim fazama dijabetesne retinopatije – DR (neproliferativna DR – NPDR i proliferativna DR – PDR). **Metode.** Izvršena je kvalitativna i kvantitativna analiza 143 angiograma bolesnika sa različitim stadijumima DR. Stepenn makularne ishemije procenjen je analizom 2

parametra: perifovealnog kapilarnog prstena, tj. nepravilnostima oboda FAZ i stepena kapilarnog gubitka. Na kraju je izvršeno poređenje između stepena makularne ishemije i najbolje korigovane OV, u zavisnosti od makularne debljine. **Rezultati.** Kod očiju sa blagom i umerenom NPDR i bez značajnog zadebljanja makule, nije uočen statistički značajan pad OV izazvan makularnom ishemijom ($p = 0,81$). Nasuprot tome, kod očiju sa ozbiljnom NPDR i PDR, bez značajnog zadebljanja makule, utvrđena je statistički značajna razlika u OV kod očiju sa umerenom i ozbiljnom makularnom ishemijom u poređenju

sa očima gde je makularna ishemija bila manjeg stepena ($p = 0,021$ i $p = 0,018$, redom). Kod očiju sa ozbiljnom NPDR i blagom makularnom ishemijom, povećanje debljine makule rezultiralo je statistički neznačajnim smanjenjem OV u poređenju sa očima sa normalnom debljinom makule ($p = 0,088$). Međutim, kod očiju sa ozbiljnom NPDR, svako patološko povećanje debljine makule izazivalo je statistički značajno smanjenje OV, bez obzira na stepen makularne ishemije ($p = 0,018-0,040$). Slična povezanost je takođe pronađena kod očiju sa PDR ($p = 0,017-0,042$). Kod očiju sa statistički značajnim smanjenjem OV, većina njih (98%) imala

je iregularnost FAZ konture u nazalnom perifovealnom subpolju. **Zaključak.** U odsustvu značajnog zadebljanja makule, destrukcija polovine oboda perifovealne kapilarne mreže ili više, povezana je sa smanjenom OV. Lokalizacija makularnih ishemijskih promena u nazalnim delovima perifovealnog kapilarnog prstena igra presudnu ulogu u njihovom efektu na funkciju vida.

Ključne reči:
dijabetesna retinopatija; angiografija, fluoresceinska; ishemija; žuta mrlja; mrežnjača; vid, oština.

Introduction

Diabetic retinopathy (DR) is the leading cause of vision loss in working, active adults. Diabetic macular edema (DME) is defined as the thickening of the macula that occurs due to an abnormal accumulation of edematous fluid in the retinal tissue. This progressively changes the anatomy of the macula and leads to progressive, irreversible photoreceptor degradation and vision loss. The degree of macular thickening is significantly correlated with visual acuity (VA). DME represents the most common cause of vision loss in patients affected by diabetes mellitus (DM), especially in type 2 diabetes¹. The Early Treatment Diabetic Retinopathy Study defined "clinically significant macular edema"; this definition was introduced to indicate the involvement of the center of the macula and its relationship to visual loss².

The macula has one of the highest metabolic intensities per gram of tissue in the body³. The outer retinal layers are completely avascular and are dependent on metabolic support by diffusion from the choroidal vascular beds. The inner retina is predominantly supplied by the retinal circulation. The histologic findings have identified three different retinal capillary plexuses in the macular area: the superficial, the deep, and the intermediate capillary plexuses. The vessels in the nerve fiber layer and the ganglion cell layer form the superficial capillary plexus (SCP), while the inner and outer plexiform layers receive blood from the deep capillary plexus (DCP) located in the junction between them^{4,5}.

The very center of the macula, the foveola, is mostly avascular and corresponds approximately to the foveal avascular zone (FAZ), which represents the capillary-free zone. The avascular region of the FAZ is surrounded by terminal capillaries forming a perifoveal capillary ring that often has an oval shape with a mean diameter of $362.3 \pm 49.7 \mu\text{m}$ vertically and $410.8 \pm 80.7 \mu\text{m}$ horizontally⁴.

The size of the FAZ has been intensively studied both in the healthy eyes and in many retinal disorders. Many studies have shown that the size of the FAZ in normal human eyes can be very variable. In healthy eyes, there are large individual variations in the size of the FAZ, ranging between 0.05 up to 1.98 mm^2 ⁶⁻⁸. Therefore, the correlation between the size of the FAZ and VA in the normal human eye has not been fully established yet. In healthy eyes, the size of the FAZ does not seem to influence visual function⁹.

Macular edema is frequently associated with relative ischemia. Diabetic macular ischemia (DMI) is characterized by the occlusion and loss of the macular capillary network¹⁰. The health and integrity of the capillaries are essential for ganglion cell survival. The persistent ischemia of both the SCP and DCP may evolve into permanent neurosensory damage¹¹.

Clinically, macular ischemia (MI) is recognized by two characteristics: enlargement or irregularity of the FAZ and widening of the intercapillary spaces in the perifoveal area due to the capillary dropouts^{12,13}. MI can occur with or without macular edema, but it is very rare to find an isolated case of DMI.

Many studies have observed the increase of the FAZ area in the eyes with DR^{7,14,15}. Some studies have reported that the relationship between the FAZ size and DMI severity occurs from the earliest stages of DR, non-proliferative DR (NPDR), while others have observed this relationship only in more advanced diseases^{7,15-17}. It is shown that the rate of the FAZ enlargement ranged between 5% and 10% of the baseline FAZ area per year in the eyes with diabetic MI¹⁸.

The relationship between the FAZ size and VA in retinal diseases remains a matter of discussion. The effects of DMI on visual function are ill-defined. Some patients maintain VA near to normal levels in the presence of profound ischemia. Evidence of enlargement of the FAZ greater than $1,000 \mu\text{m}$ generally indicates visual loss¹⁹.

Historically, since its introduction in the 1960s, conventional fluorescein angiography (FA) has been the gold standard procedure for evaluating the degree of DMI in patients with DR¹². This technique typically shows enlargement and irregular shape of the FAZ, interruptions of the perifoveal capillary ring, and large areas of retinal hypofluorescence due to the absence of macular capillaries²⁰.

While previous studies have focused mainly on investigating changes in the size and shape of the FAZ in MI, this study primarily analyzes changes in the perifoveal capillary ring to determine whether its alterations may be a good indicator of the ischemic process.

Methods

The study was conducted at the Clinic for Ophthalmology, University Clinical Center Kragujevac, Serbia. It was designed as a retrospective, cross-sectional study. We performed a qualitative and quantitative analysis of 143 angiograms of patients with different stages of DR. In these pa-

tients, the diagnostic procedure of fluorescein angiography was performed from 2008 to 2019. The study included 123 patients: angiograms of only one eye were analyzed in 103 patients, and angiograms of both eyes in 20 patients.

The main inclusion criterion was the existence of DR. Patients with cataract, high refractive error, corneal leucoma, vitreal hemorrhage, glaucoma, uveitis, previous ocular surgery or trauma, and tractional retinal detachment were not able to participate in the study. Those who received anti-vascular endothelial growth factor (VEGF) therapy or intravitreal steroids were also excluded.

All angiograms were obtained by performing a standard FA procedure using a digital retinal camera (Carl Zeiss, Meditec, Inc., Dublin, CA) and an intravenous infusion of 5–10 mL of 10% sodium fluorescein. For each angiogram analyzed, there were accompanying fundus color photographs as well as the data on VA, intraocular pressure, and biomicroscopic status of the ocular media.

For all analyzed angiograms, there was an accompanying optical coherence tomography (OCT) image (Stratus Optical Coherence Tomography – OCT3, Carl Zeiss Meditec, Inc., Dublin, CA) with data of mean foveal thickness. For all participants, the best-corrected VA was measured using the Snellen chart.

Initially, the central parts of the angiogram of 3×3 mm were excised and then magnified five times. The angiograms processed in this way corresponded to the area of five macular fields according to the Early Treatment Diabetic Retinopathy Study (ETDRS) grid cells scheme: a central foveal ring with 1 mm diameter and an inner macular ring (pericentral) with 3 mm diameter divided into four subfields (nasal, temporal, superior, and inferior)¹². Fluorescein angiograms were then independently evaluated by the two experienced retinal specialists.

The classification of DR was performed according to the ETDRS grading system¹². According to these criteria, DR was classified into two basic stages: NPDR and proliferative DR (PDR). NPDR is further divided into mild, moderate, and severe.

The early-phase angiograms (up to 20 sec) were used to observe the superficial capillary plexus, while late-phase angiograms were used to assess leakage intensity, *ie*, blood-retina barrier (BRB) status.

In each of the 4 analyzed subfields (nasal, superior, temporal, and inferior), the irregularity of the perifoveal capillary ring was assessed as follows: Grade 0, normal (no disruption of the FAZ in that subfield); Grade 1, questionable (discrete ring irregularities in that subfield, but the changes are not clearly pathological); Grade 2, mild (outline of the FAZ is destroyed to 25% in that subfield); Grade 3, moderate (outline of the FAZ is destroyed 25% to 50% in that subfield); Grade 4, severe (capillary outline of the FAZ is completely destroyed in that subfield).

The cumulative FAZ outline irregularity was classified as follows: Grade 0, normal (no disruption of the FAZ); Grade 1, questionable (outline not smoothly round or oval, appreciable irregularities seen, but changes are not clearly pathological); Grade 2, mild (outline of the FAZ is destroyed for less than

half the original circumference $< 180^\circ$); Grade 3, moderate (outline of the FAZ is destroyed for greater than half the original circumference $> 180^\circ$); Grade 4, severe (capillary outline of the FAZ is completely destroyed).

Outline of the FAZ was considered normal when the Grade ranged from 0 to 1, suspiciously abnormal when the Grade was 2, and abnormal when the grade ranged from 3 to 4.

In each of the 4 analyzed subfields (nasal, superior, temporal, and inferior), the capillary loss was assessed as follows: Grade 0, absent (no loss); Grade 1, questionable; Grade 2, minimal (up to 25% loss in the subfield); Grade 3, moderate ($> 25\%$ and up to 50% loss in the subfield); Grade 4, severe ($> 50\%$ loss in the subfield).

The cumulative capillary loss for all four subfields was graded according to the scale: Grade 0, absent (no loss); Grade 1, questionable; Grade 2, minimal (loss up to 25% of the entire perifoveal capillary network); Grade 3, moderate ($> 25\%$ and up to 50% loss of the entire perifoveal capillary network); Grade 4, severe ($> 50\%$ loss of the entire perifoveal capillary network).

The capillary loss was considered normal when the Grade ranged from 0 to 1, suspiciously abnormal when the Grade was 2, and abnormal when the Grade ranged from 3 to 4.

Using the fluorescence of the perifoveal vessels as a comparison, the intensity of leakage was classified into 4 grades: Grade 0 corresponded to the absence of leakage; Grade 1 corresponded to the presence of low-intensity leakage (less fluorescent than vessels); Grade 2 corresponded to the presence of mid-intensity leakage (similar fluorescence to the vessels); Grade 3 corresponded to the presence of high-intensity leakage (more fluorescent than the vessels); Grade 4, intensive early diffuse dye leakage that completely blocks the observation of individual blood vessels.

Finally, according to the analyzed parameters in all four subfields, a cumulative diabetic MI was calculated and classified as none (Grade 0), questionable (Grade 1), mild (Grade 2), moderate (Grade 3), and severe (Grade 4). Grades 0 and 1 were considered normal, the Grade 2 was suspected to be pathological, and Grades 3 and 4 were considered pathological.

As a pathological status of increased macular thickness, the OCT 3 definition was used: $\geq 305 \mu\text{m}$ for males and $\geq 290 \mu\text{m}$ for females¹⁰. We compared a cumulative diabetic MI with the best corrected VA depending on the macular thickness.

In analyzing statistical data, SPSS version 22 (IBM Corp., Armonk, NY, USA) was used. Examination of the incidence of the FAZ outline irregularity, capillary loss, and dye leakage was done using the χ^2 test and ANOVA. A value of $p < 0.05$ was considered statistically significant.

Results

The mean age of the participants was 64.27 ± 7.3 years (range 48–72 years). The male to female ratio was almost equal (male 75, female 68). No statistically significant difference was noticed, $p = 0.069$. The mean duration of DM was 15.12 ± 6.8 years. DM type I was presented in 37 pa-

tients, while the other 86 patients had DM type 2. As shown in Table 1, 120 eyes had NPDR (42 eyes mild, 41 eyes moderate, and 37 eyes severe NPDR), while 23 eyes had PDR. Until the moment of FA, 67 eyes had previous focal laser photocoagulation, while in 38 eyes (23 eyes with PDR and 15 eyes with NPDR), the panretinal laser photocoagulation was done. Until the moment of FA, none of the eyes had received intravitreal anti-VEGF therapy. Table 1 shows the distribution of three parameters according to the gradation,

as well as the 4 subfields of the perifovea.

The cumulative DMI compared with the best corrected VA, depending on the macular thickness, is shown in Table 2. In the eyes with mild and moderate NPDR, none of the eyes had cumulative DMI Grades 3 and 4. In the eyes with severe NPDR, moderate and severe (Grades 3 and 4) MI was measured in 6 (16.2%) eyes, while in the eyes with PDR, moderate and severe MI was presented in 12 (52.2%) eyes.

Table 1

The distribution and gradation of the foveal avascular zone (FAZ) outline, capillary loss, and dye leakage between the groups

Diabetic retinopathy (DR)	FAZ outline subfield				Capillary loss subfield				Dye leakage subfield			
	N	S	T	I	N	S	T	I	N	S	T	I
NPDR												
mild (n = 42)												
0	38	40	41	40	38	39	40	39	36	37	38	37
1	3	1	1	1	3	2	2	2	6	5	4	5
2	1	1	0	1	1	1	0	1	0	0	0	0
3	0	0	0	0	0	0	0	0	0	0	0	0
4	0	0	0	0	0	0	0	0	0	0	0	0
moderate (n = 41)												
0	29	32	34	33	31	33	36	35	29	33	35	34
1	7	6	6	5	5	5	4	4	10	8	6	7
2	2	2	1	3	3	3	1	2	2	0	0	0
3	2	1	0	0	2	0	0	0	0	0	0	0
4	1	0	0	0	0	0	0	0	0	0	0	0
severe (n = 37)												
0	18	22	26	22	20	24	26	25	21	24	27	23
1	6	8	5	7	6	8	9	7	9	9	8	10
2	7	4	3	4	9	4	2	4	5	3	2	3
3	3	2	2	2	2	1	0	1	2	1	0	1
4	3	1	1	2	0	0	0	0	0	0	0	0
PDR (n = 23)												
0	2	5	7	4	4	3	4	7	1	2	12	3
1	2	4	5	4	5	6	4	5	7	10	5	10
2	7	6	3	8	9	9	13	8	12	9	6	9
3	7	5	4	4	3	2	2	2	3	2	0	1
4	5	3	4	3	2	1	0	1	1	0	0	0

NPDR – nonproliferative DR; PDR – proliferative DR; N – nasal; S – superior; T – temporal; I – inferior.

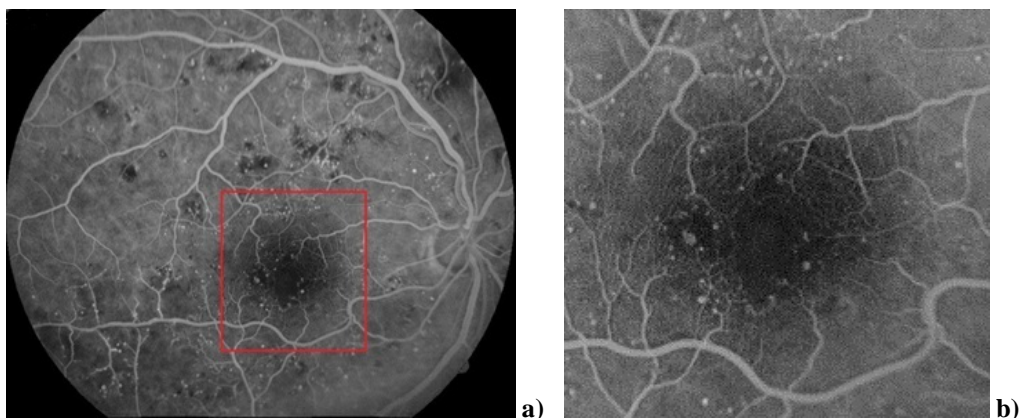


Fig. 1 – a) Enlarged foveal avascular zone (FAZ) with the FAZ outline destruction $\leq 180^\circ$; b) the same figure magnified $\times 5$.

Table 2
The distribution of cumulative diabetic macular ischemia (DMI) and mean macular thickness (MT), and the best-corrected visual acuity (BCVA) between the groups

Diabetic retinopathy (DR)	Cumulative DMI	Mean MT (μm) and mean corresponding BCVA		<i>p</i>
		< 305 (290) / BCVA	> 305 (290) / BCVA	
NPDR				
mild (n = 42)				
0	42	39 / 0.90	3 / 0.85	0.072
1	0	-	-	
2	0	-	-	
3	0	-	-	
4	0	-	-	
moderate (n = 41)				
0	35	29 / 0.90	6 / 0.70	0.051
1	5	4 / 0.85	1 / 0.80	0.088
2	1	1 / 0.90	0 / -	
3	0	-	- / -	
4	0	-	- / -	
severe (n = 37)				
0	14	12 / 0.70	2 / 0.35	0.023*
1	9	7 / 0.75	2 / 0.35	0.021*
2	8	6 / 0.65	2 / 0.35	0.018*
3	3	2 / 0.33	1 / 0.20	0.040*
4	3	2 / 0.25	1 / 0.10	0.038*
PDR (n = 23)				
0	0	- / -	- / -	
1	3	3 / 0.65	0 / -	
2	8	7 / 0.70	1 / 0.20	0.023*
3	7	6 / 0.35	1 / 0.10	0.017*
4	5	4 / 0.20	1 / 0.05	0.042*

NPDR – nonproliferative DR; PDR – proliferative DR.

* – statistically significant.

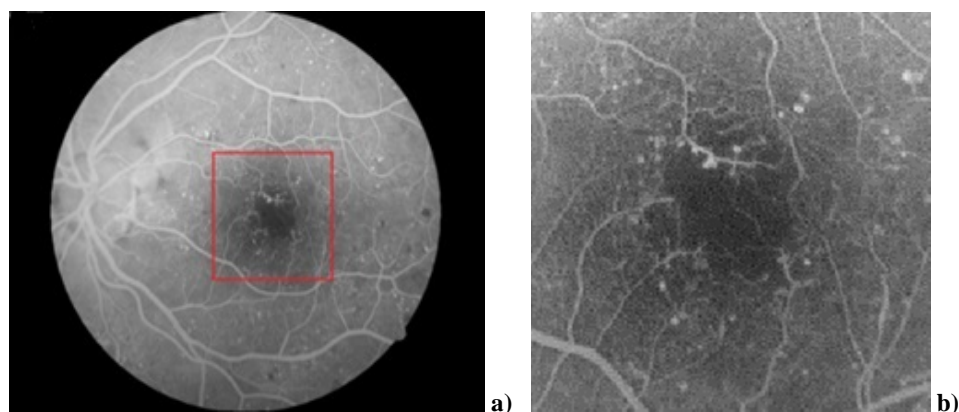


Fig. 2 – a) The cumulative foveal avascular zone (FAZ) outline destruction $\geq 180^\circ$ with capillary loss $\leq 50\%$; b) the same figure magnified $\times 5$.

According to the grade of ischemia, analyzing the eyes with mild and severe NPDR, a statistically significant difference was noticed ($p = 0.018$). Comparing severe with moderate NPDR, statistically significant difference was measured as well ($p = 0.037$). In the eyes with PDR, the highest statistically significant difference was found comparing them with the mild ($p = 0.002$), then with the moderate ($p = 0.022$), and finally with the severe NPDR ($p = 0.041$).

Figures 1a and 1b show the FAZ outline destruction $\leq 180^\circ$ of the original circumference. Figures 2a and 2b show the FAZ outline destruction $\geq 180^\circ$ of the original circumference with capillary loss $\leq 50\%$.

In subgroups with mild and moderate NPDR, without significant macular thickening, no statistically significant decrease in VA caused by MI was noticed ($p = 0.81$). Opposite, in the subgroup with severe NPDR and without significant

macular thickening, a statistically significant difference was presented among eyes with moderate and severe MI (Grades 3 and 4) compared to the eyes with lower Grades of MI ($p = 0.021$). A similar finding was found in the eyes with PDR ($p = 0.018$).

In the eyes with a statistically significant decrease of VA, most of the examined eyes (98%) had the FAZ outline destruction in the nasal subfield, while the superior and inferior subfields were destroyed in 71%, and the temporal subfield in 68% of the examined eyes.

As shown in Figures 3a and 3b, the FAZ outline destruction in the nasal subfield leads to a significant reduction in VA.

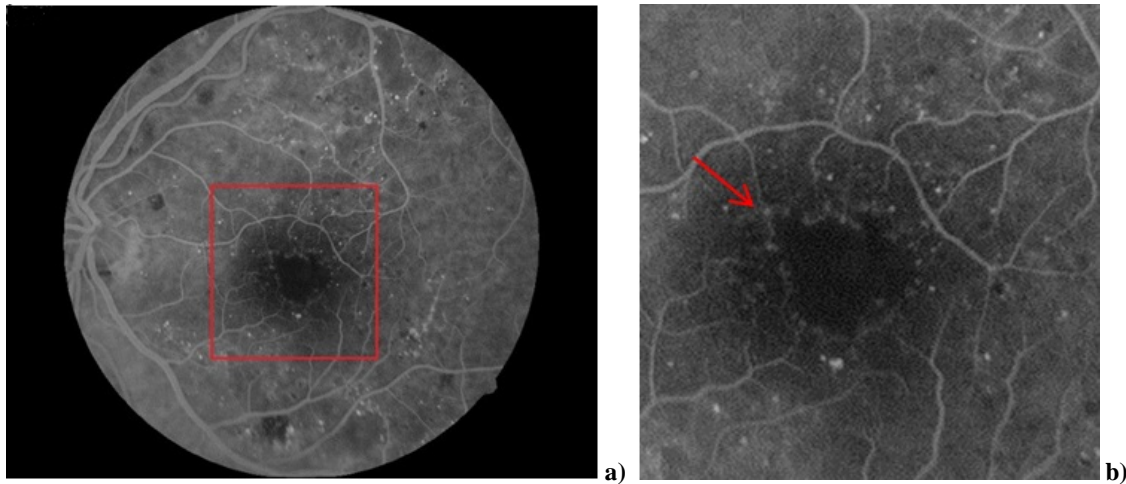


Fig. 3 – a) Foveal avascular zone (FAZ) outline destruction in nasal subfield; b) the same figure magnified $\times 5$.

In the eyes with the mild NPDR and without MI, the increased macular thickness caused a statistically insignificant decrease in VA compared to the eyes with a normal macular thickness ($p = 0.072$). A similar relationship was found in the eyes with the moderate NPDR ($p = 0.051$). In the eyes with the moderate NPDR and mild MI, the increase in macular thickness resulted in a statistically insignificant decrease in VA compared to the eyes with the normal macular thickness ($p = 0.088$). However, in the eyes with severe NPDR, every pathological increase in macular thickness caused a statistically significant decrease in VA, regardless of the degree of MI ($p = 0.023$, $p = 0.021$, $p = 0.018$, $p = 0.040$, $p = 0.038$). The similar relationship was found in the eyes with PDR ($p = 0.023$, $p = 0.017$, $p = 0.042$).

Discussion

The macula is a unique structural and functional region of the retina, and its nutrition must be well balanced. The outer retinal layers are completely avascular and are dependent on the metabolic support by the diffusion from the choroidal vascular beds. The inner retina is predominantly supplied by the retinal circulation^{21–23}. The parafoveal region of the macula is supplied by the dense vasculature with approximately 9 pairs of arterioles and venules⁶. The histologic findings have identified three different retinal capillary plex-

uses in the macula area: the superficial, the deep, and the intermediate capillary plexuses. The vessels in the nerve fiber layer and the ganglion cell layer form SCP, while the inner and outer plexiform layers receive blood from DCP located in the junction between them. At the level of the SCP, the mean vascular density is $0.28 \pm 0.1 \text{ mm}^2$, while at the level of the DCP, the mean vascular density is $0.37 \pm 0.12 \text{ mm}^2$ ^{4,5}.

The very center of the macula, the foveola, is completely avascular and corresponds approximately to the FAZ. The size of the FAZ has been intensively studied both in the healthy eyes as well in many retinal disorders. Many studies have shown that in healthy eyes, there are large individual variations in the size of the FAZ, ranging from 0.05 up to

1.98 mm^2 ^{7–9, 16, 17, 24–28}. A correlation between the FAZ size and VA in the normal human eyes has not yet been precisely determined. In healthy eyes, the size of the FAZ does not seem to influence visual function^{9,29}. Nevertheless, the relationship between the FAZ size and VA in retinal vascular diseases remains a matter of discussion.

DME represents the most common cause of vision loss in patients affected by DM. The degree of macular thickening is significantly correlated with VA^{30–33}. The common pathway that results in DME is disruption of the inner blood-retinal barrier^{34,35}.

Macular edema is frequently associated with relative ischemia. Diabetic MI is characterized by the occlusion and loss of the macular capillary network. The capillary dropout may result in larger areas of nonperfusion with a widening of intercapillary spaces in the perifoveal area¹⁰. Diabetic MI is an important clinical feature of DR. Clinically, DMI is defined by an enlargement of the FAZ and paramacular areas of capillary nonperfusion. The FAZ seems to get larger as the stage of retinopathy advances^{12,13}.

DMI can occur with or without macular edema, although it is very rare to find an isolated case of DMI. Thus, each macular edema is the result of two interrelated pathophysiological mechanisms that occur simultaneously: capillary occlusions and disruption of the BRB. Even in the absence of macular edema in diabetic eyes, abnormalities of the

FAZ are often seen, and they include irregular margins and widening of the intercapillary spaces^{11, 36}. FA typically shows the large areas of retinal hypofluorescence due to the absence of macular capillaries. In the case of MI, early-phase FA usually can demonstrate enlargement of the FAZ, irregularity of the FAZ outline, a broken foveal capillary ring, and widening of perifoveal capillary spaces^{12, 20}. In addition, based on the extent of dye leakage, the FA provides information on the condition of the inner BRB. However, fluorescein leakage does not always correlate with retinal thickness; a simple diffusion of fluorescein without retinal thickening is not included as a part of the definition of macular edema^{31, 36, 37}.

Optic coherence tomography is another useful clinical tool that can be used for detecting DMI. The ischemic areas of the macula appear thin during OCT investigation. However, the presence of edema usually makes the results of OCT difficult to interpret³⁸⁻⁴⁰.

Many studies have observed the increase of the FAZ area in the eyes with DR^{7, 14, 15}. Some studies have reported that the relationship between the FAZ size and DMI severity occurs from the earliest stages of DR^{7, 16}, while others have observed this relationship only in more advanced diseases^{15, 17}. This discrepancy is most likely due to the large inter-subject variability of the FAZ.

In our study, we have shown that some degree of MI may exist in the earliest stages of DR (mild and moderate NPDR), but the MI progressively intensifies during the advanced stages of the disease. There is a statistically significant difference in the degree of MI between the severe NPDR in relation to the mild NPDR ($p = 0.0016$) and the moderate NPDR ($p = 0.0022$). This difference is even more pronounced between PDR and the mild NPDR ($p = 0.0011$) and the moderate NPDR ($p = 0.0014$). Furthermore, the degree of MI is statistically slightly higher in PDR compared to the severe NPDR ($p = 0.041$). This finding is consistent with previous studies that have shown that in DR, the FAZ has been enlarged and seems to get larger as the stage of retinopathy advances⁴¹. It is estimated that the rate of the FAZ enlargement was between 5% and 10% of the baseline FAZ area per year in the eyes with DMI¹⁸.

In this paper, the FAZ outline irregularity has been demonstrated to be a good indicator of MI. The parameters related to the shape of the FAZ may be better parameters for monitoring the FAZ rather than its size. This is in agreement with the results of previous studies that have shown that the circularity and axial ratio are changed significantly more than the size of the FAZ in the eyes with DR⁴².

The effects of DMI on visual function are poorly defined. Some patients may have an almost normal level of VA in the presence of profound ischemia. Despite this, numerous studies have demonstrated the link between the presence of DMI and the loss of visual function^{13, 19, 43}. Some patients can experience sudden and severe decreases in VA. In these cases, DMI is often responsible for unexplained visual loss, even if the clinical stage of the disease is early or mild⁴⁴.

Previous studies have mainly focused on the relationship between the increase in the FAZ size in DR and its ef-

fect on VA. It is generally accepted that the doubling of the FAZ size indicates ischemic maculopathy. The enlargement of the FAZ greater than 1,000 μm generally indicates visual loss^{19, 45-47}. In their study, Arend et al.⁴³ showed that in diabetics with decreased VA (0.5 or worse), the FAZ was enlarged by 73% compared with patients whose VA was normal or near to normal (median VA 0.8)⁴³.

Due to the large variability in the FAZ size and topology in both normal and diseased eyes, we were mainly focused on determining the FAZ outline irregularities and their effect on VA. In our work, in the eyes with the mild and moderate NPDR, without significant macular thickening, MI does not affect visual function ($p = 0.068$, $p = 0.059$). Our study demonstrated that visual function was affected only in those people with moderate to severe MI.

In the eyes with severe NPDR and no significant macular thickening, there was a statistically significant difference in VA ($p = 0.033$) between eyes with the FAZ outline destruction greater than half the original circumference $> 180^\circ$ (Grades 3 and 4) compared to eyes where these alterations are milder (grades 1 and 2). A similar finding was found in the eyes with PDR ($p = 0.025$).

In the eyes with severe NPDR and PDR, in the absence of significant macular thickening, only the destruction of the FAZ outline for greater than half of the original circumference $> 180^\circ$ (Grades 3 and 4) resulted in a significant decrease in VA. Our results confirm, therefore, a definite link between MI and VA.

Our findings indicate that the location of MI changes plays a critical role in its effects on visual function. In our work, the ischemia of the nasal parts of the parafoveal capillary plexus had a particularly strong impact on VA. In almost all eyes with capillary nonperfusion in this part of the FAZ outline, there was a decrease in VA. The capillary network in the nasal parafoveal parts supplies the papillomacular nerve fibers originating from the fovea. We supposed that ischemia in these locations, which contain a high density of axons originating from the macula, may have an association with a reduction in VA. This finding is consistent with the results of other studies that observed a strong significant association between papillomacular ischemia and VA, independent of the FAZ size^{44, 48}.

The relationship of edema to changes in visual function is complex. In the eyes with the mild NPDR and without MI, the increased macular thickness caused a statistically insignificant decrease in VA compared to the eyes with a normal macular thickness ($p = 0.072$). A similar relationship was also found in the eyes with the moderate NPDR ($p = 0.051$). In the eyes with the moderate NPDR and the mild MI, the increase in macular thickness resulted in a statistically insignificant decrease in VA compared to the eyes with the normal macular thickness ($p = 0.088$). As shown in Table 2, in the eyes with severe NPDR, any pathological increase in macular thickness caused a statistically significant decrease in VA, regardless of the degree of MI. A similar relationship was also found in the eyes with PDR.

Our results suggest that ischemic maculopathy may be compatible with good VA if not accompanied by edema. The

occurrence of macular edema caused by leakage from residual macular capillaries leads to a greater decrease in VA, which is in agreement with the findings of other studies^{14, 19}. As mentioned earlier, the fluorescein leakage does not always correlate with retinal thickness. However, in our study, there was a significant agreement on the degree of dye leakage and increased macular thickness in approximately 75% of the eyes.

DMI causes severe irreversible vision loss, and the severity of the disease increases with time^{16, 17}. DMI is associated with a poor prognosis of DR. Some studies have linked DMI as a risk factor for progression of DR severity⁴⁹. The one-year risk of developing progressive DR was found to be almost 42% in patients with DMI. The risk for disease progression was significantly lower (by 18%) in diabetics without DMI⁵⁰.

Until now, no defined successful treatment method for DMI has been found. The only possible treatment seems to be the management of the risk factors. These include the control of blood sugar levels and optimum blood pressure control. In addition, other risk factors like anemia and nephropathy should also be controlled⁵¹.

Today, the intravitreal application of anti-VEGF drugs is a generally accepted method of treating macular edema, and those drugs can significantly reduce retinal edema.

However, several studies have suggested that anti-VEGF therapy could have potential ischemic effects and further compromise the retinal circulation^{52–54}. In this regard, a good assessment of the degree of MI is necessary before using these drugs to treat macular edema.

Conclusion

DMI is an important clinical feature of DR, and some degree of MI may exist in the earliest stages of the disease. Results of our study suggest that the assessment of the FAZ outline irregularity may be a good indicator of MI. Ischemic maculopathy may be compatible with good VA if not accompanied by edema. In the absence of significant macular thickening, the destruction of one-half of the perifoveal capillary network or larger is associated with reduced VA. The occurrence of macular edema caused by leakage from residual macular capillaries leads to a greater decrease in VA. The location of MI changes in the nasal parts of the perifoveal capillary ring has a particularly strong impact on VA. Before using anti-VEGF drugs in the treatment of macular edema, a good assessment of the degree of MI is required due to their potentially detrimental effect on the deterioration of macular perfusion.

R E F E R E N C E S

1. Klein R, Klein BEK, Moss SE, Crickshanks K. The Wisconsin Epidemiologic Study of Diabetic Retinopathy, XV: the long-term incidence of macular edema. *Ophthalmology* 1995; 102(1): 7–16.
2. Photocoagulation for diabetic macular edema. Early Treatment Diabetic Retinopathy Study report number 1. Early Treatment Diabetic Retinopathy Study research group. *Arch Ophthalmol* 1985; 103(12): 1796–806.
3. Yu DY, Cringle SJ. Oxygen distribution and consumption within the retina in vascularised and avascular retinas and in animal models of retinal disease. *Prog Retin Eye Res* 2001; 20(2): 175–208.
4. Coscas F, Sellam A, Glacet-Bernard A, Jung C, Goudot M, Miere A, et al. Normative Data for Vascular Density in Superficial and Deep Capillary Plexuses of Healthy Adults Assessed by Optical Coherence Tomography Angiography. *Invest Ophthalmol Vis Sci* 2016; 57(9): OCT211–23.
5. Tan PE, Yu PK, Balaratnasingam C, Cringle S, Morgan WH, McAllister IL, et al. Quantitative confocal imaging of the retinal microvasculature in the human retina. *Invest Ophthalmol Vis Sci* 2012; 53(9): 5728–36.
6. Yu PK, Balaratnasingam C, Cringle SJ, McAllister IL, Provis J, Yu DY. Microstructure and network organization of the microvasculature in the human macula. *Invest Ophthalmol Vis Sci* 2010; 51(12): 6735–43.
7. Conrath J, Giorgi R, Raccab D, Ridings B. Foveal avascular zone in diabetic retinopathy: quantitative vs qualitative assessment. *Eye (Lond)* 2005; 19(3): 322–6.
8. Dubis AM, Hansen BR, Cooper RF, Beringer J, Dubra A, Carroll J. The relationship between the foveal avascular zone and foveal pit morphology. *Invest Ophthalmol Vis Sci* 2012; 53(3): 1628–36.
9. Samara WA, Say EA, Khoo CT, Higgins T, Magrath G, Ferenczy S, et al. Correlation of foveal avascular zone size with foveal morphology in normal eyes using optical coherence tomography angiography. *Retina* 2015; 35(11): 2188–95.
10. Bressler NM, Edwards AR, Antoszyk AN, Beck R, Browning D, Ciardella A, et al. Retinal thickness on Stratus optical coherence tomography in people with diabetes and minimal or no diabetic retinopathy. *Am J Ophthalmol* 2008; 145(5): 894–901.
11. Byeon SH, Chu YK, Lee H, Lee SY, Kwon OW. Foveal ganglion cell layer damage in ischemic diabetic maculopathy: correlation of optical coherence tomography and anatomic changes. *Ophthalmology* 2009; 116(10): 1949–59. e8.
12. Classification of diabetic retinopathy from fluorescein angiograms. ETDRS report number 11. Early Treatment Diabetic Retinopathy Study Research Group. *Ophthalmology* 1991; 98(5 Suppl): 807–22.
13. Unoki N, Nishijima K, Sakamoto A, Kita M, Watanabe D, Hangai M, et al. Retinal sensitivity loss and structural disturbance in areas of capillary nonperfusion of eyes with diabetic retinopathy. *Am J Ophthalmol* 2007; 144(5): 755–60.
14. Bresnick GH, Condit R, Syrjala S, Groo A, Korth K. Abnormalities of the foveal avascular zone in diabetic retinopathy. *Arch Ophthalmol* 1984; 102(9): 1286–93.
15. Hilmantel G, Applegate RA, van Heuven WA, Stowers S, Bradley A, Lee B. Entoptic foveal avascular zone measurement and diabetic retinopathy. *Optom Vis Sci* 1999; 76(12): 826–31.
16. Mansour AM, Schachat A, Bodiford G, Haymond R. Foveal avascular zone in diabetes mellitus. *Retina* 1993; 13(2): 125–8.
17. Sander B, Larsen M, Engler C, Lund-Andersen H, Parving HH. Early changes in diabetic retinopathy: capillary loss and blood-retina barrier permeability in relation to metabolic control. *Acta Ophthalmol* 1994; 72(5): 553–9.
18. Sim DA, Keane PA, Zarranz-Ventura J, Bunce C, Fruttiger M, Patel P, et al. Predictive factors for the progression of diabetic macular ischemia. *Am J Ophthalmol* 2013; 156(4): 684–92.
19. Bresnick GH, De Venecia G, Myers FL, Harris JA, Davis MD. Retinal ischemia in diabetic retinopathy. *Arch Ophthalmol* 1975; 93(12): 1300–10.
20. Salz DA, Witkin AJ. Imaging in diabetic retinopathy. *Middle East Afr J Ophthalmol* 2015; 22(2): 145–50.

21. Provis JM, Penfold PL, Cornish EE, Sanderoe TM, Madigan MC. Anatomy and development of the macula: specialization and the vulnerability to macular degeneration. *Clin Exp Optom* 2005; 88(5): 269–81.
22. Kawamura S, Taohibanaki S. Rod and cone photoreceptors: molecular basis of the difference in their physiology. *Comp Biochem Physiol a Mol Integr Physiol* 2008; 150(4): 369–77.
23. Snodderly DM, Weinhaus RS. Retinal vasculature of the fovea of the squirrel monkey, *Saimiri sciureus*: three-dimensional architecture, visual screening, and relationships to the neuronal layers. *J Comp Neurol* 1990; 297(1): 145–63.
24. Iafe NA, Phasukkijwatanana N, Chen X, Sarraf D. Retinal Capillary Density and Foveal Avascular Zone Area Are Age-Dependent: Quantitative Analysis Using Optical Coherence Tomography Angiography Quantitative Analysis Using OCT Angiography. *Invest Ophthalmol Vis Sci* 2016; 57(13): 5780–7.
25. Yu J, Jiang C, Wang X, Zhu L, Gu R, Xu H, et al. Macular perfusion in healthy Chinese: an optical coherence tomography angiogram study. *Invest Ophthalmol Vis Sci* 2015; 56(5): 3212–7.
26. Tan CS, Lim LW, Chow VS, Chay IW, Tan S, Cheong KX, et al. Optical Coherence Tomography Angiography Evaluation of the Parafoveal Vasculature and Its Relationship with Ocular Factors. *Invest Ophthalmol Vis Sci* 2016; 57(9): OCT224–34.
27. Takase N, Nozaki M, Kato A, Ozeki H, Yoshida M, Ogura Y. Enlargement of Foveal Avascular Zone In Diabetic Eyes Evaluated By En Face Optical Coherence Tomography Angiography. *Retina* 2015; 358(11): 2377–83.
28. Laatikainen L, Larinkari J. Capillary-free area of the fovea with advancing age. *Invest Ophthalmol Vis Sci* 1977; 16(12): 1154–7.
29. Mammo Z, Balaratnasingam C, Yu P, Xu J, Heisler M, Mackenzie P, et al. Quantitative noninvasive angiography of the fovea centralis using speckle variance optical coherence tomography. *Invest Ophthalmol Vis Sci* 2015; 56(9): 5074–86.
30. Nussenblatt RB, Kaufman SC, Palestine AG, Davis MD, Ferris FL 3rd. Macular thickening and visual acuity. Measurement in patients with cystoid macular edema. *Ophthalmology* 1987; 94(9): 1134–9.
31. Chan A, Duker JS, Ko TH, Fujimoto JG, Schuman JS. Normal macular thickness measurements in healthy eyes using Stratus optical coherence tomography. *Arch Ophthalmol* 2006; 124(2): 193–8.
32. Sebaudig UH, Glaefke C, Scholz F, Richard G. Optical coherence tomography for retinal thickness measurement in diabetic patients without clinically significant macular edema. *Ophthalmic Surg Lasers* 2000; 31(3): 182–6.
33. Sanchez-Tocino H, Alvarez-Vidal A, Maldonado MJ, Moreno-Montañés J, García-Layana A. Retinal thickness study with optical coherence tomography in patients with diabetes. *Invest Ophthalmol Vis Sci* 2002; 43(5): 1588–94.
34. Tarr JM, Kaul K, Chopra M, Kohner EM, Chibber R. Pathophysiology of diabetic retinopathy. *ISRN Ophthalmol* 2013; 2013: 343560.
35. Browning DJ, Altaweel MM, Bressler NM, Bressler S, Scott I. Diabetic macular edema: what is focal and what is diffuse? *Am J Ophthalmol* 2008; 146(5): 649–55.
36. Cunha-Vaz JG. Natural history of diabetic retinopathy. *Focus Diabetic Ret* 1995; 2: 48–55.
37. Lobo CL, Bernardes RC, Cunha-Vaz JG. Alterations of the blood-retinal barrier and retinal thickness in preclinical retinopathy in subjects with type 2 diabetes. *Arch Ophthalmol* 2000; 118(10): 1364–9.
38. Spaide RF. Retinal vascular layers imaged by fluorescein angiography and optical coherence tomography angiography. *JAMA Ophthalmol* 2015; 133(1): 45–50.
39. Cennamo G, Romano MR, Nicoletti G, Velotti N, de Crecchio G. Optical coherence tomography angiography versus fluorescein angiography in the diagnosis of ischaemic diabetic maculopathy. *Acta Ophthalmol* 2017; 95: e36–e42.
40. Sim DA, Keane PA, Fung S, Karampelas M, Sadda SR, Fruttiger M, et al. Quantitative analysis of diabetic macular ischemia using optical coherence tomography. *Invest Ophthalmol Vis Sci* 2014; 55(1): 417–23.
41. Scarinci F, Jampol LM, Linsenmeier RA, Fawzi AA. Association of Diabetic Macular Nonperfusion with Outer Retinal Disruption on Optical Coherence Tomography. *JAMA Ophthalmol* 2015; 133(9): 1036–44.
42. Krawitz BD, Mo S, Geyman LS, Agemy S, Scripsema N, Garcia P, et al. Acircularity index and axis ratio of the foveal avascular zone in diabetic eyes and healthy controls measured by optical coherence tomography angiography. *Vision Res* 2017; 39: 177–86.
43. Arend O, Wolf S, Harris A, Reim M. The relationship of macular microcirculation to visual acuity in diabetic patients. *Arch Ophthalmol* 1995; 113(5): 610–14.
44. Sim DA, Keane PA, Zarranz-Ventura J, Fung S, Powner M, Platteau E, et al. The Effects of Macular Ischemia on Visual Acuity in Diabetic Retinopathy. *Invest Ophthalmol Vis Sci* 2013; 54(3): 2353–60.
45. Bandello F, Parodi MB, Lanzetta P, Loewenstein A, Massin P, Menchini F, et al. Diabetic macular edema. In: Coscas G, editor. *Macular Edema: A Practical Approach*. Basel: Karger; 2010. p. 73–110.
46. Yu DY, Cringle SJ, Yu PK, Su EN. Intraretinal oxygen distribution and consumption during retinal artery occlusion and hyperoxic ventilation in the rat. *Invest Ophthalmol Vis Sci* 2007; 48(5): 2290–6.
47. Das A, McGuire PG, Rangasamy S. Diabetic Macular Edema: Pathophysiology and Novel Therapeutic Targets. *Ophthalmology* 2015; 122(7): 1375–94.
48. Ishibazawa A, Nagaoka T, Takahashi A, Omae T, Tami T, Sogawa K, et al. Optical coherence tomography angiography in diabetic retinopathy: a prospective pilot study. *Am J Ophthalmol* 2015; 160(1): 35–44.
49. Pautler SE. Diabetic macular ischemia. In: *Browning DJ*, editor. *Diabetic Retinopathy: Evidence-Based Management*. New York, NY: Springer; 2010. p. 203–25.
50. Fluorescein angiographic risk factors for progression of diabetic retinopathy. ETDRS report number 13. Early Treatment Diabetic Retinopathy Study Research Group. *Ophthalmology* 1991; 98(5 Suppl): 834–40.
51. Browning DJ, Stewart MW, Lee C. Diabetic macular edema: Evidence-based management. *Indian J Ophthalmol* 2018; 66(12): 1736–50.
52. Chen E, Hsu J, Park CH. Acute visual acuity loss following intravitreal bevacizumab for diabetic macular edema. *Ophthalmic Surg Lasers Imaging* 2009; 40(1): 68–70.
53. Pereira F, Godoy BR, Maia M, Regatieri CV. Microperimetry and OCT angiography evaluation of patients with ischemic diabetic macular edema treated with monthly intravitreal bevacizumab: a pilot study. *Int J Retin Vitre* 2019; 5: 24.
54. Manosaridis K, Talks J. Macular ischaemia: a contraindication for anti-VEGF treatment in retinal vascular disease? *Br J Ophthalmol* 2012; 96(2): 179–84.

Received on October 30, 2020

Revised on December 24, 2020

Accepted on December 31, 2020

Online First January 2021