



## Double-hit primary unilateral adrenal lymphoma with good outcome

*Double-hit* primarni limfom nadbubrežne žlezde sa povoljnim ishodom

Olivera Marković<sup>\*†</sup>, Dragomir Marisavljević<sup>\*†</sup>, Svetlana Jelić<sup>\*†</sup>, Biljana Mihaljević<sup>†‡</sup>, Tamara Martinović<sup>†</sup>, Vesna Čemerikić<sup>§</sup>

<sup>\*</sup>Clinical Hospital Center “Bežanijska kosa”, Belgrade, Serbia; <sup>†</sup>Faculty of Medicine, University of Belgrade, Belgrade, Serbia; <sup>‡</sup>Clinic of Hematology, Clinical Center of Serbia, Belgrade, Serbia; <sup>§</sup>Beolab, Belgrade, Serbia

### Abstract

**Introduction.** Primary adrenal non-Hodgkin's lymphoma (NHL) is a rare neoplasm with poor prognosis. On the other side, double-hit lymphomas with BCL2 and MYC translocation are characterized by advanced disease stage, extranodal and central nervous system involvements at presentation or disease progression. **Case report.** We reported a 73-year-old male patient with double-hit primary adrenal lymphoma and preserved adrenal function, showing a favorable clinical course. Computed tomography of abdomen showed a 9 × 7 cm mass of the left adrenal gland. Laparotomy with left adrenalectomy was done and histological examination revealed diagnosis of a diffuse large B-cell NHL (DLBCL), non-GCB subtype. The patient was treated with 6 cycles of R-CHOP chemotherapy with reduced doses of doxorubicin because of the decreased left ventricle ejection fraction. The patient was followed up regularly for 20 months with no evidence of tumor recurrence despite the inherently poor prognostic profile and double-hit phenotype of the disease. **Conclusion.** R-CHOP chemotherapy in combination with adrenalectomy can be an effective first-line regimen for primary adrenal DLBCL, despite the inherently poor prognostic profile (non-GCB subtype, bulky disease, elevated lactate dehydrogenase and double-hit phenotype of the disease).

### Key words:

lymphoma, non-hodkin; adrenal gland neoplasms; drug therapy; surgical procedures, operative; prognosis.

### Apstrakt

**Uvod.** Primarni adrenalni nehoćkinski limfom izuzetno je redak oblik limfoma i odlikuje se lošom prognozom. Sa druge strane, *double-hit* limfomi sa BCL2 i MYC translokacijom karakterišu se uznapredovalom bolešću u vreme postavljanja dijagnoze, često prisutnom ektranodalnom lokalizacijom bolesti i lošom prognozom. **Prikaz bolesnika.** Prikazali smo bolesnika starog 73 godine sa *double-hit* primarnim limfomom nadbubrege sa očuvanom adrenalnom funkcijom i povoljnim kliničkim tokom. Kompjuterizovanom tomografijom abdomena registrovana je tumorska promena leve adrenalne žlezde, veličine 9 × 7 cm, dok nije utvrđeno prisustvo bolesti na drugim lokalizacijama. Učinjeno je kompletno hirurško uklanjanje tumorske promene i na osnovu histološkog pregleda postavljena je dijagnoza difuznog B krupnoćelijskog limfoma, (DLBCL) non-GCB podtipa. Nakon hirurškog lečenja primenjen je R-CHOP protokol sa redukovanim dozama adriablastina zbog smanjene ejekcione frakcije leve komore. I pored veoma lošeg prognostičkog profila bolesti (non-GCB tip, *bulky* bolesti, visokih vrednosti laktat dehidrogenaze, visokog komorbiditetnog skora i *double-hit* fenotipa) bolesnik je već 20 meseci u kompletnoj remisiji. **Conclusion.** Imunohemioterapija (R-CHOP) u kombinaciji sa hirurškim lečenjem je efikasna prva linija terapije kod bolesnika sa primarnim adrenalnim difuznim B-krupnoćelijskim limfomom i pored nepovoljnog prognostičkog profila i *double-hit* fenotipa bolesti.

### Ključne reči:

limfom, nehodžkinov; nadbubrežne žlezde, neoplazme; lečenje lekovima; hirurgija, operativne procedure; prognoza.

## Introduction

The adrenal gland is a rare site of primary extranodal non-Hodgkin lymphoma (NHL), accounting for less than 1% of all NHL cases and only 3% of primary extranodal lymphomas<sup>1</sup>. Compared with nodal diffuse large B-cell NHL (DLBCL), primary adrenal DLBCL is frequently accompanied with many adverse features such as bulky disease, elevated lactate dehydrogenase (LDH), advanced clinical stage and adrenal insufficiency<sup>2</sup>. Prognosis is poor and most patients die due to the progressive disease or its complications within one year after the diagnosis<sup>3,4</sup>. Double-hit lymphomas with MYC and BCL-2 translocation are rare types of lymphoma (around 2% of NHL) with frequent extranodal disease and extremely poor prognosis<sup>5</sup>. We presented the patient with double-hit primary unilateral adrenal lymphoma, with preserved adrenal function and good outcome.

## Case report

A 73-year-old man, with complaints of abdominal pain, fatigue and weight loss for 4 months was admitted to the Hematology Department of the Clinical Hospital Center "Bežanijska kosa", Belgrade, Serbia. The patient had acute myocardial infarction in 2007 and underwent gastrectomy due to bleeding of gastric ulcer 12 years ago. His past medical history was also significant for alcohol abuse (20 years) and cigarette smoking (55 years). Hematological analysis showed mild anemia (hemoglobin level of 103 g/L). Blood biochemistry showed elevated LDH (920 U/L). Ultrasonography and computed tomography (CT) of abdomen demonstrated 9 × 7 cm mass of the left adrenal gland, without splenomegaly or abdominal lymphadenopathy (Figure 1). The patient was referred to the Endocrine Surgery Clinic where left adrenalectomy was done in May 2011.

Histological examination of adrenal tumor revealed diagnosis of DLBCL, non-germinal center B-cell (non-GCB) subtype with following immunophenotype: EMA-, LCA+, PAX5+, inhibin-, synaptophysin-, CD79+, CD20+, CD5-, CD3-, CD10-, CD43-, CD30-, CD38-, CD138-, Mum-1+, BCL2+, BCL6-, ALK-1-, Ki-67 (positive in 60% of lymphoma cells). Fluorescence *in situ* hybridization (FISH) showed MYC(8q24) and BCL2(18q21) rearrangement (Figure 2). In June 2011 the patient was referred back to the He-

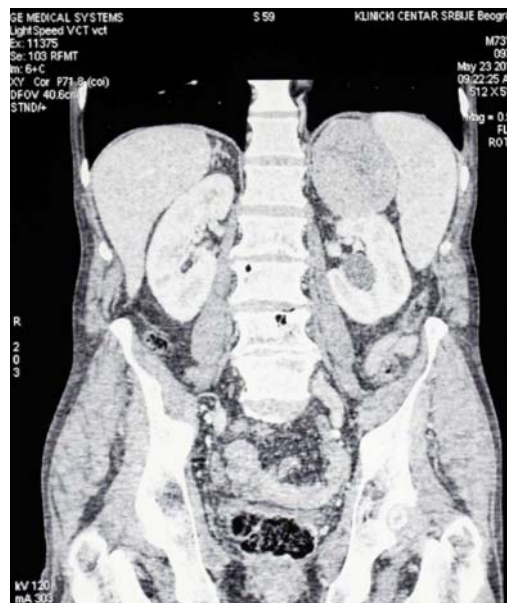


Fig. 1 – Computed tomography scan of abdomen demonstrated 9 × 7 cm mass of the left adrenal gland.

matology Department. The clinical examination showed pale skin without superficial lymphadenopathy or organomegaly. A serum biochemistry profile showed elevated LDH (506 IU/L) and  $\beta_2$  microglobulin of 4.3 mg/L. Serum sodium, potassium and calcium levels were normal. Endocrinology assessment proved that the patient was euthyroid and eucortisolemic. Mineralocorticoid function and the function of adrenal medulla were also intact. Thoracic CT scan did not show any lymph node enlargement. CT of brain revealed only a few old ischemic lesions. Cerebrospinal fluid sediment did not show any lymphoid cells. Bone marrow trephine biopsy showed no lymphoid infiltration. Echocardiography showed reduced ejection fraction (40%) and aneurysmatic dilatation of the inferior left ventricular wall. Therefore, the patient received immunochemotherapy regimen rituximab–cyclophosphamide/doxorubicin (hydroxydaunomycin)/vincristine (Oncovin®)/prednisolone (R-CHOP) with reduced doses of an anthracycline (doxorubicin 25 mg/m<sup>2</sup> i.v. every 3 weeks). After 6 cycles of R-CHOP chemotherapy the patient was in good condition with no evidence of tumor on fludeoxyglucose – positron emission tomography (FDG-PET) scans. The patient was followed regularly in our Outpatient Hematology Clinic. On the

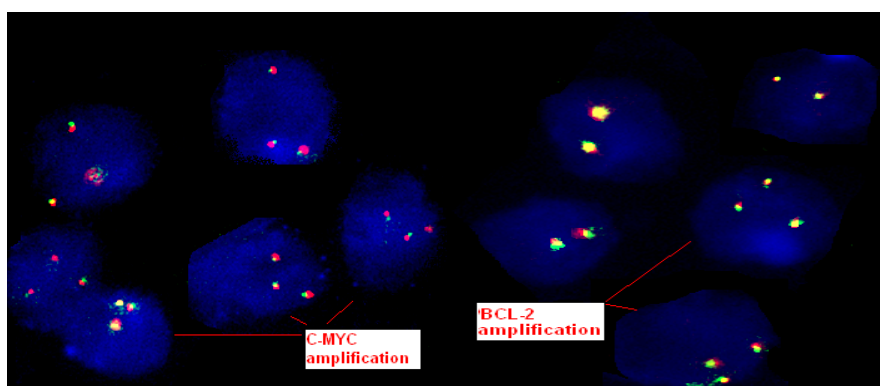


Fig. 2 – MYC (8q24) and BCL2 (18q21) rearrangement (fluorescence *in situ* hybridisation – FISH).

last follow-up (January, 2013), the patient was in good clinical condition, with no evidence of lymphoma recurrence.

## Discussion

Primary adrenal non-Hodgkin's lymphoma (PAL) is a rare neoplasm with approximately 120 cases reported worldwide<sup>2</sup>. The disease most frequently affects older men with the mean age of 68 years at diagnosis<sup>4</sup>. The symptoms of the disease and response to treatment vary depending on the type of lymphoma, tumor size, and the presence of adrenal failure. Literature data based mostly on case reports, revealed a high rate of bilateral involvement (60–79% of cases) and adrenal failure (67–69% of cases)<sup>4</sup>. Nodal and extranodal disease in PAL is rare at diagnosis<sup>6</sup>. However, involvement of unusual extranodal organs is often reported at the disease relapse<sup>6</sup>. The most frequent histological subtype of PAL is a diffuse large non-GCB subtype<sup>2,7</sup>. The presented patient had typical age, histology and symptoms for PAL, but he presented without bilateral involvement and consecutive adrenal failure.

The pathogenesis of PAL is not clear. Immune deregulation may predispose to PAL as well as to certain other lymphomas in some patients<sup>8</sup>. Proposed hypothesis for the occurrence of PAL includes preexisting autoimmune adrenalitis with lymphocyte infiltration, although not conclusively proven due to the rarity of both autoimmune adrenalitis and lymphomas<sup>9</sup>. It is supported by more frequent development of adrenal failure in patients with lymphoma than in patients with bilateral adrenal metastases. Namely, adrenal failure occurs in 1% of patients with adrenal metastasis and only when more than 90% of the adrenal tissue is destroyed<sup>10</sup>. In contrast, a very high frequency of primary adrenal failure (60–70%) has been reported in patients with

PAL, including patients with mildly enlarged adrenal glands<sup>9,10</sup>.

The majority of published cases of PAL had a poor prognosis, although there were some with good prognosis<sup>3,4,11</sup>. Poor prognosis is related to bilateral disease, high International Prognostic Index score, high LDH, the presence of other localization of disease, non-GCB type and advanced age<sup>2</sup>. Our patient had double-hit phenotype with concurrent expression of MYC and BCL2 which is particularly related to inferior prognosis of DLBCL cases, even in the era of rituximab<sup>5,12–14</sup>. Despite non-GCB subtype, double-hit phenotype, advanced age, comorbidities and high LDH our patient achieved complete remission and showed no evidence of lymphoma recurrence 20 months from the diagnosis.

Given the rarity of PAL, the optimal therapeutic modality is poorly defined. Available data on outcomes of patients treated by chemotherapy, unilateral or bilateral adrenalectomy, and/or adjuvant radiotherapy gave inconclusive results<sup>2,15–17</sup>. In earlier trials of CHOP or CHOP-like therapy, the results of PAL treatment have been disappointing; a review of the literature data has shown that most patients died due to the disease or its complications within one year after diagnosis<sup>4,7,17</sup>. In contrast, Kim et al.<sup>2</sup> have recently reported that treatment outcomes with R-CHOP for primary adrenal DLBCL were not inferior to those of nodal DLBCL.

## Conclusion

This first published case of double-hit primary adrenal lymphoma in Serbia suggests that R-CHOP chemotherapy in combination with adrenalectomy can be an effective first-line regimen for primary adrenal diffuse large B-cell lymphoma, despite the inherently poor prognostic profile and double-hit phenotype of the disease.

## REFERENCES

1. Kumar R, Xiu Y, Mavi A, El-Haddad G, Zhuang H, Alawi A. FDG-PET imaging in primary bilateral adrenal lymphoma: a case report and review of the literature. *Clin Nucl Med* 2005; 30(4): 222–30.
2. Kim YR, Kim JS, Min YH, Hyunyon D, Shin H, Mun Y, et al. Prognostic factors in primary diffuse large B-cell lymphoma of adrenal gland treated with rituximab-CHOP chemotherapy from the Consortium for Improving Survival of Lymphoma (CISL). *J Hematol Oncol* 2012; 5(1): 49–51.
3. Yang Y, Li Q, Pan Y. Bilateral primary adrenal lymphoma. *Br J Hematol* 2010; 150(3): 250–4.
4. Singh D, Kumar L, Sharma A, Vijayaraghavan M, Thulkar S, Tandon N. Adrenal Involvement in Non-Hodgkin's Lymphoma: Four Cases and Review of Literature. *Leuk Lymphoma* 2004; 45(4): 789–94.
5. Tomita N, Tokunaka M, Nakamura N, Takeuchi K, Koike J, Motomura S, et al. Clinicopathological features of lymphoma/leukemia patients carrying both BCL2 and MYC translocations. *Haematologica* 2009; 94(7): 935–43.
6. Grigg AP, Connors JM. Primary adrenal lymphoma. *Clin Lymphoma* 2003; 4(3): 154–60.
7. Mozas A, Ye H, Chuang W, Chu J, Huang W, Chen H, et al. Most primary adrenal lymphomas are diffuse large B-cell lymphomas with non-germinal center B-cell phenotype, BCL6 gene rearrangement and poor prognosis. *Mod Pathol* 2009; 22(9): 1210–7.
8. Goldin LR, Landgren O. Autoimmunity and lymphomagenesis. *Int J Cancer* 2009; 124(7): 1497–502.
9. Lam KY, Lo CY. Metastatic tumours of the adrenal glands: a 30-year experience in a teaching hospital. *Clin Endocrinol* 2002; 56(1): 95–101.
10. Reddy SV, Prabhudesai S, Gnanasekaran B. Origin of primary adrenal lymphoma and predisposing factors for primary adrenal insufficiency in primary adrenal lymphoma. *Indian J Endocrinol Metab* 2011; 15(4): 350–1.
11. Spyrgiorgou A, Schneider HJ, Mussack T, Reincke M, von Werder K, Beuschlein F. Primary adrenal lymphoma: 3 case reports with different outcomes. *Exp Clin Endocrinol Diabetes* 2011; 119(4): 208–13.
12. Lim KH, Chiou TY, Lin CJ, Hsieh RK. Rituximab in the treatment of primary bilateral adrenal lymphoma with adrenal crisis. *Med Oncol* 2008; 25(1): 107–9.
13. Savage KJ, Johnson NA, Ben-Neriah S, Connors JM, Sehn LH, Farinha P, et al. MYC gene rearrangements are associated with a poor prognosis in diffuse large B-cell lymphoma patients treated with R-CHOP chemotherapy. *Blood* 2009; 114(17): 3533–7.

14. *Johnson NA, Slack GW, Savage KJ, Connors JM, Ben-Neriah S, Rogic S*, et al. Concurrent expression of MYC and BCL2 in diffuse large B-cell lymphoma treated with rituximab plus cyclophosphamide, doxorubicin, vincristine, and prednisone. *J Clin Oncol* 2012; 30(28): 3452–9.
15. *Smith A, Eyvazoglu D, Kavic SM*. Laparoscopic adrenalectomy for unsuspected unilateral primary adrenal lymphoma. *JSLs* 2011; 15(3): 427–9.
16. *Shirao S, Kuroda H, Kida M, Watanabe H, Matsunaga T, Niitsu Y*, et al. Effective combined modality therapy for a patient with primary adrenal lymphoma. *Rinsho Ketsueki* 2006; 47(3): 204–9. (Japanese)
17. *Horiguchi K, Hashimoto K, Hashizume M, Masuo T, Suto M, Okajo J*, et al. Primary bilateral adrenal diffuse large B-cell lymphoma demonstrating adrenal failure. *Intern Med* 2010; 49(20): 2241–6.

Received on February 21, 2013.

Accepted on March 22, 2013.