



Disseminated *Rhodococcus equi* infection in a patient with Hodgkin lymphoma

Diseminovana *Rhodococcus equi* infekcija kod bolesnice sa Hočkinovim limfomom

Dragan Mikić^{*†}, Zoran Djordjević[‡], Leosava Sekulović[‡], Miroslav Kojić^{*},
Branka Tomanović[§]

^{*}Clinic for Infectious and Tropical Diseases, [‡]Institute for Radiology, [§]Institute for Microbiology, Military Medical Academy, Belgrade, Serbia; [†]Faculty of Medicine of the Military Medical Academy, University of Defence, Belgrade, Serbia

Abstract

Introduction. *Rhodococcus (R) equi* is an opportunistic, uncommon human pathogen that causes mainly infection in immunocompromised hosts. The disease is usually presented as subacute pneumonia that is mostly cavitary and sometimes bacteremic. **Case report.** We reported the extremely rare case of a 43-year-old woman with Hodgkin lymphoma, who developed *R. equi* pulmonary infection after receiving multiple courses of chemotherapy. Secondary, the patient developed bacteremia, leading to sepsis and dissemination of *R. equi* infection in many extrapulmonary sites. At admission the patient was febrile, tachypnoic, tachycardic, hypotensive, with facial edema, splenomegaly, positive meningeal signs, left hemiparesis and paraparesis. Laboratory data included erythrocyte sedimentation rate (ESR) > 140 mm/h, C-reactive protein (CRP) 143.0 mg/L, red blood cells (RBC) $2.14 \times 10^{12}/L$, white blood cells (WBC) $2.8 \times 10^9/L$, lactate dehydrogenase (LDH) 706 U/L, serum albumin 26 g/L, sodium 127 mmol/L and potassium 2.7 mmol/L. Blood culture and culture of sputum and empyema were positive for *R. equi*. Imaging studies demonstrated a large right cavitary pneumonia and abscess, empyema, pericarditis, mediastinal and intra-abdominal lymphadenopathy, brain and psoas abscesses, osteomyelitis and spondylodiscitis. The patient recovered completely after a 12-month treatment with combinations of parenteral and oral antibiotics (meropenem, vancomycin, teicoplanin, ciprofloxacin, rifampicin, macrolides etc), including drainage of abscesses and empyema. Eight years after completion of the treatment the patient was without recurrence of *R. equi* infection and lymphoma. **Conclusion.** Since the eradication of *R. equi* is very difficult, it is very important to make the diagnosis and initiate appropriate antibiotic therapy as soon as possible.

Key words: rhodococcus equi; hodgkin disease; immunologic deficiency syndromes; infection; sepsis; anti-bacterial agents; drug therapy, combination.

Apstrakt

Uvod. *Rhodococcus (R) equi* je oportuni patogen koji retko uzrokuje oboljenje u humanoju populaciji, uglavnom kod imunokompromitovanih domaćina. Oboljenje se obično ispoljava kao subakutna pneumonija koja je često kavitarna i neretko praćena bakterijemijom. **Prikaz bolesnika.** Prikazujemo veoma redak slučaj bolesnice stare 43 godina sa Hočkinovim limfomom, kod koje je došlo do razvoja *R. equi* pneumonije u toku primene hemoterapije. Kasnije, kod bolesnice je došlo do razvoja bakterijemije i sepsis uz diseminaciju *R. equi* infekcije u brojna ekstrapulmonalna tkiva. Na prijemu bolesnica je bila febrilna, tahipnoična, tahikardična, hipotenzivna, sa otokom lica, splenomegalijom, pozitivnim meningealnim znacima, levostranom hemiparezom i paraparezom. U laboratorijskim nalazima sedimentacija eritrocita (SE) bila je > 140 mm/h, C-reaktivni protein (CRP) 143,0 mg/L, eritrociti $2,14 \times 10^9/L$, leukociti $2,8 \times 10^{12}/L$, lektat dehidrogenaza (LDH) 706 U/L, serumski albumin 26 g/L, natrijum 127 mmol/L i kalijum 2,7 mmol/L. Hemokulturom i kulturom sputuma i empijema izolovan je *R. equi*. Radiološke metode registrovale su veliku kavitarnu pneumoniju i apsces pluća, empijem pleure, perikarditis, medijastinalnu i abdominalnu limfadenopatiju, apsces mozga i psoasa, osteomijelitis i spondilodiscitis. Bolesnica se potpuno oporavila nakon 12 meseci terapije kombinacijama parenteralnih i peroralnih antibiotika, uz primenu drenaže apscesnih kolekcija i empijema. Osam godina po završenoj terapiji kod bolesnice nije zabeležen recidiv *R. equi* infekcije niti limfoma. **Zaključak.** S obzirom na to da je eradicacija *R. equi* veoma teška, od velike je važnosti što ranije postaviti dijagnozu i otpočeti adekvatnu antibiotsku terapiju.

Ključne reči: rhodococcus equi; hodžkinova bolest; imunitet, sindromi nedostatka; infekcija; sepsa; antibiotici; lečenje, kombinovano.

Introduction

Rhodococcus equi *R. equi* is an opportunistic, gram-positive, weak acid-fast aerobic *coccobacillus* that primarily causes zoonotic infections and is usually present in soil and feces of horses^{1,2}. Although natural exposure to *R. equi* is frequent, the first infection by this organism in humans was described in 1967³. Overall, a few hundred cases of *R. equi* infections in humans have been reported till now. The disease is typically described in immunocompromised hosts, especially in patients with acquired immunodeficiency syndrome (AIDS), and less than 15% of the patients have hematopoietic and other malignancies⁴⁻¹³. The most often, *R. equi* causes a subacute, cavitary and bacteriemic pneumonia

the implementation of various parenteral and peroral antibiotics in a multiple short courses, the progression of acquired pneumonia in the right lung was registered and the permanent deterioration of general condition.

Chemotherapy was discontinued in March 2003. In order to maintain intra-abdominal lymphadenopathy radiotherapy was performed. In the following period, in addition to high temperature and expectoration of the purulent sputum, a pain in the left hip occurred. Computed tomography showed the presence of a large abscess and pneumonia in the right lung, pleural effusion on the right side and paraaortic lymphadenopathy of more than 2 cm. Magnetic resonance imaging registered progressive spondylodiscitis L2/L3 and psoas abscess at the left side (Figure 1).

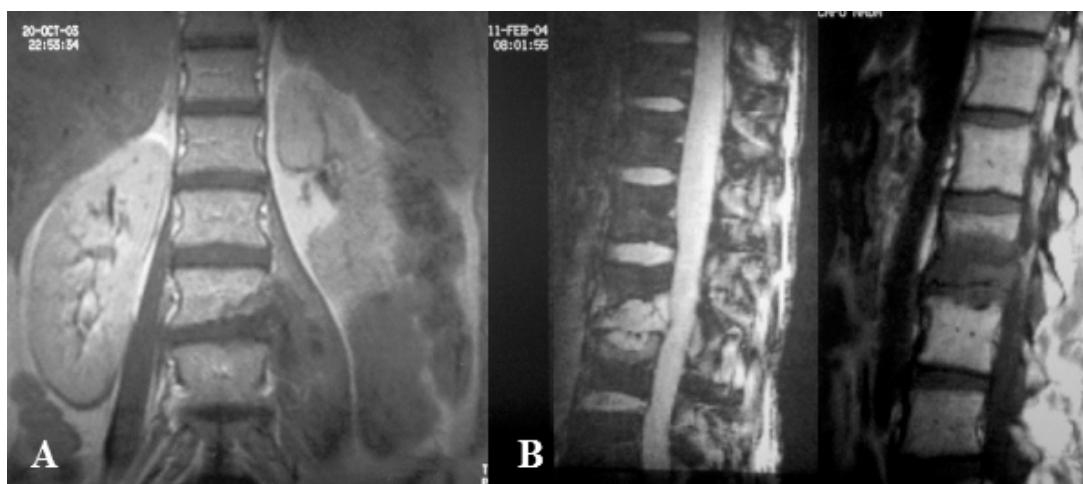


Fig. 1 – Magnetic resonance imaging of the lumbar spine in the presented patient with disseminated *R. equi* infection: progressive spondylodiscitis L2/L3 and psoas abscess of the left side.

which is characterised by frequent relapses and a high mortality rate. Extrapulmonary disease is usually a late manifestation of the initial pulmonary infection^{4-9, 14-18}.

We reported an extremely rare case of disseminated *R. equi* infection in a patient with Hodgkin lymphoma who was successfully treated with antibiotics and drainage of abscesses. To the best of our knowledge, this is the first documented case of *R. equi* infection in Serbia.

Case Report

A 43-year-old woman was admitted to the Clinic for Infectious and Tropical Diseases of Military Medical Academy, Belgrade due to disseminated *R. equi* infection on April 8, 2004. She became ill on February 2001 with the appearance of fever, malaise and enlarged lymph nodes in the right inguinal region. At that period of time, the patient worked hard as a lawyer, for several months, at a farm near the village she lived in. One year later, a generalized lymphadenopathy occurred and the Hodgkin lymphoma was diagnosed. After 7 cycles of chemotherapy, in October 2002, the patient developed high fever, chills, cough, and severe pain in the right hemithorax. On chest radiography loose shadow in the right lung with pleural effusion was registered. Despite

During July, 2003 pathohistological examination of the material obtained by biopsy of the right pulmonary infiltration showed pulmonary malacoplakia. In late 2003 blood culture and cultures of the sputum and pleural empyema were positive on *R. equi*. Prolonged use of parenteral antibiotics according to the antibiogram with blood transfusions, human albumin and other replacement therapy resulted in improvement of the patient's general condition, normalization of body temperature and marked regression of the right pulmonary infiltration. However, on February 2004 the patient developed to allergic reaction to vancomycin and soon after, hemolytic anemia occurred. By the end of March, new relapse was registered. According to high fever, dizziness, headache, nausea, vomiting, cough, expectoration of purulent sputum, hemoptysis and chest pain, a positive meningeal signs were detected. Computerized tomography (CT) scan showed large nodular lesion with cavitation in right lung. This lesion was in a close contact with the vena cava superior, pericard and right hilus. An oval lesion 10 cm in diameter has also been registered in the basal region of the chest, that was in contact with right chest wall and destruction of left ribs 9 and 10 (Figure 2). A lumbar puncture was not performed because of the presence of lumbar spine abscess collection. At that time the patient was admitted to the

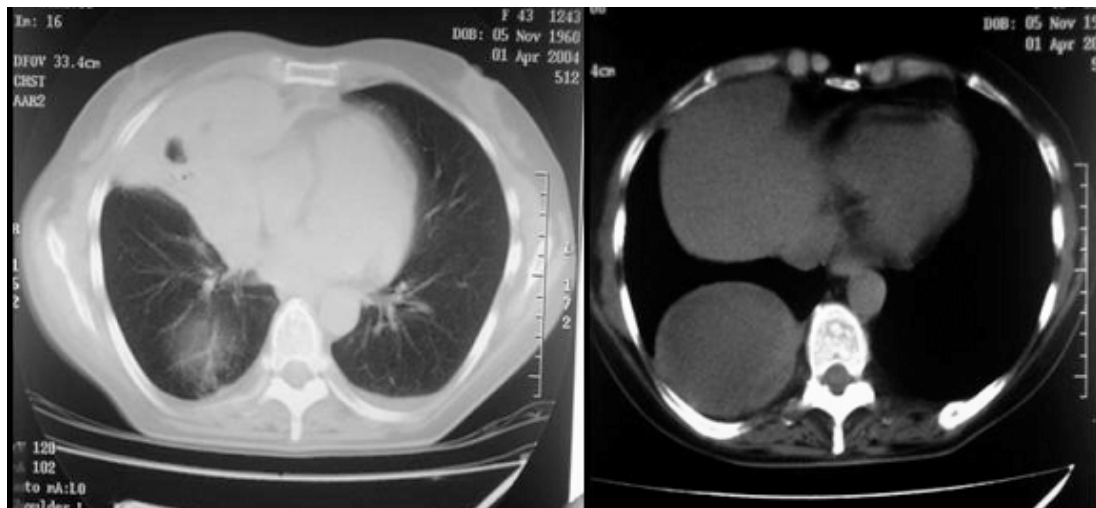


Fig. 2 – Computed tomography of the chest in the presented patient: large cavitary pneumonia and abscess in the right lung.

Clinic for Infectious and Tropical Diseases of Military Medical Academy, Belgrade.

At admission the patient was in a very bad general condition, febrile (38.5°C), asthenic, hardly moving, with facial edema, tachypnoic, tachycardic and hypotensive. In the physical findings silent breathing in the lower parts of the right lung, splenomegalia, positive meningeal signs, left side hemiparesis and paraparesis were registered.

Laboratory data included ESR > 140 mm/h, fibrinogen 5.8 g/L, CRP 143.0 mg/L, RBC $2.14 \times 10^{12}/L$, Hb 66 g/L, WBC $2.8 \times 10^9/L$, neutrophils 84.7%, platelets (PLT) $542 \times 10^9/L$, bilirubin 25 $\mu\text{mol}/L$, serum protein 54 g/L, serum albumin 26 g/L, gamma GT 80 U/L, LDH 706 U/L, sodium 127 mmol/L, potassium 2.7 mmol/L, iron 5 mmol/L, cholesterol 3.4 mmol/L, γ globulin 19.8%. Direct and indirect

ampicin, fluoroquinolons, glycopeptids, carbapenems, amikacin and amoxicilin-clavulaxate, but resistant to cephalosporins, piperacillin-tazobactam, clindamycin, amoxicillin and gentamicin.

Infiltration connected with right hilus and nodular lesion in posterobasal region of the right lung, diameter of 9 cm, were registered on chest radiography examination. Radiography of LS spine showed pathologic fracture of L2 corpus with a wedge-shaped deformation (Figure 3).

Pericardial effusion of 1.4 cm was registered on echocardiography and splenomegaly of 16 cm on the abdominal ultrasound. CT scan of the brain showed hypodense zones 4 mm in diameter in crus posterior of the right capsula interna and left olive, which did not change their characteristics after intravenous admission of the contrast.

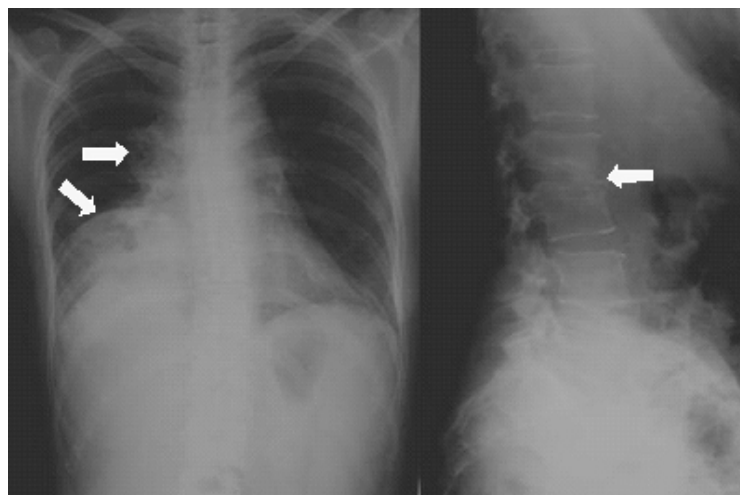


Fig. 3 – Radiography of the chest and lumbar spine in the presented patient at admission.

Coombs tests were positive. Serological analyses to hepatitis B and C, and human immunodeficiency viruses were negative.

Blood culture and sputum and empyema cultures were positive for *R. equi*. *R. equi* was sensitive to macrolides, rif-

Immediately after admission the therapy with meropenem and rifampicin started. After 7 days ciprofloxacin and amikacin were added. After 14 days amikacin was excluded and teicoplanin was added (Table 1). During the first month the patient received immunoglobulins, human albumin, fresh

Table 1

Combined antibiotic therapy in a patient with disseminated *R. equi* infection during the first month of hospitalization in 2004

Antibiotics	Dosage	Application	Therapy duration
Meropenem	1 gr / 8 h / daily	<i>iv</i> infusion	April 4 – May 5
Ciprofloksacin	200 mg / 12 h / daily	<i>iv</i> infusion	April 15 – Maj 8
Amikacin	1 gr / 24 h /daily	<i>iv</i>	April 15 – April 29
Teikoplanin	400 mg / 24 h /daily	<i>iv</i> infusion	April 29 – May 15
Rifampicin	600 mg / daily	per os	April 4 – May 12

frozen plasma, cryoprecipitate, filtered erythrocytes and symptomatic therapy which led to normalization of the temperature, improvement of general condition and laboratory values. At control chest CT, regression of lung changes was noticed. In the region of the middle lobe, retrosternally and paracardially, a zone of consolidation of the lung parenchyma with cavitation of 5×3 cm was registered. Up to the back thoracic wall in the right posterobasal region, encapsulated liquid collection of 6×7 cm in diameter was noticed. There was a large number of lymph nodes of about 2 cm in diameter in mediastinum, paratracheally and up to the arcus aortae (Figure 4).

A combined antibiotic treatment was continued also including meropenem, ciprofloxacin, vancomycin, rifampicin, trimethoprim-sulfamethoxazole and lincomycin. By the end of August 2004, drainage of abscess collection diameter of 10 cm in the left psoas was performed (Figure 5). A parenteral antibiomatic therapy was continued for six months more and than was changed with peroral antibiotics (rifampicin, azithromycin, roxithromycin, eritromycin, linkomycin, clarithromycin, ciprofloxacin, trimethoprim-sulfamethoxazole) up to 12 months. At discharge from the Clinic, on February 1, 2005, the patient was in good general condition with lumbar pain and normal laboratory values.

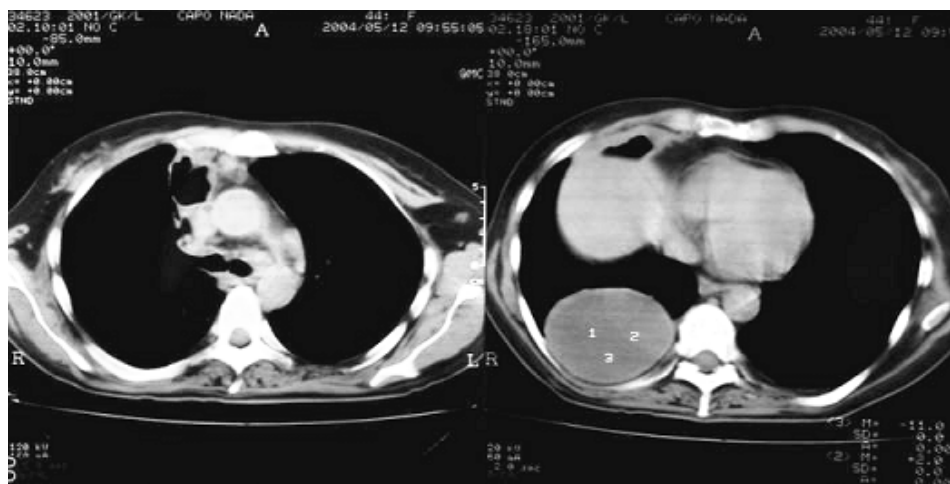


Fig. 4 – Computed tomography of the chest in the presented patient with disseminated *R. equi* infection after a month of combined antibiotic therapy.

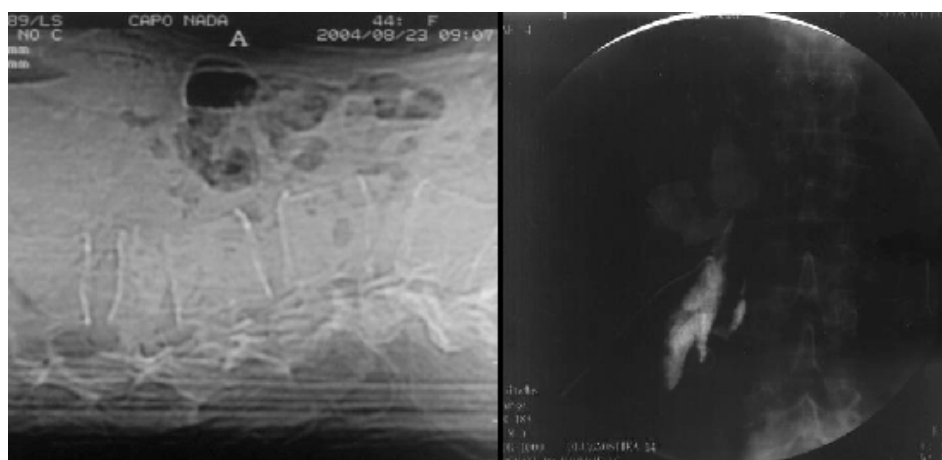

Fig. 5 – Computed tomography and radiography of lumbar spine show a psoas abscess in the presented patient.

Four months later, MRI of the lumbar spine showed cured spondylodiscitis L2/L3 with kyphosis deformity. There were no signs of paravertebral infection (Figure 6).

Five months after therapy cessation, CT scan showed scared lesions in basal paracardial regions of the right lung and incapsulated liquid collection 4 cm in diameter in the posterobasal region of the same lung. Mediastinal lymph nodes were not enlarged (Figure 7).

Eight years after treatment cessation the patient was without recurrence of *R. equi* infection and lymphoma. Meanwhile, fluid collection in the right lung was completely and spontaneously regressed (Figure 8).

Discussion

R. equi is an opportunistic pathogen well described in veterinary science as a causative agent of pneumonia and sepsis in domestic animals, and a leading cause of chronic pneumonia in foals less than six months of age^{1,2}. However, its role in the etiology of human diseases is much less known. Human *R. equi* infection was described in 1967 for the first time in a patient with autoimmune hepatitis, who suffered from cavitory pneumonia after immunosuppressive treatment³. In the next 15 years only 12 cases of this illness have been reported. After that, the frequency of *R. equi* in-

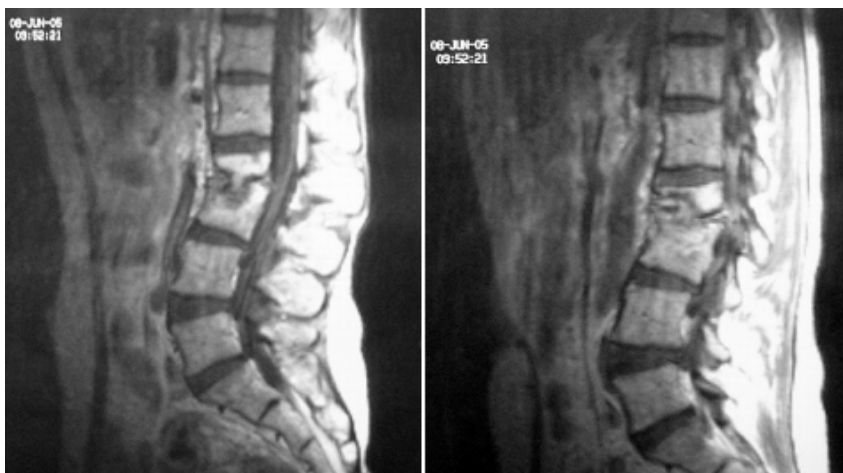

Fig. 6 – Magnetic resonance imaging of the lumbar spine 2 months after antibiotic treatment cessation.

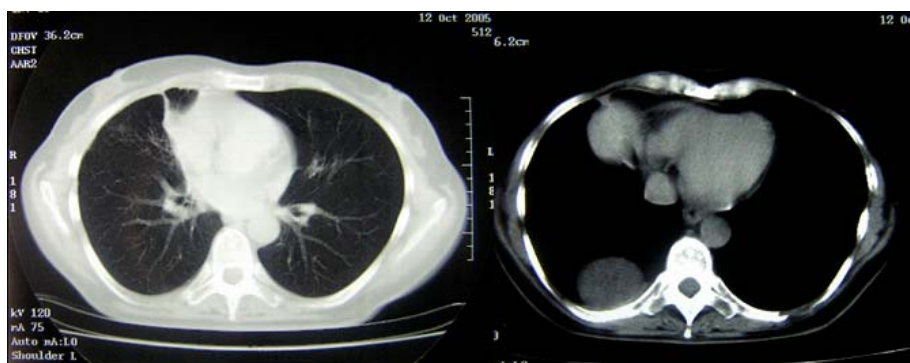

Fig. 7 – Computed tomography of the chest in the presented patient 5 months after the antibiotic therapy completion.

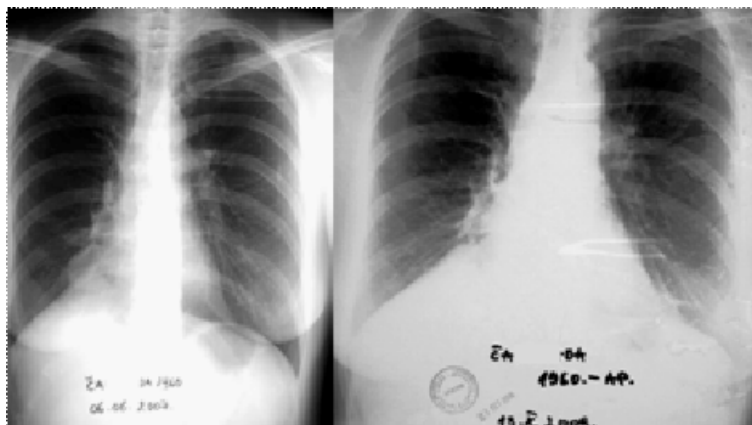


Fig. 8 – Radiography of the chest in the presented patient few years after the antibiotic therapy

fection begins to increase along with the increasing number of immunocompromised hosts, particularly the number of AIDS patients^{4,19-21}.

R. equi has been isolated from almost each specimen and tissue of domestic and wild animals. It has been isolated from soil on 50%–90% farms on each continent, except Antarctic. Concentration of *R. equi* is especially high in feces of horses. From that reason direct and indirect contact with domestic animals could have an important role in development of human *R. equi* infection. The infection occurs through inhalation, ingestion and inoculation^{1, 2, 22-24}. We assume that the presented patient acquired *R. equi* infection most probably by inhalation, working at the farm of horses. However, we are not sure when the infection actually occurred.

Like the other authors, we assume that regional lymphadenitis was caused by dissemination of *R. equi* infection from the primary focus^{20, 25}. However, we are not absolutely sure what was the role of *R. equi* infection in the development of mediastinal and intra-abdominal lymphadenopathy in the presented patient. Namely, chemotherapy of Hodgkin lymphoma was interrupted when the patient had significant mediastinal and intraabdominal lymphadenopathy, and this lymphadenopathy just withdrew after a long-term of a combined antibiomatic therapy. This indicates that the most likely cause of lymphadenitis was *R. equi*.

The most important factor in the development of *R. equi* infection is impaired cellular immunity. This is confirmed by the results of the study conducted in HIV positive persons, which showed that *R. equi* infection is more common in patients with blood CD4 + lymphocytes count less than 100/mm³. For that reason the disease is more frequent in the patients with AIDS and on immunosuppressive therapy after solid organ or bone marrow transplantation, but very rare in healthy immunocompetent persons^{6, 7, 8, 20, 26, 27}. This explains why there was continuous impairment of lung inflammatory process in the presented patient and why the dissemination of *R. equi* infection appeared. However, the delayed diagnosis and inadequate antibiotic therapy has also contributed to the frequent relapses and dissemination of the disease. Namely, bacteriemia, relapses and dissemination of the infection also registered after chemotherapy cessation and making the diagnosis. According to data from the literature, relapses, bacteriemia and visceral dissemination of *R. equi* infection rarely occurs in HIV negative persons in contrast to the patients with AIDS^{4, 14, 16, 27-30}.

Clinical manifestations of *R. equi* infection may be different, but the disease is usually manifested with respiratory symptoms and signs. The most frequent form of *R. equi* infection is chronic, progressive, granulomatous and necrotizing inflammation which is cavitary in 2/3 of the patients. The other manifestations of respiratory infection are nodular infiltrates which can be complicated by lung abscesses, empyema, pleural effusion and spontaneous pneumothorax^{6, 7, 8, 20, 27}. Extrapulmonary *R. equi* infection can be primary and secondary, and usually is a late manifestation of initial lung infection as was the case in our pa-

tient. It is a multisystemic or local disease, usually presented as sepsis, fever of unknown origin, cerebral abscess, meningitis, pericarditis, osteomyelitis, subcutaneous abscess, regional lymphadenitis, mastoiditis, or wound infection^{18, 25, 27, 31-36}. Because of the delayed diagnosis and treatment, frequent bacteremias and dissemination of *R. equi* infection, almost all of these manifestations were seen in our patient. However, we should not forget that in such cases disease progression is registered in about 10% of patients, despite adequate therapy^{4, 20, 27}.

Optimal treatment regimen and optimal duration of antibiotic therapy in patients with *R. equi* infection are not exactly defined. Combined antibiotic treatment is the cornerstone of the therapy for *R. equi* infection, but surgical incision and drainage of abscess formation can also be useful. Treatment of severe forms of the disease should start with combined parenteral antibiotics and after clinical and laboratory improvement should switch to a combined peroral antibiotic therapy, we also applied³⁷⁻⁴³. Because of high incidence of bacteriemia and large bacterial inoculum it is necessary to apply adequate combination of antibacterial drugs with bactericidal activity, with simultaneous application of lipophilic antibiotics with good intracellular penetration. It is believed that antibiotics combination which includes carbapenems (meropenem, imipenem), glycopeptides (vancomycin, teicoplanin), macrolides and rifampicin can be optimal^{4, 20, 27, 37-43}. That was the way we started and continued antibiotic treatment for exactly one year, that resulted in a complete success. Some authors recommend combinations with two or even more antibiotics with intracellular activity, while the others put accent on the bactericidal antimicrobial agents, especially during the initial phase of treatment³⁷⁻⁴³. We appreciated the views of both authors and conducted the treatment with four antimicrobial drugs, guided by antibiogram, in a long period of time. After careful consideration, we anticipated that there was no allergic reaction to vancomycin in our patient, actually it was "red woman" phenomenon, so we continued the treatment with glycopeptides successfully. At the same time great attention was paid to the volume replacement therapy and to the fact that drainage of large abscess collection in those with *R. equi* infection should be done whenever possible.

Conclusion

Human *R. equi* infection is a very rare disease usually affecting those with severe immunodeficiencies. The delayed diagnosis is very frequent, despite the advances in knowledge about the causative agent. The most important step in making diagnosis is a clinical suspicion of the disease and after that, microbiological analyses from the adequate specimens. Since it is almost impossible to eradicate *R. equi*, it is very important to make a diagnosis and start therapy as soon as possible. Antimicrobial therapy is based on a combination of antibacterial drugs with bactericidal activity and drugs with good intracellular penetration and applied for a long period of time.

R E F E R E N C E S

- Zink MC, Yager JA, Smart NL. *Corynebacterium equi* infections in horses, 1958-1984: A review of 131 cases. *Can J Vet Res* 1986; 27(5): 213-7.
- Takai S, Ohbuschi S, Koike K, Tsubaki S, Oishi H, Kamada M. Prevalence of virulent *Rhodococcus equi* in isolates from soil and feces of horses from horse-breeding farms with and without endemic infections. *J Clin Microbiol* 1991; 29(12): 2887-9.
- Golub B, Falk G, Spink WW. Lung abscess due to *Corynebacterium equi*. Report of first human infection. *Ann Med* 1967; 66(6): 1174-7.
- Mikić D. *Rhodococcus equi* infection. *Vojnosanit Pregl* 2006; 63(11): 957-62. (Serbian)
- Yamschikov AV, Schuetz A, Lyon MG. *Rhodococcus equi* infection. *Lancet Infect Dis* 2010; 10(5): 350-9.
- Topino S, Galati V, Grilli E, Petrosillo N. *Rhodococcus equi* infection in HIV-infected individuals: case reports and review of the literature. *AIDS Patient Care STDS* 2010; 24(4): 211-22.
- Perez MG, Vassilev T, Kemmerly SA. *Rhodococcus equi* infection in transplant recipients: a case of mistaken identity and review of the literature. *Transplant Infect Disease* 2002; 4(2): 52-6.
- Kedlaya I, Ing MB, Wong SS. *Rhodococcus equi* Infections in Immunocompetent Hosts: Case Report and Review. *Clin Infect Dis* 2001; 32(3): E39-46.
- Stolk-Engelaar MV, Dompeling EC, Meis JF, Hoogkamp-Korstanje JA. Disseminated Abscesses Caused by *Rhodococcus equi* in a Patient with Chronic Lymphocytic Leukemia. *Clin Infect Dis* 1995; 20(2): 478-9.
- Meuse JJ, Sprenger HG, van Assen S, Leduc D, Daenen SM, Arends JP, et al. *Rhodococcus equi* infection after alemtuzumab therapy for T-cell prolymphocytic leukemia. *Emerg Infect Dis* 2007; 13(12): 1942-3.
- Borghi E, La FM, Gazzola L, Marchetti G, Zonato S, Foa P, et al. *Rhodococcus equi* infection in a patient with spinocellular carcinoma of unknown origin. *J Med Microb* 2008; 57(11): 1431-3.
- Al AF, Al WI, Chaftari A, Reitzel R, Jiang Y, Ghannoum M, et al. *Rhodococcus Bacteremia* in Cancer Patients Is Mostly Catheter Related and Associated with Biofilm Formation. *PLoS ONE* 2012; 7(3): e 32945.
- Farina C, Ferruzzi S, Mamprin F, Vailati F. *Rhodococcus equi* infection in non-HIV-infected patients. Two case reports and review. *Clin Microbiol Infect* 1997; 3(1): 12-8.
- Gabriels P, Joosen H, Put E, Verhaegen J, Magerman K, Cartuyvels R. Recurrent *Rhodococcus equi* infection with fatal outcome in an immunocompetent patient. *Eur J Clin Microbiol Infect Dis* 2006; 25(1): 46-8.
- Wicky S, Cartei F, Mayor B, Frija J, Gevenois PA, Giron J, et al. Radiological findings in nine AIDS patients with *Rhodococcus equi* pneumonia. *Eur Radiol* 1996; 6(6): 826-30.
- Alonso P, Tashima KT, Goldstein JJ. Disseminated *Rhodococcus equi* infection. *Clin Infect Dis* 2001; 18(2): 125-35.
- Barsotti M, Cupisti A, Morelli E, Meola M, Barsotti G. Sepsis from *Rhodococcus equi* successfully treated in a kidney transplant recipient. *Nephrol Dial Transplant* 1997; 12(9): 2002-4.
- Kamboj M, Kaira A, Kak V. *Rhodococcus equi* brain abscess in patient without HIV. *J Clin Pathol* 2005; 58(4): 423-5.
- Sane DC, Durack DT. Infection with *Rhodococcus equi* in AIDS. *New Engl J Med* 1986; 314(1): 56-7.
- Scott MA, Graham BS, Verrall R, Dixon R, Schaffler W, Tharn KT. *Rhodococcus equi*: an increasingly recognized opportunistic pathogen. Report of 12 cases and review of 65 cases in the literature. *Am J Clin Pathol* 1995; 103(5): 649-55.
- Gray KJ, French N, Lugada E, Watera C, Gilks CF. *Rhodococcus equi* and HIV-1 infection in Uganda. *J Infect* 2000; 41(3): 227-31.
- Takai S. Epidemiology of *Rhodococcus equi* infections: a review. *Vet Microbiol* 1997; 56(3-4): 167-76.
- Giguère S, Cohen ND, Chaffin KM, Hines SA, Hondalus MK, Prescott JF, et al. *Rhodococcus equi*: clinical manifestations, virulence, and immunity. *J Vet Intern Med* 2011; 25(6): 1221-30.
- Guerrero R, Bhargava A, Nableh Z. *Rhodococcus equi* venous catheter infection: a case report and review of the literature. *J Medical Case Reports* 2011; 5(1): 358-64.
- Lee-Chiong T, Sadigh M, Simms M, Buller G. Case reports: pericarditis and lymphadenitis due to *Rhodococcus equi*. *Am J Med Sci* 1995; 310(1): 31-3.
- Arlotti M, Zoboli G, Moscatelli GL, Magnani G, Maserati R, Borghi V, et al. *Rhodococcus equi* infection in HIV-positive subjects: a retrospective analysis of 24 cases. *Scand J Infect Dis* 1996; 28(5): 463-7.
- Torres-Tortosa M, Arrizabalaga J, Villanueva JL, Gálvez J, Leyes M, Valencia EM, et al. Prognosis and clinical evaluation of infection caused by *Rhodococcus equi* in HIV-infected patients: a multicenter study of 67 cases. *Chest* 2003; 123(6): 1970-6.
- Giacometti A, Cirioni O, Burzacchini F, Del PM, Balducci M, Al NI, et al. *Rhodococcus equi* infections: antibiotic therapy and relapses. *AIDS* 1997; 11(1): 120-1.
- Ferretti F, Boschini A, Iabichino C, Gerevini S, De NP, Guffanti M, et al. Disseminated *Rhodococcus equi* infection in HIV infection despite highly active antiretroviral therapy. *BMC Infect Dis* 2011; 11: 343.
- Ibarra R, Jinkins JR. Severe otitis and mastoiditis due to *Rhodococcus equi* in a patient with AIDS. Case report. *Neuroradiology* 1999; 41(9): 699-701.
- Pardo ML, Faubel SM, Llaveró SM, Cano CB, Pérez CF, Giménez VF, et al. Laryngeal infection by *Rhodococcus equi* in patient with AIDS. *Acta Otorrinolaringol Esp* 2002; 53(10): 783-8. (Spanish)
- Napoleao F, Damasco PV, Camello TC, do Vale MD, de Andrade AF, Hirata R, et al. Pyogenic liver abscess due to *Rhodococcus equi* in an immunocompetent host. *J Clin Microbiol* 2005; 43(2): 1002-4.
- DeMarais PL, Kocka FE. *Rhodococcus Meningitis* in an Immunocompetent Host. *Clin Infect Dis* 1995; 20(1): 167-9.
- Kohl O, Tillmanns HH. Cerebral infection with *Rhodococcus equi* in a heart transplant recipient. *J Heart Lung Transplant* 2002; 21(10): 1147-9.
- Novak RM, Polisky EL, Janda WM, Libertin CR. Osteomyelitis caused by *Rhodococcus equi* in a renal transplant recipient. *Infection* 1988; 16(3): 186-8.
- Adal KA, Shiner PT, Francis JB. Primary subcutaneous abscess caused by *Rhodococcus equi*. *Ann Intern Med* 1995; 122(4): 317.
- Chavanet P, Bonnotte B, Caillot D, Portier H. Imipenem/teicoplanin for *Rhodococcus equi* pulmonary infection in AIDS patients. *Lancet* 1991; 337(8744): 794-5.
- Rouquet RM, Clave D, Massip P, Moatti N, Leophonte P. Imipenem/vancomycin for *Rhodococcus equi* pulmonary infection in HIV-positive patient. *Lancet* 1991; 337(8737): 375.
- el Karoui K, Guillet C, Sekkal N, Lanternier F, Méchaï F, Hue K, et al. Synergistic effect of carbapenem-teicoplanin combination during severe *Rhodococcus equi* pneumonia in a kidney transplant recipient. *Transpl Infect Dis* 2009; 11(4): 359-62.

40. *Stiles BM, Isaacs RB, Daniel TM, Jones DR.* Role of surgery in *Rhodococcus equi* pulmonary infections. *J Infect* 2002; 45(1): 59–61.
41. *Muñoz P, Palomo J, Guinea J, Yañez J, Giannella M, Bouza E.* Relapsing *Rhodococcus equi* infection in a heart transplant recipient successfully treated with long-term linezolid. *Diagn Microbiol Infect Dis* 2008; 60(2): 197–9.
42. *Russo G, Lichtner M, Carnevalini M, Mascellino MT, Mengoni F, Oliva A, et al.* Primary retroperitoneal abscesses due to *Rhodococcus equi* in a patient with severe nephrotic syndrome: successful antibiotic treatment with linezolid and tigecycline. *Int J Infect Dis* 2010; 14(6): e533–5.
43. *Scotton PG, Tonon E, Giobbia M, Gallucci M, Rigoli R, Vaglia A.* *Rhodococcus equi* nosocomial meningitis cured by levofloxacin and shunt removal. *Clin Infect Dis* 2000; 30(1): 223–4.

Received on December 18, 2012.

Accepted on March 13, 2013.

OnLine-First July, 2013