



Massive retroperitoneal hematoma as a complication of anticoagulation therapy in a patient treated in a pulmonary intensive care unit

Masivni retroperitoneumski hematom kao komplikacija antikoagulantne terapije kod bolesnika lečenog u pulmološkoj jedinici intenzivne nege

Mihailo Stjepanović*, Ivana Buha*, Snežana Raljević*†, Uroš Babić‡, Milan Savić*§, Jovana Mašković*, Marina Rokсандić*, Dragana Marić**†

*Clinic of Pulmonary Diseases, §Clinic for Thoracic Surgery, ‡Clinic of Urology, Clinical Center of Serbia, Belgrade, Serbia; †Faculty of Medicine, University of Belgrade, Belgrade, Serbia

Abstract

Introduction. Retroperitoneal hematoma may occur as a result of trauma, but also from rupture of arterial aneurysms (aortic or iliac), surgical complications, tumors or anticoagulation therapy. **Case report.** We presented a patient on permanent anticoagulation therapy. On the day of admission to our institution, the patient had the value of his INR 5.57 which required immediate suspension of the therapy. The main symptom in this patient was pain in the right inguinal canal with propagation along the right leg, which was indicated in clinical picture of spontaneous retroperitoneal haematoma. After three days the fall of hemoglobin occurred, so the additional diagnostics was done. A computed tomography of the abdomen was performed showing well limited, large retroperitoneal hematoma (213 × 79 × 91 mm). Transfusion of concentrated red blood cells was performed twice with satisfactory correction of hemoglobin level, and four units of fresh frozen plasma. The patient was hemodynamically stabilized and discharged after a two-month long intensive care unit treatment, with the advice to use low-molecular weight heparin 2 × 0.4 mg subcutaneously, due to persistent arrhythmia. **Conclusion.** In patients on anticoagulation therapy regular monitoring of the anticoagulant status is extremely important, because of the possibility of fatal complications development, such as retroperitoneal hematoma.

Key words:

anticoagulants; drug toxicity; hemorrhage; hematoma; retroperitoneal space; treatment outcome.

Apstrakt

Uvod. Retroperitoneumski hematom može nastati kao rezultat traume, rupture aneurizme arterije (aortne ili ilijačne), hirurške komplikacije, tumora ili antikoagulantne terapije. **Prikaz bolesnika.** Prikazali smo bolesnika na trajnoj antikoagulantnoj terapiji koji je na dan prijema u našu ustanovu imao vrednost INR 5,57. Odmah je obustavljena antikoagulantna terapija. Bolesnik je od tegoba navodio i bolove u desnom ingvinalnom kanalu koji su zračili duž desne noge, što se uklapalo u kliničku sliku spontanog retroperitoneumsku hematoma. Posle tri dana došlo je do sniženja nivoa hemoglobina, tako da je primenjena dopunska dijagnostika. U nalazu dobijenom kompjuterizovanim tomografijom abdomena opisan je dobro ograničen retroperitoneumski hematom velikih dimenzija (213 × 79 × 91 mm). Primenjena je transfuzija koncentrovanih eritrocita koja je dovela do zadovoljavajuće korekcije nivoa hemoglobina. Bolesnik je dobio i četiri jedinice sveže smrznute plazme. Nakon što je hemodinamski stabilizovan, otpušten je iz jedinice intenzivne nege, posle dvomesečnog lečenja. Savetovano mu je da zbog perzistentne aritmije koristi niskomolekulski heparin 2 × 0,4 mg potkožno. **Zaključak.** Kod bolesnika na antikoagulantnoj terapiji izuzetno je značajno redovno praćanje njihovog antikoagulantnog statusa, upravo zbog razvoja ponekad i fatalnih komplikacija, kao što je spontani retroperitonealni hematom.

Ključne reči:

antikoagulansi; lekovi, toksičnost; krvarenje; hematom; retroperitonealni prostor; lečenje, ishod.

Introduction

Retroperitoneal hematoma (or retroperitoneal bleeding) refers to accumulation of blood in the retroperitoneal space.

It is most frequently seen after femoral artery catheterisation or pelvic and lumbar trauma¹. Also, retroperitoneal hemorrhage can be the result of ruptured abdominal aortic aneurysm or some kidney or adrenal gland conditions. Spontane-

ous retroperitoneal hemorrhage refers to bleeding without trauma or retroperitoneal pathology. Spontaneous retroperitoneal hematomas is rare but potentially life threatening condition and it is almost always seen in association with anticoagulation therapy, coagulopathies and in patients on hemodialysis².

The incidence of retroperitoneal hematoma has been reported to be 0.6–6.6% in patients on oral anticoagulant therapy³.

Coumarins are vitamin K antagonists that produce their anticoagulant effect by interfering with the cyclic interconversion of vitamin K and its 2,3 epoxide (vitamin K oxide). Vitamin K antagonists inhibit carboxylation of the regulatory anticoagulant protein C and S and therefore have the potential to exert a procoagulant effect⁴.

Drugs may influence the pharmacodynamics of warfarin by inhibiting synthesis or increasing clearance of vitamin K-dependent coagulation factors or by interfering with other pathways of hemostasis.

Drugs such as aspirin, nonsteroidal anti-inflammatory drugs, high doses of penicillins and moxolactam increase the risk of warfarin-associated bleeding by inhibiting platelet function. The mechanisms by which erythromycin and some anabolic steroids potentiate the anticoagulant effect of warfarin are unknown. Sulfonamides and several broad-spectrum antibiotic compounds may augment the anticoagulant effect of warfarin by eliminating bacterial flora and aggravating vitamin K deficiency in patients whose diet is deficient of vitamin K⁴.

It would be reasonable to monitor the prothrombin time (PT) more frequently when any drug therapy is added or withdrawn from the regimen of a patient treated with an oral anticoagulant drug.

According to the literature when the value of international normalised ratio (INR), that is standardized measure of protrombin time, ≥ 5 , the risk of bleeding increases 3.6 times compared to the referent range of 2.0–3.0⁵. Patients on oral anticoagulant therapy with $\text{INR} \geq 6$ are faced with the risk of major, life-threatening bleeding⁶.

We presented a patient treated in the pulmonary intensive care unit, with a large retroperitoneal hematoma, as the result of complication of anticoagulant therapy.

Case report

A 73-year-old male patient was transferred to the Pulmonary Intensive Care Unit from the Coronary Care Unit, Clinical Center of Serbia, because of acute partial respiratory insufficiency. He complained of exertional fatigue lasting for the last year and ten days before admission he got tired in peace. During the last five days the patient also felt pain in the right inguinal canal emitting in the right leg. The day before admission at the Coronary Care Unit strong fever, chills and dyspnea appeared and on the day of admission, his general condition deteriorated and the patient became drowsy and was hospitalized in the Coronary Care Unit with suspected pulmonary embolism. Computed tomography (CT) scan of the thorax had not confirmed the existence of pul-

monary embolism or other pathological processes in the chest. At the Coronary Care Unit echocardiography of the heart was made: dilated aortic root was found (4.0 cm), normal size of the left ventricle, thick concentric walls, ejection fraction rate of 50%, enlarged left atrium (4.6 cm), enlarged right ventricle (3.3 cm) while without free wall motion abnormalities with tricuspid regurgitation 2–3 +; indirectly measured systolic pressure in the right ventricle was 46 mm.

In his personal history we found that the patient had myocardial infarction 15 years ago, triple coronary artery bypass grafting (ACBG) was made and in February 2007 redo triple ACBG was performed and also a biological valve was implanted because of aortic valve insufficiency. The patient also had diabetes for about five years, then permanent absolute arrhythmia and was treated from gout, and was on continuous oral anticoagulant therapy. In the Coronary Care Unit the patient was treated with warfarin sodium 3.75 mg and 5 mg alternately, isosorbide-5-mononitrate 2 × 20 mg, metformine 1,000 mg 2 × 1, enalapril 10 mg, furosemid 40 mg, spironolacton 50 mg and bisoprolol 5 mg.

On the day of admission the patient was conscious, oriented, somnolent, afebrile with cyanosis and dyspnea, and decompensated heart failure with pedal edema, without sings of hemorrhagic syndrome. Through auscultation of the lung we found bilateral lower breath sounds and arrhythmic heart rate, clear tones, systolic ejection murmur of intensity grade 2. Chest radiography showed enlarged cardiac silhouette and the voluminous hilum (Figure 1). Electrocardiogram described atrial fibrillation with absolute arrhythmia of ventricles, negative T-waves in V2-V6. Blood pressure was 140/90 mmHg, while the heart frequency was 125/beats per minutes. Arterial blood gas reflected significant partial respiratory insufficiency (pH 7.40, pO₂ 5.5 kPa, pCO₂ 4.9 kPa, saturation 83%).

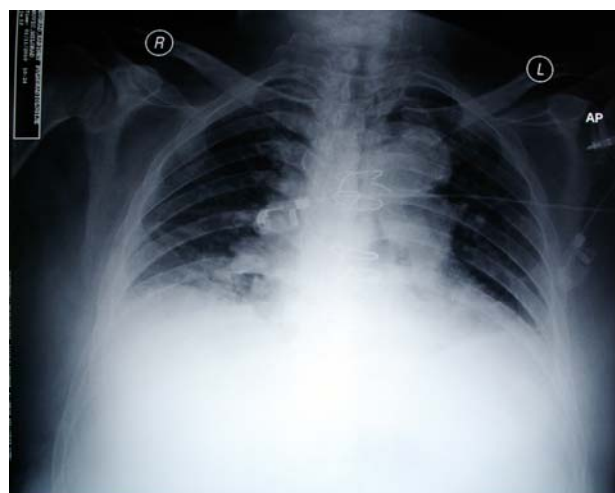


Fig. 1 – Chest radiography showed enlarged cardiac silhouette and the voluminous hilum.

Laboratory analyses were: leukocytes (Le) $14.5 \times 10^9/L$, sedimentation rate (SE) 84 mm/h, C-reactive protein (CRP) 120 mg/L, fibrinogen 7.0 g/L, urea 13.3 mmol/L (normal range 2.5–7.5 mmol/L), creatinine 169 $\mu\text{mol/L}$ (normal range 59–104), aspartate aminotransferase (AST)

108 U/L (normal range 0–37), alanine aminotransferase (ALT) 96 U/L (normal range 0–41), lactate dehydrogenase (LDH) 601 U/L (normal range 220–400), d-dimer 2.56 mg/L (normal range 0–0.55), INR 5.57. Other laboratory values were in the reference range. All the therapies prescribed by cardiologist were continued. Because of high INR values oral anticoagulant therapy was immediately discontinued and anticoagulant status of the patient was monitored every day.

Somnolence with hypoxemia despite oxygen therapy was a dominant sign of clinical features at the beginning of hospitalization, so non-invasive mechanical ventilation was applied which corrected arterial blood oxygenation. Three days later in blood analyses we registered the fall of hemoglobin level (123...94...82...68 g/L) and, at the same time, the occurrence of a large hematoma in the soft tissue of the lateral side of the right hemithorax. Ultrasound examination of the lateral chest soft tissues described hematoma in organization, with the dimension of 25 mm and the length of 35–40 mm. As there was no evident bleeding in the chest and the Adler-Weber test was negative, we decided to make the scan of abdomen. CT of the abdomen described: retroperitoneal hematoma localized between the liver and the pelvis, size 213 × 79 × 91 mm, density 24–56 HU. The right *musculus iliopsoas* and right *musculus iliacus* were edematous with signs of intramuscular hematoma, hematoma in the soft tissues of the right abdominal wall. In the infrarenal part of the abdominal aorta the aortic wall had sclerotic aneurysm of the

of medication and for future treatment he suggested low-molecular weight heparin which should be suspended at INR higher than 3.

Two control scan examinations of the abdomen described a slightly lower retroperitoneal hematoma. A month later the dimension of hematoma was 143 × 70 × 78 mm. Because of altered state of consciousness and the present long-term sleep disorders, a neurologist was consulted and he suggested endocranial CT scan which showed notable degenerative changes with no pathological density and polysomnographic testing.

After applying the therapy, the patient was hemodynamically stabilized, The INR value was within the referent range, with satisfactory gas exchange. The patient was discharged after two months of hospital treatment in the Intensive Care Unit, with the advice to use anticoagulant therapy (low molecular weight heparin, nodroparin calcium 2 × 0.4 mL *sc*) because of the persistence of arrhythmia and due to hematoma transition, oral anticoagulants were delayed because of difficult dosing. Frequent monitoring of INR values was advised, to.

Discussion

Anticoagulant therapy such as warfarin, unfractionated heparin and low-molecular weight heparin are widely used in everyday practice in prevention and therapy of deep

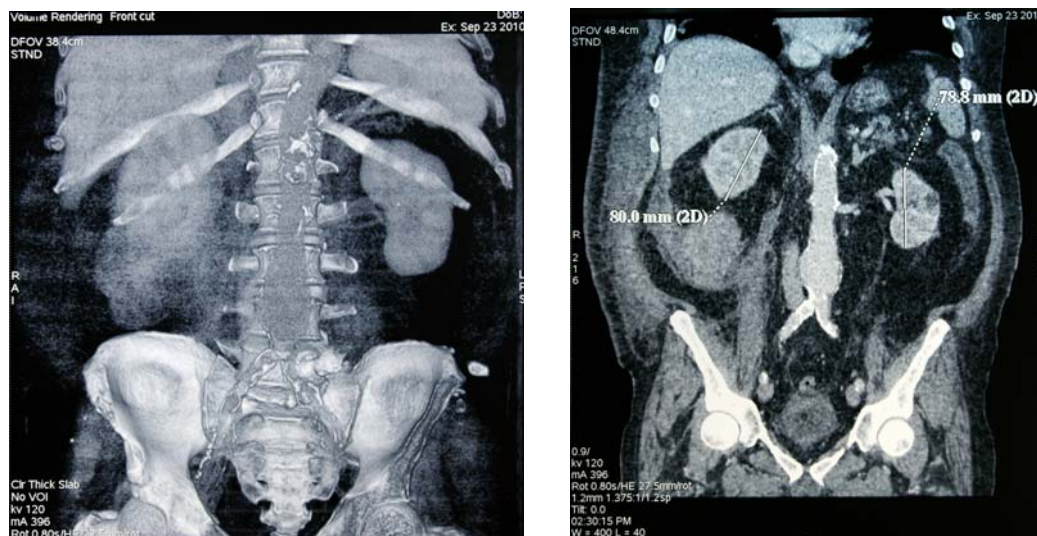


Fig. 2 – Computed tomography of the abdomen: retroperitoneal hematoma localized between the liver and the pelvis.

segment length 50 mm and wide 48 mm, with no signs of extravasation of blood (Figure 2).

Transfusion of concentrated red blood cells was performed twice with a satisfactory correction of hemoglobin level, and four units of fresh frozen plasma. After the consultation with the abdominal surgeon, he did not indicate surgical treatment. We also consulted the hematologist, who concluded that it was spontaneous hemorrhage as a complication of anticoagulant therapy in the application of standard dose

vein thrombosis, pulmonary embolism, acute ischemic stroke, valvular heart disease and atrial fibrillation. Bleeding is the most common complication, but literature recognizes many other complications like subcapsular renal hematoma, retroperitoneal and intraperitoneal hemorrhage, hemothorax, spinal epidural hematoma, gastrointestinal and cutaneous hematoma^{7, 8}.

An individual patient's risk for major anticoagulant-related bleeding can be estimated on the basis of specific risk factors

such as the intensity of the anticoagulant effect achieved and the presence of serious comorbid diseases, especially cerebrovascular, kidney, heart, and liver disease; older age and concurrent medicines may also be independent risk factors. The frequency of bleeding during warfarin therapy is reduced by less intense therapy achieving the prothrombin time with an INR of 2.0 to 3.0, which is efficacious for most indications⁹.

A large study of Sasson et al.¹⁰ showed that patients on anticoagulant therapy, even in therapeutic doses, should be monitored and checked regularly because of the possibility of complications of this therapy such as the development of spontaneous retroperitoneal hematoma. The most common symptoms are acute onset, persistent pain in the upper quadrant of the abdomen, in the groin or lumbal region with radiation to the scrotum. Pain and paresthesia are the result of pressure on the femoral nerve, the largest branch of the lumbal plexus.

We presented the patient who permanently used anticoagulant therapy. On the day of admission to our hospital he had the value of INR 5.57, so we immediately stopped this therapy. According to Naranjo et al.¹¹ adverse drug reaction probability scale, adverse event was definitely related to the drug.

The main symptom was the pain in the right inguinal canal radiating down the right leg, which is comparable to the clinical features of spontaneous retroperitoneal hematoma.

The diagnosis of spontaneous retroperitoneal hematoma is a challenge even on high-resolution CT or nuclear magnetic resonance, because many benign and malignant lesions can mimic this condition. CT is superior to ultrasound in localization, extension and evaluation of the size of hematoma.

Good limited and large-scale retroperitoneal hematoma was described on CT in our patient¹².

Treatment of spontaneous retroperitoneal hematoma includes surgery and conservative treatment of anemia and correction of warfarin-associated coagulopathy¹³. Conservative treatment depends on severity and location of hemorrhage and the INR when bleeding occurs. Warfarin therapy should be withheld in all patients with bleeding during oral anticoagulant therapy. Patients should be treated with coagulation

factor replacement and intravenous vitamin K¹⁴. Fresh frozen plasma provides rapid but partial reversal of coagulopathy providing replacement of coagulation factors II, VII IX and X. The usual dose of fresh frozen therapy is 15 mL/kg, although the optimal dose has not been established¹⁵.

Vitamin K reverses the action of warfarin partially or wholly depending on the route of administration and the dose used. The most effective way of treatment is intravenous administration of vitamin K. Usual dose is 2–5 mg. Reduction of INR begins within 2 hours, and correction to normal range is expected within 24 hours¹⁶.

Prothrombin complex concentrate depending on recommended doses ranges from 25 to 100 U/kg product used. Three-factor concentrates may not adequately correct the INR⁹.

Recombinant factor VIIa, in usual dose of 10 to 90 µg/kg, has immediate effect⁹.

A small hematoma with mild symptoms of neuropathy, without compression to surrounding structures and the need for transfusion and no signs of infection can be treated conservatively. On the other hand, surgical treatment is necessary when patients cannot be stabilized with conservative treatment, in unstable patients or due to constant compressive syndrome (femoral or ischiadic neuropathy)^{17,18}.

The presented patient was successfully treated with the application of fresh frozen plasma and blood transfusion.

Conclusion

Spontaneous retroperitoneal hematoma as a rare complication is still a diagnostic challenge even for experienced clinicians. Acute abdominal pain, paresthesia and laboratory signs of anemia in patients receiving oral anticoagulant therapy, should raise suspicion for intraabdominal bleeding. The early diagnosis is crucial because patients can be treated conservatively with good outcome. In patients who are on anticoagulant treatment it is extremely important to follow their status regularly, because of development of sometimes fatal complications such as spontaneous retroperitoneal hematoma

R E F E R E N C E S

1. Panetta T, Scalfani SJ, Goldstein AS, Phillips TF, Shafiq GW. Percutaneous transcatheter embolization for massive bleeding from pelvic fractures. *J Trauma* 1985; 25(11): 1021–9.
2. Danaci M, Kesici GE, Kesici H, Polat C, Belet U. Coumadin-induced renal and retroperitoneal hemorrhage. *Ren Fail* 2006; 28(2): 129–32.
3. Pallea EX, Domingo P, Fontcuberta J, Felez J. Spontaneous retroperitoneal haemorrhage during oral anticoagulant therapy. *Arch Intern Med* 1985; 145(8): 1531–4.
4. Hirsh J, Dalen JE, Anderson DR, Poller L, Bussey H, Ansell J, et al. Oral anticoagulants: mechanism of action, clinical effectiveness, and optimal therapeutic range. *Chest* 2001; 119: 8S–21S.
5. The European Atrial Fibrillation Trial Study Group. Optimal oral anticoagulant therapy in patients with nonrheumatic atrial fibrillation and recent cerebral ischemia. *N Engl J Med* 1995; 333: 5–10.
6. Hylek EM, Chang YC, Skates SJ, Hughes RA, Singer DE. Prospective study of outcomes of ambulatory patients with excessive Warfarin anticoagulation. *Arch Intern Med* 2000; 160(11): 1612–7.
7. Bali NC, Sirvanci M, Tüfek I, Onat L, Duran C. Spontaneous retroperitoneal hemorrhage secondary to subcapsular renal hematoma: MRI findings. *Magn Reson Imaging* 2001; 19(8): 1145–8.
8. Kirazlı Y, Akkoç Y, Kanyılmaz S. Spinal epidural hematoma associated with oral anticoagulation therapy. *Am J Phys Med Rehabil* 2004; 83(3): 220–3.
9. Crowther MA, Warkentin TE. Bleeding risk and the management of bleeding complications in patients undergoing anticoagulant therapy: focus on new anticoagulant agents. *Blood* 2008; 111(10): 4871–9.
10. Sasson Z, Mangat I, Peckham KA. Spontaneous iliopsoas hematoma in patients with unstable coronary syndromes receiving

- intravenous heparin in therapeutic doses. *Can J Cardiol* 1996; 12(5): 490–4.
11. *Naranjo CA, Busto U, Sellers EM, Sandor P, Ruiz I, Roberts EA, et al.* A method for estimating the probability of adverse drug reactions. *Clin Pharmacol Ther* 1981; 30(2): 239–45.
 12. *Pless T, Loertzer H, Brandt S, Radke J, Fornara P, Soukup J.* Atraumatic retroperitoneal hemorrhage: interdisciplinary and differential diagnostic considerations based on a case report. *Anaesthesial Reanim* 2003; 28(2): 50–3. (German)
 13. *Quartey B, Nelson J.* Massive spontaneous retroperitoneal hemorrhage induced by enoxaparin and subsequent abdominal compartment syndrome requiring surgical decompression: a case report and literature review. *IJCRI* 2011; 2(10): 14–8.
 14. *Dentali F, Cronther M.* Management of excessive anticoagulant effect due to vitamin K antagonists. *Hematology Am Soc Hematol Educ Program* 2008; 2008: 266–70.
 15. *Baglin T.* Management of warfarin (coumarin) overdose. *Blood Rev* 1998; 12(2): 91–8.
 16. *Lubetsky A, Yonath H, Olchovsky D, Loebstein R, Halkin H, Ezra D.* Comparison of oral vs intravenous phytonadione (vitamin K1) in patients with excessive anticoagulation: a prospective randomized controlled study. *Arch Intern Med* 2003; 163(20): 2469–73.
 17. *Ivascu FA, Janczyk RJ, Bair HA, Bendick PJ, Howells GA.* Spontaneous retroperitoneal hemorrhage. *Am J Surg* 2005; 189(3): 345–7.
 18. *Daliakopoulos SI, Bairaktaris A, Papadimitriou D, Pappas P.* Gigantic retroperitoneal hematoma as a complication of anticoagulation therapy with heparin in therapeutic doses: a case report. *J Med Case Rep* 2008; 2(1): 162.

Received on September 24, 2013.

Revised on April 17, 2014.

Accepted on June 9, 2014.

Online First March, 2015.