



## Diagnostic approach to localised organising pneumonia – A case report

### Dijagnostički pristup lokalizovanoj organizovanoj pneumoniji

Mirna Djurić, Djordje Považan, Dejan Djurić, Živka Eri, Anika Trudić

The Institute for Pulmonary Diseases of Vojvodina, Sremska Kamenica, Serbia

#### Abstract

**Introduction.** Localised organising pneumonia, radiologically presented with oval or round shadows mimicing lung cancer or metastases, is a major issue in differential diagnosis. **Case report.** A female patient was hospitalized to clarified the etiology of multiple nodular lung lesions. The chest X-ray and the chest computed tomography (CT) revealed bilateral patchy and nodular shadows, and round lung lesions, respectively. Neither sputum analyses, nor histology of bronchoscopy samples clarified the etiology of these lung lesions. As secondary deposits in the lungs were suspected, video-assisted thoracoscopy and anterolateral right minithoracotomy with atypical upper and lower lobe resection were performed. The frozen-section analysis suggested the benign nature of the lesion, and the definite histopathological finding of localised organising pneumonia was established. Due to bilateral lung lesions, corticosteroids were applied. Seven weeks later, the chest CT finding revealed a total regression of the lesions. **Conclusion.** A surgical resection was necessary to diagnose the localised organising pneumonia which mimiced secondary malignant lesions, thus establishing the definite etiology of lung lesions. Bronchoscopic cryobiopsy, recently introduced in order to obtain peripheral lung biopsy samples, has provided new possibilities in the diagnosis and treatment of neoplastic and non-neoplastic lung diseases.

#### Key words:

pneumonia; lung neoplasms; neoplasm metastasis; diagnosis; diagnosis differential; thoracic surgical procedures.

#### Apstrakt

**Uvod.** Lokalizovana organizovana pneumonija, predstavljena ovalnim ili okruglim senkama, zbog sumnje na karcinom bronha ili metastaze, čini diferencijalno dijagnostički problem. **Prikaz bolesnika.** Prikazana je bolesnica koja je hospitalizovana radi razjašnjenja etiologije multiplih nodularnih plućnih promena. Radiogram grudnog koša pokazao je obostrana mrljasta i nodularna zasenečenja, a kompjuterizovana tomografija obostrane okruglaste promene. Pregledi sputuma i patohistološke analize materijala uzetih tokom bronhoskopije nisu razjasnili etiologiju promena. Zbog sumnje na sekundarne depozite u plućima, urađena je videoasistirana torakoskopija i anterolateralna desna mini torakotomija sa atipičnom resekcijom gornjeg i donjeg režnja. *Ex tempore* nalaz ukazao je na benignost promene, a definitivni patohistološki nalaz na lokalizovanu organizovanu pneumoniju. Zbog obostranih plućnih promena primenjeni su kortikosteroidi. Nakon sedam nedelja nalaz kompjuterizovane tomografije ukazao je na potpunu regresiju promena. **Zaključak.** Hirurška resekcija bila je neophodna u dijagnostici lokalizovane organizovana pneumonija koja je ličila na sekundarne maligne lezije, a u cilju definitivnog razjašnjenja etiologije promena u plućima. Nedavnim uvođenjem bronhoskopske kriobiopsije biopata otvorene su nove mogućnosti u dijagnostici i terapiji neoplazmi i drugih bolesti pluća.

#### Ključne reči:

pneumonija; pluća, neoplazme; neoplazme, metastaze; dijagnoza; dijagnoza, diferencijalna; hirurgija, torakalna, procedure.

#### Introduction

Acute bacterial pneumonias respond to antibiotic therapy by regression and inflammatory process resolution. However, an intraalveolar fibrin exudate, or organising pneumonia (OP) may develop in some cases. OP is a unique histopathological entity which represents an unresolved or delayed slow-regression pneumonia occurring in 5–10% of all pneumonia cases<sup>1–4</sup>.

Depending on its inducing agent, three OP classes are differentiated: OP induced by a determined agent (bacteria, viruses,

parasites, fungi, drugs, irradiation), OP induced by an undetermined inducing agent or associated with other diseases, and OP of unknown origin (cryptogenic organising pneumonia – COP)<sup>1,2</sup>.

COP is the OP induced by an unknown agent with specific radiological and clinical signs. It usually occurs in 50–60 years old subjects, taking a subacute course and developing unspecific clinical symptoms (fever, cough, fatigue, dyspnea, anorexia, weight loss). The radiological finding is presented with multiple, bilateral, patchy, peripheral alveolar shadows, ground

glass or consolidation. More rarely, the radiological finding is presented with bilateral diffuse infiltrates and focal solitary lesions<sup>1,2,5</sup>. Focal COP is a rare entity, which may radiologically mimic malignant lung lesions and lung cancer. In most focal OP (FOP) cases, the diagnosis is established only after a surgical resection due to a suspected malignancy<sup>1,2,5</sup>. Tiny nodular shadows are more frequent, found in 10–50% of patients, while huge nodular lesions are rare<sup>6</sup>. The nodules may be around 8 mm in size and are defined as o (micro)nodules. Multiple OP nodules may suggest metastatic lesions<sup>1,2</sup>.

The diagnosis of COP is established on the basis of the histopathological OP finding, clinical and radiological characteristics, having excluded the known agents or comorbid conditions<sup>7</sup>. The sample for histopathology may be obtained by transbronchial biopsy (TBB), but video-assisted thoracoscopy (VATS) is not rarely indicated as the method providing a sufficient lung tissue sample<sup>1,2,5</sup>.

Recently, a new technique for bronchoscopic lung biopsy has been developed, using flexible cryoprobes<sup>8,9</sup>. In patients with diffuse lung diseases, transbronchial lung cryobiopsy (TBLC) is a safe procedure, less invasive than a surgical lung biopsy, providing large and well-preserved biopsy samples of the lung parenchyma, as compared to the standard forceps biopsy<sup>8–11</sup>. Constantly increasing the experience with bronchoscopic cryobiopsy, it has emerged to be the technique promising to become the first-line approach to lung biopsies in diagnosing diffuse lung diseases, enabling to avoid surgical lung biopsy<sup>8</sup>. The initial results of transbronchial cryobiopsy accompanied with endobronchial ultrasound (EBUS) in diagnosing peripheral lung lesions sizes < 4 cm show it is a feasible, safe and useful sampling technique which provides a larger sample than standard forceps biopsy<sup>12</sup>. Additional research is required to analyse and compare the cost-effectiveness of bronchoscopic cryobiopsy and surgical lung biopsy in the diagnosis of diffuse lung diseases and peripheral lung lesions<sup>8–10,12</sup>.

Pneumonias which do not regress, tending to organise instead, may resemble tumorous lesions. Focal pneumonic consolidations and focal malignant lesions may sometimes be radiologically presented as round or oval lesions. It is often difficult to differentiate between inflammatory and malignant nodules, and a surgical resection is the most reliable method to clarify their etiology<sup>4,13</sup>. Nevertheless, bronchoscopic cryobiopsy offers new diagnostic prospects.

The aim of this work was to present a female patient with the localised organising pneumonia (LOP) which radiologically resembled malignant lung lesions, in whom the histopathological dilemma was resolved by surgical resection.

### Case report

A 58-year-old female patient, a preschool teacher, was admitted to the Institute for Pulmonary Diseases of Vojvodina (IPDV), Sremska Kamenica, in November 2013, to clarify the etiology of multiple nodular lung lesions.

The patient went to the doctor because of fever (37.7°C) and dry cough, when she was submitted to chest X-ray, pre-

sented with bilateral merged patchy and nodular shadows (Figure 1). Computed tomography (CT) of the chest revealed the upper and lower lobes of both lungs predominantly involved by multiple, hyperdense lesions, patchy or roundish in shape, either isolated or merged, 9 mm in diameter, a few of which were localized in the subpleura (Figure 2).

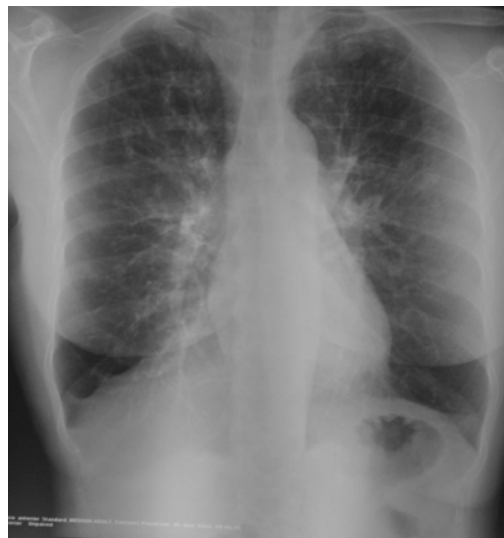

Fig. 1 – Chest X-ray on admission.

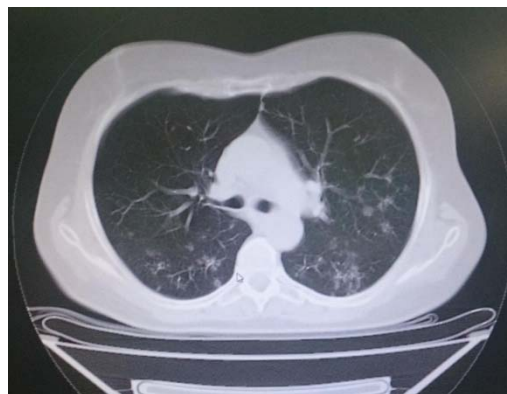

Fig. 2 – Chest computed tomography (CT) on admission

The patient was referred to the IPDV. On admission, the patient had no major respiratory symptoms, complaining of stabbing bellow the right rib arch. The patient was afebrile, eupneic, cardially compensated, normotensive, with no deviations registered on physical examination. Anamnestically, the patient reported a 20-year history of chronic bronchitis, stent implantation after the myocardial infarction six years ago, and long-term smoking.

Laboratory findings were: elevated erythrocyte sedimentation rate (66 mm/-), C reactive protein 6.9 mg/L and procalcitonine 0.08 ng/mL; blood cell count, fibrinogen and standard laboratory findings within reference values.

Lung function estimation revealed: moderate obstructive ventilation disorder, with moderate hyperinflation of the lungs (FVC 2.35–93.6%; FEV1 1.16–55%; ITGV 4.45–174.1%, Rt 0.28;). In acute test with a bronchodilator, the obstruction of the airways was partially reversible in character. Moderately decreased diffuse capacity (DLCO 3.88–54.1%) was registered. Gas analysis of the arterial blood



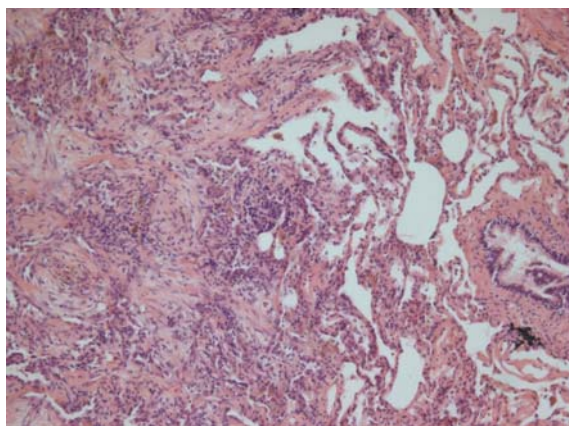
suggests mild hypoxemia (PaO<sub>2</sub> 9.09 kPa; PaCO<sub>2</sub> 4.89 kPa; pH 7.464; SaO<sub>2</sub> 94.4%). Echocardiography finding was normal (60% ejection fraction of the left ventricle).

The patient was submitted to bronchoscopy, providing a normal endoscopy finding. Histopathology of the obtained lung sample was negative.

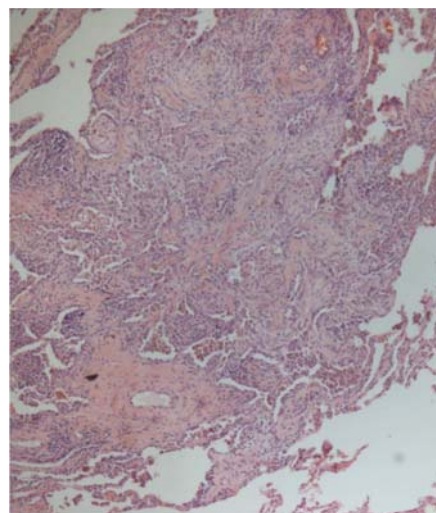
Sputum cytology revealed catarrhal exudate. No bacteriological growth was present. The sputum smear and culture, as well as catheter biopsy samples were negative to *Mycobacterium tuberculosis*.

Due to the radiological finding which might be suggestive of secondary lung deposits, ultrasound of the upper abdomen and the pelvis, colonoscopy, thyroid examination, mammography and gynecological examination were performed, providing normal findings.

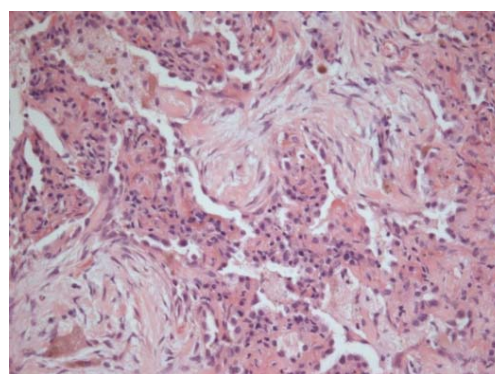
As the etiology of the lung lesions was not clarified, surgical diagnostics was indicated. Thoracotomy-inducing video-assisted thoracoscopy of the right lung was performed (having approached the pleural cavity, the exploration verified smooth and bright pleura free of carcinosis) at the Chest Surgery Clinic of the Institute. The right anterolateral mini thoracotomy was performed, and the exploration verified a few nodular lesions in the upper and lower right lung lobes. An atypical resection of the upper and lower lobe was performed, and the frozen section assay suggested a benign nature of the lesion. The material sent for histopathology included three lung edge samples sized 7 × 2 × 1 cm, 5.5 × 1.5 × 1 cm and 4 × 2 × 0.5 cm, presented with a tiny greyish capsule enclosing tumorous lesions sized 1 × 1 cm. On cross-section, they were relatively clearly defined, pinkish grey or light yellowish in colour, firm, with a relatively preserved pulmonary parenchyma between them. Histologically, the lung architecture was typically preserved (Figure 3). The nodular character of the lesion was well seen even at a low magnification (Figure 4). The terminal lumen of airways the neighbouring alveoli were involved with numerous buds of multiplied edematous loose granulation tissue (Figure 5). The interstitium was involved with infiltrates of lymphocytes, plasma cells and histiocytes in different quantities. Some alveoli were coated with atypical cuboid alveolar cells, and filled with alveolar macrophages (Figure 6). The definite histopathological finding was: localised organising pneumonia.



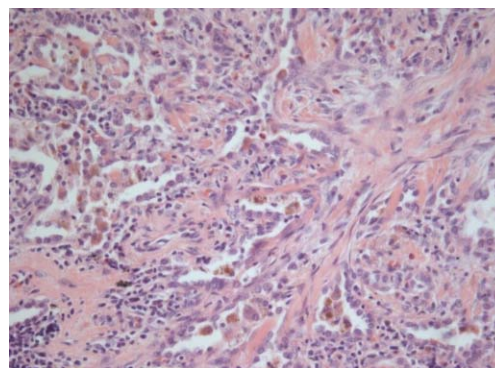
**Fig. 3 – Preserved lung structure (HE, ×200).**



**Fig. 4 – Nodular nature of the process at low magnification (HE, ×200).**



**Fig. 5 – Terminal airways and adjacent alveoli filled with loose granulation tissue (HE, ×400).**



**Fig. 6 – Fibrosis and interstitial inflammation with alveolar hyperplasia. Massive accumulation of alveolar macrophages (HE, ×400).**

During the hospital stay, the patient was receiving the inhalant desopstruction therapy and antihypertensives, and as soon as the diagnosis of organising pneumonia had been established, corticosteroids (prednisolon 0.75 mg/kg/day) were introduced, accompanied with a gastroprotective drug. The patient was discharged in a good general condition, instructed to gradually reduce the prescribed corticotreatment.

Seven weeks later, the patient was feeling well. The inflammation markers were normal, as well as the chest X-ray finding (Figure 7). The control CT of the chest revealed a to-

tal regression of the lesions in both lungs (formerly described lesions sized  $\leq 9$  mm in different segments of both lungs). Some sites of former lesions were now involved with striped pleuropulmonary sequels, and the sites of performed typical resections S1 and S10 with scar lesions. Vesiculous pulmonary emphysema persisted. No enlarged mediastinal or axillary lymph nodes were registered, nor uni- or bilateral pleural effusion signs (Figure 8).

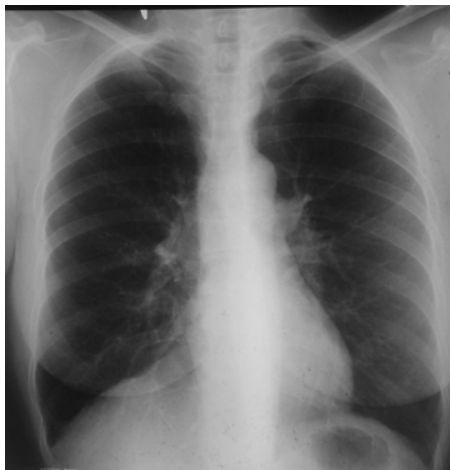

Fig. 7 – Control chest X-ray.

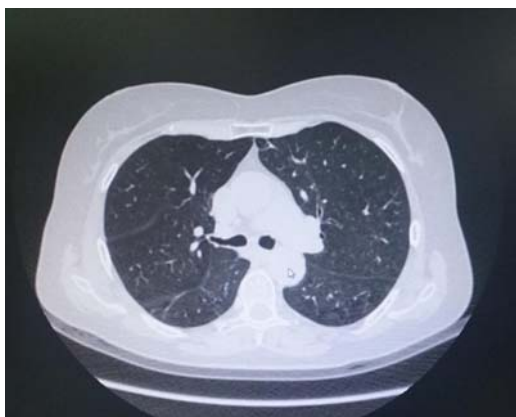

Fig. 8 – Control computed tomography (CT) of the chest.

### Discussion

As OP is a localised process presented with oval or round shadows mimicking lung cancer or metastases, it is a major issue in differential diagnosis, investigated by many authors<sup>13</sup>.

If chest CT in OP is characterized with focal lesions they are hardly differentiated from malignant ones, requiring bronchoscopy sampling of the lungs. In case it fails to clarify the etiology of lung lesions, a surgical resection (VATS, thoracotomy) is needed<sup>14-16</sup>. There exist no specific clinical and radiological features enabling a reliable differentiation between focal OP and lung cancer, and therefore a surgical resection cannot be avoided in some cases. Zheng et al.<sup>17</sup> have come to a similar conclusion in his study of 20 FOP patients compared to 40 patients with lung cancer.

In the presented case, bronchoscopy with standard lung biopsy sampling failed to clarify the etiology of lung lesions. The experience in applying TBLC to diagnose diffuse parenchymal

lung disease shows the following: the technique provides a larger tissue sample than the standard transbronchial forceps biopsy; the diagnosis is established in a large percentage of cases; intervention is safe in regard to pneumothorax and bleeding, and a surgical diagnosis is required in 5–12% of the cases<sup>8-10</sup>. Cryobiopsy samples are larger, with no artefacts, containing alveolar tissue more often. Cryobiopsy can therefore be said to have a diagnostic perspective<sup>11</sup>. The results of applying transbronchial cryobiopsy in diagnosing peripheral lung lesions also confirm it as safe and useful technique<sup>12</sup>. Still, additional, large-scale investigations are also needed.

In our patient, thoracotomy-introducing VATS was performed, succeeded by the atypical resection, correlating to other authors' reports: of 27 patients, 14 had wedge resection, and 13 lobectomy with or without VATS<sup>13</sup>; of 21 patients, wedge resection was performed in 16, and lobectomy in 5; wedge resection was therefore performed in 81%, segmentectomy in 11%, and lobectomy in 8% of the patients<sup>17</sup>. In our patient, the lesions were localized below the visceral pleura, the largest one over 2 cm away from the visceral pleura, in the right upper lobe. Close to this lesion, there was another, smaller one, which was extirpated. Due to the accidental mistake possible in randomly selecting the multiple lesions, the third lesion was also extirpated from the right lower lobe, thus reducing the accidental mistake to the minimum.

Many authors emphasize the role of surgical diagnostic procedures in clarifying the etiology of peripheral lung lesions. Wu et al.<sup>13</sup> applied surgical resection of tumorous lesion in patients thoracotomized due to undiagnosed peripheral focal lung lesions suspected for malignancy, establishing OP. Their etiology would not have been clarified if surgical resection had not been applied. As lung cancer was suspected due to unifocal shadowing unclarified by bronchoscopy, surgical resection was indicated, clarifying the diagnostic dilemmas of these cases and establishing the diagnosis of FOP<sup>17</sup>. Due to the suspected malignant nature of our patient's lesions presented with 9–10 mm nodules, surgical resection was also indicated, correlating to the reports of Yang et al.<sup>3</sup> who analysed the patients with FOP submitted to thoracotomy due to 9–60 mm sized nodules, mimicking lung cancer on CT.

Corticosteroid treatment is a standard for OP. In our patient, it resulted in a radiological regression of bilateral lung lesions. Bronchoscopy confirmed FOP is treated by corticotherapy, resulting in elimination of the symptoms and radiological regression<sup>5</sup>. In a study on LOP, patients with bilateral lesions were operated to establish the diagnosis, and due to bilateral lesions they were prescribed for corticotherapy which improved their condition, correlating to our reported case. Resected solitary lesions require no additional corticotherapy, unlike bilateral localized OP lesions<sup>16</sup>.

When COP is treated with corticosteroids, it has good prognosis, while the prognosis of secondary OP is less certain and depends on the underlying disease, as reported by many authors<sup>18,19</sup>.

As there exist no specific clinical and radiological features to enable a reliable differentiation between FOP and lung cancer or metastases, surgical resection is the method of choice to either establish or abandon malignancy in problematic cases.

## Conclusion

Surgical resection is necessary in the diagnosis of localised organising pneumonia mimicking lung cancer or metastases, in

order to clarify the etiology of these lesions. Bronchoscopic cryobiopsy, recently introduced in order to obtain peripheral lung biopsy samples, has provided new possibilities in diagnosis and treatment of neoplastic and non-neoplastic lung diseases.

## R E F E R E N C E S

1. *Cordier JF*. Organising pneumonia. *Thorax* 2000; 55(4): 318–28.
2. *Cordier JF*. Cryptogenic organising pneumonia. *Eur Respir J* 2006; 28(2): 422–46.
3. *Yang PS, Lee KS, Han J, Kim EA, Kim TS, Choo IW*. Focal organizing pneumonia: CT and pathologic findings. *J Korean Med Sci* 2001; 16(5): 573–8.
4. *Furuya K, Yasumori K, Takeo S, Sakino I, Uesugi N, Momosaki S, Muranaka T*. Lung CT: Part 1, Mimickers of lung cancer--spectrum of CT findings with pathologic correlation. *AJR Am J Roentgenol* 2012; 199(4): W454–63.
5. *Alikhan M, Veeraghavan S*. Empiric Treatment of Focal Organizing Pneumonia in a Patient with a Low - Risk Lung Mass. *Case Rep Pulmonol* 2013; 2013: 340202.
6. *Kevin OL, Mark RW*. Practical Pulmonary Pathology A diagnostic approach. 2nd ed. St. Louis, Mo: Elsevier Saunders; 2005.
7. *Travis WD, Costabel U, Hansell DM, King TE, Lynch DA, Nicholson AG, et al*. An official American Thoracic Society/European Respiratory Society statement: Update of the international multidisciplinary classification of the idiopathic interstitial pneumonias. *Am J Respir Crit Care Med* 2013; 188(6): 733–48.
8. *Kropski JA, Pritchett JM, Mason WR, Sinarajan L, Gleaves LA, Johnson JE, et al*. Bronchoscopic cryobiopsy for the diagnosis of diffuse parenchymal lung disease. *PLoS One* 2013; 8(11): e78674.
9. *Babiak A, Hetzel J, Krishna G, Fritz P, Moeller P, Balli T, et al*. Transbronchial cryobiopsy: a new tool for lung biopsies. *Respiration* 2009; 78(2): 203–8.
10. *Casoni GL, Tomassetti S, Cavazza A, Colby TV, Dubini A, Ryu JH, et al*. Transbronchial lung cryobiopsy in the diagnosis of fibrotic interstitial lung diseases. *PLoS ONE* 2014; 9(2): e86716.
11. *Griff S, Ammenwerth W, Schonfeld N, Bauer TT, Mairinger T, Blum TG et al*. Morphometrical analysis of transbronchial cryobiopsies. *Diagn Pathol* 2011; 6: 53.
12. *Schubmann M, Bostanci K, Bugalbo A, Warth A, Schnabel PA, Herth FJ, et al*. Endobronchial ultrasound-guided cryobiopsies in peripheral pulmonary lesions: a feasibility study. *Eur Respir J* 2014; 43(1): 233–9.
13. *Wu CT, Chang YL, Chen WC, Lee YC*. Surgical treatment of organising pneumonia mimicking lung cancer: experience of 27 patients. *Eur J Cardiothorac Surg* 2010; 37(4): 797–801.
14. *Maldonado F, Daniels CE, Hoffman EA, Yi ES, Ryu JH*. Focal organizing pneumonia on surgical lung biopsy: causes, clinico-radiologic features, and outcomes. *Chest* 2007; 132(5): 1579–83.
15. *Melloni G, Cremona G, Bandiera A, Arrigoni G, Rizzo N, Varagona R, et al*. Localized organizing pneumonia: report of 21 cases. *Ann Thorac Surg* 2007; 83(6): 1946–51.
16. *Maldonado F, Daniels CE, Hoffman EA, Yi ES, Ryu JH*. Focal organizing pneumonia on surgical lung biopsy: causes, clinico-radiologic features, and outcomes. *Chest* 2007; 132(5): 1579–83.
17. *Zheng Z, Pan Y, Song C, Wei H, Wu S, Wei X, et al*. Focal organizing pneumonia mimicking lung cancer: a surgeon's view. *Am Surg* 2012; 78(1): 133–7.
18. *Drakopanagiotakis F, Polychronopoulos V, Judson MA*. Organizing pneumonia. *Am J Med Sci* 2008; 335(1): 34–9.
19. *Yoo J, Song JW, Jang SJ, Lee CK, Kim M, Lee H, et al*. Comparison between cryptogenic organizing pneumonia and connective tissue disease-related organizing pneumonia. *Rheumatology* 2011; 50(5): 932-8.

Received on February 20, 2014.

Revised on May 15, 2014.

Accepted on July 2, 2014.

Online First July, 2015.