



A clinical study on the influence of suturing material on oral wound healing

Klinička studija o uticaju materijala za šivenje na zarastanje oralne rane

Dragan Gazivoda*[†], Dejan Pelemiš*, Goran Vujašković[‡]

*Clinic of Oral Surgery, Military Medical Academy, Belgrade, Serbia; [†]Faculty of Medicine of the Military Medical Academy, University of Defence, Belgrade, Serbia;

[‡]Faculty of Dentistry, University of Belgrade, Belgrade, Serbia

Abstract

Background/Aim. Suture materials play an important role in healing, enabling reconstruction and reassembly of tissue separated by the surgical procedure or trauma, and at the same time facilitating and promoting healing and hemostasis. Suture materials are used daily in oral surgery, and are considered to be substances most commonly implanted in human body. The aim of this clinical study was to examine the speed of wound healing and complications incidence, after the use of three different absorbable synthetic suture materials in oral surgery (catgut, Dexon and Vicryl rapide), and to ascertain which one is the most suitable for oral surgery. **Methods.** The study was conducted on 96 patients undergoing root resection or surgical extraction of third molars. Each of the suture materials (catgut, Dexon and Vicryl rapide) was used for 8 root resections and 8 surgical third molar extractions in the maxilla, as well as in the mandible (a total of 32 surgical interventions for each suture material). **Results.** The faster wound healing was obtained with Vicryl rapide compared to other two suturing material tested. There was no significant difference regarding the presence of local reaction in all the three groups of patients on the 21st postoperative day. **Conclusion.** The results of our clinical study point out that Vicryl-rapide contributes more than catgut or Dexon to faster healing of human wounds, with fewer incidences of wound dehiscence and milder local reactions.

Key words:

oral surgical procedures; sutures; treatment outcome.

Apstrakt

Uvod/Cilj. Materijali za šivenje igraju važnu ulogu u zarastanju rane, omogućavajući rekonstrukciju i vraćanje razdvojenog tkiva tokom hirurške procedure ili traume, i u isto vreme omogućavaju i pospešuju zarastanje i hemostazu. Materijali za šavove svakodnevno se koriste u oralnoj hirurgiji i smatraju se supstancama koje se najčešće implantiraju u ljudsko telo. Cilj ove kliničke studije je da se ispita brzina zarastanja rana, učestalosti komplikacija nakon primene tri različita resorptivna sintetička materijala za šivenje u oralnoj hirurgiji (catgut, Dexon i Vicryl rapide), i da se utvrdi koji je od njih najpogodniji za upotrebu u oralnoj hirurgiji. **Metode.** Studija je sprovedena na uzorku od 96 pacijenata kod kojih je urađena resekcija korena i hirurška ekstrakcija trećih molara. Svaki od materijala za šavove (catgut, Dexon i Vicryl rapide) upotrebljen je prilikom osam resekcija korena i osam hirurških ekstrakcija trećih molara u maksili i mandibuli (ukupno 32 intervencije za svaki materijal za šavove). **Rezultati.** Ustanovljeno je brže zarastanje rana uz primenu Vicryl rapide materijala za šavove u odnosu na druga dva testirana materijala. Nije ustanovljena značajna razlika u prisustvu lokalne reakcije kod sve tri grupe bolesnika 21. postoperativnog dana. **Zaključak.** Rezultati kliničke studije ukazuju na veći doprinos bržem zarastanju rane uz primenu Vicryl rapide materijala u odnosu na catgut i Dexon, sa nekoliko slučajeva dehiscencije rane i ispoljavanjem blaže lokalne reakcije.

Ključne reči:

hirurgija, oralna, procedure; šavovi; lečenje, ishod.

Introduction

Suture materials play an important role in healing of wounds, enabling reconstruction and reassembly of tissue separated by a surgical procedure or a trauma, and at the same time facilitating and promoting healing and hemostasis¹. Suture ma-

terials are used daily in oral surgery, and are considered to be substances most commonly implanted in human body.

Usage of suture materials dates back to ancient Egypt, but significant development occurred in the 1960s and the early 1970s, when greatest innovations of synthetic sutures made of polyvinyl alcohol were introduced^{2,3}.

Suture materials are classified on the basis of several criteria, and these are usually origin, structure, and biological properties⁴. By origin, sutures can be natural and synthetic; by structure they can be monofilament and multifilament, while by biological properties they can be absorbable and non-absorbable.

Development of synthetic suture materials introduced a few suture materials of different characteristics, good quality and acceptable price³. However, ideal suture material has not been manufactured yet.

Important features of absorbable suture materials are their way of absorption and loss of tensile strength over time. Both are very important for ascertaining whether the used absorbable suture material will stay intact long enough and ensure enough strength to facilitate and promote wound healing. Superficial wound tissue usually takes five to ten days to heal, but some surgical procedures require sutures to persist 14 to 28 days⁵. However, as absorbable suture materials are dissolved under the influence of proteolytic enzymes or hydrolysis, it would be preferable not to have them remain in tissue longer than necessary.

Ideal suture material should have certain physical characteristics and properties, such as resistance to traction, dimension stability, absence of memory, knot safety and flexibility sufficient to avoid damaging oral mucosa. Furthermore, ideal suture material needs to provide limited bacterial adhesion and wound contamination. Given that no ideal suture material has been manufactured yet, sutures themselves can become the source of inflammation, which may reduce or compromise the potential for reparation and regeneration. Only a few references compare or discuss properties and quality of absorbable suture materials⁶⁻⁹.

Sutures used in oral and maxillofacial surgery behave differently from those used for other parts of the body due to differences in the quality of tissue involved, constant presence of saliva, high level of vascularisation and the presence of functions of speech, chewing and swallowing.

Oral surgery interventions are customarily finished by suturing surgical wound¹⁰, and the choice of the most appropriate suture material depends on the site and depth of tissue to stitch. Given that this type of intervention includes suturing overlying tissue, non-absorbable materials (usually silk sutures) are routinely used, which are then removed 5–7 days postoperatively.

Sometimes, however, when it is not possible to remove the placed sutures, absorbable materials are used: in case of persons with disability, not able to cooperate, given that removing sutures would imply induction of general anaesthesia; children and soldiers positioned in remote units, without adequate conditions for revisiting and removing sutures, especially in case of emergency and in wartime¹¹.

There is lack of information on behaviour of these materials in oral cavity. Oral environment is characterized by numerous specificities, primarily presence of saliva¹⁰⁻¹³, which is of variable amount, pH and contents of immunoglobulins. Besides the presence of saliva, oral cavity is characterised by: local immunogenic response, presence of saprophyte bacteria that can manifest pathogenic effects in some circumstances, accumulation of plaque on the surface

of suture material (especially on knots), capillary effect and subsequent absorption of fluid by material^{14,15}.

The aim of this clinical study was to examine the speed of wound healing and complications incidence, after the use of three different absorbable synthetic suture materials in oral surgery [catgut, polyglycolic acid (Dexon) and polyglactin 910 (Vicryl rapide)], and to ascertain which one is the most suitable for oral surgery.

Methods

The study was conducted on 96 patients undergoing root resection or surgical extraction of third molars. The patients were chosen randomly, paying attention to equal distribution of interventions in both upper and lower jaw (medical indication was the only criterion for choice, not sex, age or general health condition). Therefore, each of the suture materials (catgut, Dexon and Vicryl rapide) was used for 8 root resections and 8 surgical third molar extractions in the maxilla, as well as in the mandible (total of 32 surgical interventions for each suture material).

With the aim of unification of healing conditions, the same incisions were used (R ein-M uler and Novak-Peter for root resection and standard edge cut with relaxation for surgical extractions of impacted third molars). In the postoperative period, patients were followed-up on the days 1, 3, 7, 14 and 21. The following indicators of wound healing efficiency were monitored: a) incidence of wound dehiscence (postoperative days 1, 3 and 7); b) occurrence of local tissue reaction (postoperative days 1, 7, 14 and 21).

In the postoperative period, all the patients were monitored, in specified intervals, for the presence (absence) and incidence of the following side effects: edema, hematoma, infection, as well as administration of analgesic or antibiotics.

Changes of protruding for more than 1 cm relative to the opposite side were registered as edema, and changes of mucosa color to purple were considered as hematoma. Particular attention was paid to the presence of dehiscence and local reaction (redness of the mucosa, edema, inflammation) for all the three types of suture materials.

The results are presented in tables and figures, and χ^2 test was used for determining differences in the incidence of particular change. All indicators had frequency distribution identified, with frequency differences determined with chi-square test. Differences were accepted as statistically significant if *p*-value was 0.05 or less.

Results

Our study was finalized by summing up the obtained results regarding the registered manifestations: dehiscence and local reactions in the postoperative period, as well as an incidence of postoperative complications, such as edema, hematoma and infections.

On the 1st postoperative day, dehiscence was registered in two patients (6.2%) with catgut applied, and not registered in the patients with Dexon or Vicryl rapide applied. By comparing all the 3 groups on the 1st postoperative day, it is ap-

parent that this difference was not significant (Table 1). On the 3rd postoperative day, dehiscence was registered more frequently, and it was statistically significant when comparing catgut and Vicryl rapide (Table 1). On the 7th postoperative day, Dexon was associated with dehiscence in 10 patients, catgut in 16 patients, and Vicryl-rapide in 6 patients, which was statistically significant (Table 1).

On the postoperative day 1, the presence of some mild local reaction (mostly just redness of the mucosa and slight edema) was registered in more than 50% of the patients. Comparison of all the 3 groups on the postoperative day 1 revealed no significant difference (Table 2). On the postoperative day 7, the presence of local reaction was still registered in approximately 50% of the patients. However, comparison of the results showed a significant difference in favor of Vicryl rapide when compared to the other two materials (Table 2). On the postoperative day 14, the presence of local reaction was registered in only 3 (9.3%) of the patients with

Discussion

There are not many references comparing or discussing properties and quality of absorbable suture materials^{6-9, 16}. Many authors compare non-absorbable and absorbable sutures; however, just a few of them define properties of suture materials used in oral cavity. Given that there is no ideal suture material, it is necessary to conduct large number of studies that would help clinicians to consider all characteristics of suture materials, with the emphasis on biological properties and their applicability in oral cavity. Oral cavity is a specific environment relative to other human tissues, due to the presence of saliva and specific microorganisms, strong vascularisation, as well as associated functions of speech, chewing and swallowing.

On the basis of their comparative study, Filho et al.¹⁷ concluded that polyglactin 910 is one that is preferred in dentistry. It has proved to be clinically excellent because it does

Table 1

Suture materials	Postoperative day		
	1	3	7
Dexon	0	6	13
Catgut	1	9	8
Vicryl rapide	0	3	5

Table 2

Suture materials	Postoperative day			
	1	7	14	21
Dexon	17	16	3	0
Catgut	20	17	3	1
Vicryl rapide	17	4	0	0

applied catgut and Dexon. The patients treated with Vicryl rapide had no local reaction. There was no significant difference when comparing all the 3 groups on the day 14. There was no significant difference regarding the presence of local reaction on the postoperative day 21 also (Table 2).

Fluctuation of local reactions during the postoperative period is presented in Figure 1, and mean values of local reactions for the entire postoperative period are presented in Figure 2.

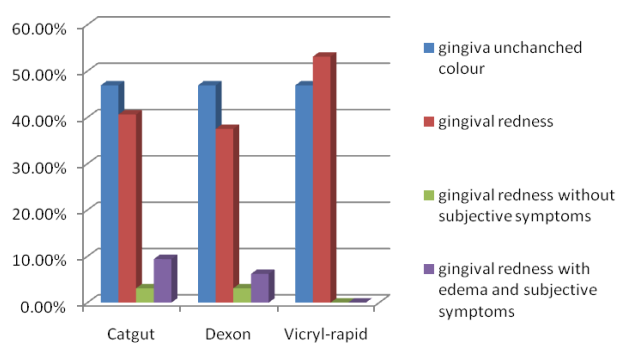


Fig. 1 – Local tissue reactions after suturing with the tested suture materials.

not allow adherence of plaque and is well suited for handling. In addition, it shows no intensive local reaction. It is excellent clinically because it does not allow plaque adherence, being coated with Ca-stearate, which enables easy and efficient passing through tissue with minimum resistance^{16, 17}. Our experiences with Vicryl are positive and agreeable with these. A shortcoming of Vicryl rapide could be a possibility of knots loosening (because it is coated). However, this deficiency may be overcome by tying more knots³⁻⁵.

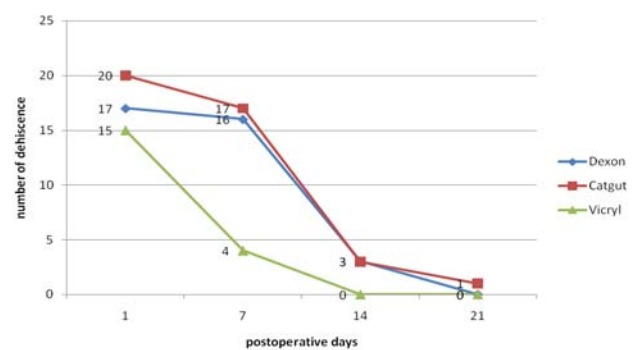


Fig. 2 – Local reaction in the postoperative period after the use of the tested suture materials.

Duprez et al.¹⁸ conducted a clinical research including surgical procedures on children's hips. Breaking of suture material was registered after 12 to 16 days. Absorption mechanism includes hydrolysis. Inflammatory reaction was obvious, with abundant macrophages containing suture material fragments. It is also possible that inflammation cells release lytic enzymes, which increase spontaneous lysis and lead to fragmentation of suture material. These authors found Vicryl-rapide to be perfect, tolerant and breaking after 12 to 16 days, with moderately present reaction of macrophages.

The objective of our study was to examine clinical characteristics of the 3 most commonly used absorbable suture materials (catgut, Dexon and Vicryl rapide). References suggested that inflammatory tissue reaction is strongest with catgut. Our research results showed the highest level of inflammatory response in the observation period – on the postoperative days 3, 7, 14 and 21 – with Dexon, then with catgut, and the lowest with Vicryl rapide.

Shaw et al.¹⁹ conducted a prospective study in which patients with oral surgery reported by mail the moment when absorbable stitches disappeared from their mouth. A study of this type is interesting, but not very significant, given that patients gave personal subjective perception of the moment of suture absorption, which did not necessarily need to be authentic.

Search for ideal suture material does not imply only biological compatibility, but also good clinical behaviour – resistance to traction, dimensional stability, low memory effect, good knot security and good flexibility with mild capillary effect²⁰.

Wallace et al.²¹ compared polyglycolic acid, silk, chromic and flat catgut used on 52 respondents. Tissue reaction was studied and classified clinically and histologically on the days 3, 5, 7 and 14 after oral surgical intervention. Polyglycolic acid stitch (Dexon) caused the mildest tissue reaction, milder than silk, chromic and flat catgut. Besides suggesting easier stitching with Dexon than with silk, they said that Dexon stayed present in tissue after implanting for 16–20 days; catgut was absorbed in 3–5 days, and chromic in 7–10 days. According to these authors, Dexon seems to have properties closer to ideal suture material than any other tested.

Besides being conditioned by the degree of local reaction, time of absorption of suture material is also conditioned by the

quantity of present electrolytes, as well as by basal metabolism. The only logical explanation for misbalance in absorption time of Dexon lies in the fact that Wallace et al.²¹ equals disappearing of knot from oral cavity with absorption, which does not necessarily imply the moment of complete absorption of suture material, since it can be registered only with histopathological examination, which was not indicated as the method used in that study.

Our study confirms that Vicryl rapide provokes mildest local reaction, while most severe local reaction is not caused by catgut, but by Dexon, which differs from most other study results and manufacturers' information. It is also confirmed that Vicryl rapide contributes to faster healing of wounds in humans, with the lower incidence of dehiscence and milder local reactions than with applied catgut or Dexon. Besides these manifestations, it is important that intensity of local reaction stays as mild as possible (low antigenic potential), with the least possible wound dehiscence. Statistically significant difference regarding the incidence of dehiscence on the postoperative day 3 was visible when catgut and Vicryl rapide were compared, being more rare with application of Vicryl rapide. Occurrence of local reaction on the postoperative day 7 presented statistically significant difference when comparing catgut and Vicryl-rapide and Dexon and Vicryl rapide.

In oral surgery, sutures are usually removed 7–10 days upon implanting, when differences between materials do not seem to be very significant. However, some patients who do not cooperate and do not have sutures removed may benefit from using absorbable sutures with best characteristics. Moreover, histopathological examination, a part of our experimental study already performed¹¹, confirmed that Vicryl rapide has the best results, again approving the results of this clinical study.

Conclusion

It seems that Vicryl rapide has the best properties of the available absorbable suture materials for application in oral surgery.

The results of our clinical study point out that Vicryl rapide contributes more than catgut or Dexon to faster healing of human wounds, with fewer incidences of wound dehiscence and milder local reactions.

R E F E R E N C E S

1. Banche G, Roana J, Mandras N, Amasio M, Gallesio C, Allizond V, et al. Microbial adherence on various intraoral suture materials in patients undergoing dental surgery. *J Oral Maxillofac Surg* 2007; 65(8): 1503–7.
2. Kostić I. Impact of suture material and suture techniques on healing of tracheal anastomoses. Niš: Faculty of Medicine, University of Niš; 1989. (Serbian)
3. Sortino F, Lombardo C, Sciaccia A. Silk and polyglycolic acid in oral surgery: a comparative study. *Oral Surg Oral Med Oral Pathol Oral Radiol Endod* 2008; 105(3): 15–8.
4. Çapanoğlu D. Sutures, 1999-2000, Spring Term. [cited 2007. September 9]. Available from: <http://www.biometu.edu.tr/biomed/sutures.htm>
5. O'Neal RB, Allyn CD. Suture materials and techniques. *Curr Opin Periodontol* 1997; 4: 89–95.
6. Stone IK, von Fraunhofer JA, Masterson BJ. A comparative study of suture materials: chromic gut and chromic gut treated with glycerin. *Am J Obstet Gynecol* 1985; 151(8): 1087–93.
7. Stone IK. Suture materials. *Clin Obstet Gynecol* 1988; 31(3): 712–7.
8. Ravey GL, Wallace WR, Cavalaris CJ, Marquard JV. Comparison of a polyglycolic-poly-lactic acid suture to black silk and plain catgut in human oral tissues. *J Oral Surg* 1978; 36(10): 776–70.
9. Gnyuron B, Vaughan C. A comparison of absorbable and non-absorbable suture materials for skin repair. *Plast Reconstr Surg* 1992; 89(2): 234–6.

10. Peterson L, Ellis E, Hupp JR, Tucker MR. Contemporary Oral and Maxillofacial Surgery. 3rd ed. St Louis, Mo: Mosby Year-Book; 1998.
11. Gazivoda D, Pelemiš D, Vujašković G. Influence of the suturing material on a wound healing - experimental study in dogs. *Vojnosanit Pregl* 2015; 72(5): 397–404.
12. Aderriotis D, Sándor GK. Outcomes of irradiated polyglactin 910 Vicryl Rapide fast-absorbing suture in oral and scalp wounds. *J Can Dent Assoc* 1999; 65(6): 345–7.
13. Mirković S. Impact of suture material on wound healing following mucoperiosteal incision. Novi Sad: Faculty of Dentistry, University of Novi Sad; 2000. (Serbian)
14. Greene JC, Vermillion JR. The simplified oral hygiene index. *J Am Dent Assoc* 1964; 68: 7–13.
15. Löe H. The Gingival Index, the Plaque Index and the Retention Index Systems. *J Periodontol* 1967; 38: 610–6.
16. Nary FH, Matsumoto MA, Batista AC, Lopes LC, de Góes FC, Consolaro A. Comparative study of tissue response to polyglactone 25, polyglactin 910 and polytetrafluorethylene suture materials in rats. *Braz Dent J* 2002; 13(2): 86–91.
17. Filbo NH, Okamoto T, Padovan LE. Estudo comparativo da resposta tecidual frente a fios de sutura de catgut e poliglecaprone 25 em subcutâneo de ratos. *Salusvita* 1996; 15(1): 127–42.
18. Duprez K, Bilweis J, Duprez A, Merle M. Experimental and clinical study of fast absorption cutaneous suture material. *Ann Chir Main* 1988; 7(1): 91–6.
19. Shaw RJ, Negus TW, Mellor TK. A prospective clinical evaluation of the longevity of resorbable sutures in oral mucosa. *Br J Oral Maxillofac Surg* 1996; 34(3): 252–4.
20. Certosimo FJ, Nicoll BK, Nelson RR, Wolfgang M. Wound healing and repair: a review of the art and science. *Gen Dent* 1998; 46(4): 362–9.
21. Wallace WR, Maxwell GR, Cavalari CJ. Comparison of polyglycolic acid to black silk, chromic, and plain catgut in human oral tissues. *J Oral Surgery* 1970; 28(10): 739–16.

Received on April 1, 2014.

Revised on July 14, 2014.

Accepted on July 23, 2014.

Online First July, 2015.