



## Unrecognised adrenergic symptoms and the delayed diagnosis of urinary bladder paraganglioma

Kasna dijagnoza paraganglioma mokraćne bešike zbog neubedljivih adrenergičkih simptoma

Tamara Dragović<sup>\*†</sup>, Dejan Marinković<sup>\*</sup>, Snežana Kuzmić-Janković<sup>\*</sup>, Rade Prelević<sup>‡</sup>, Novak Milović<sup>†‡</sup>, Božidar Kovačević<sup>§</sup>, Zoran Hajduković<sup>\*†</sup>

<sup>\*</sup>Clinic for Endocrinology, <sup>‡</sup>Clinic for Urology, <sup>§</sup>Institute of Pathology, Military Medical Academy, Belgrade, Serbia; <sup>†</sup>Faculty of Medicine of the Military Medical Academy, University of Defence, Belgrade, Serbia

### Abstract

**Introduction.** Paraganglioma is a rare neuroendocrine neoplasm that may arise from the extra-adrenal autonomic paraganglia. Urinary bladder paraganglioma is typically presented as repeated episodes of palpitations, headache or blood pressure rise immediately after micturition. Management of these tumors includes radical surgical treatment with preoperative antihypertensive preparation, and a life-long follow-up. **Case report.** We presented a middle-age female patient with functional urinary bladder paraganglioma, with a 3-year history of repeated episodes of abdominal pain, dysuria and hematuria. After obtaining more precise anamnestic data, the patient reported occasional simultaneous presence of mild adrenergic symptoms, that did not cause any particular attention at first.

### Apstrakt

**Uvod.** Paragangliom je redak neuroendokrini tumor koji vodi poreklo od ekstraadrenalnih autonomnih paraganglija. Paragangliom mokraćne bešike u tipičnom slučaju manifestuje se rekurentnim epizodama palpitacija, glavobolje i skokova krvnog pritiska, nastalih neposredno nakon mokrenja. Lečenje ovog tumora podrazumeva radikalni hirurški zahvat sa karakterističnom preoperativnom pripremom, antihipertenzivnom terapijom i dugotrajnim postoperativnim praćenjem. **Prikaz bolesnika.** Prikazali smo bolesnicu, staru 54 godine, sa funkcionalnim paragangliomom mokraćne bešike i trogodišnjom evolucijom ponavljanih epizoda suprapubičnih bolova, praćenih hematurijom i dizuričnim smetnjama. Tokom prikupljanja detaljnijih anamnestičkih podataka, bolesnica je navela istovremeno prisustvo blagih adrenergičkih simptoma koji su nastupali neposredno nakon mokrenja, na koje inače ranije nije obraćala naročitu pažnju. Nakon spro-

Morphological and biohumoral examinations suggested paraganglioma of the urinary bladder. Open partial cystectomy was performed, detecting a submucosal mass, while immunohistochemical analysis confirmed the presence of chromaffin tissue. Clinical manifestations, diagnostic approach, management and histopathological findings of urinary bladder paraganglioma are discussed. **Conclusion.** Since the prognosis with localized paraganglioma is good, we underlined the importance of a well-timed, accurate and detailed medical history in all the patients with even mild, inexplicable micturition-provoked adrenergic symptomatology.

**Key words:** urinary bladder neoplasms; paraganglioma; diagnosis; urologic surgical procedures; histological techniques.

vođenja dopunskih biohumoralnih i morfoloških ispitivanja dijagnostikovao je paragangliom mokraćne bešike. Tumorska masa je odstranjena parcijalnom cistektomijom, a imunohistohemijskom analizom potvrđeno je postojanje hromafinog tkiva. U radu su analizirane moguće kliničke prezentacije paraganglioma mokraćne bešike, dijagnostički pristup i patohistološka analiza. **Zaključak.** S obzirom na to da bolesnici sa lokalizovanim paragangliomom imaju povoljnu prognozu, naglasili smo značaj pravovremeno uzete, tačne i detaljne anamneze kod bolesnika sa blagom, nerazjašnjenom, adrenergičkom simptomatologijom, koja je provocirana mokrenjem.

**Ključne reči:** mokraćna bešika, neoplazme; paragangliom; dijagnoza; hirurgija, urološka, procedure; histološke tehnike.

## Introduction

A paraganglioma is a rare neoplasm that originate from chromaffin tissue of the extra-adrenal autonomic paraganglia, and have the ability to secrete catecholamines. The tumor is closely related to pheochromocytoma, and undistinguished at the cellular level<sup>1</sup>. Sympathetic paraganglioma may be localized in different parts of the sympathetic paravertebral ganglia of thorax, abdomen or pelvis. Paraganglioma of the urinary bladder accounts for less than 0,06% of all bladder neoplasms, and less than 1% of all pheochromocytomas<sup>2</sup>.

Clinical manifestation of these tumors may be various and nonspecific, since they can be functional or nonfunctional. In most of the cases, signs and symptoms are due to excessive catecholamine secretion, or may be related to the mechanical impact on the surrounding tissues. Typical symptoms are repeated episodes of dizziness, palpitations, headache or hypertensive crises provoked by micturition. In rare cases, the clinical picture is dramatic with general symptomatology or sudden cardiac death<sup>2,3</sup>.

We presented a patient with functional urinary bladder paraganglioma, expressed with a dominant dysuric disabilities and mild inconclusive signs of catecholamine excess, provoked by micturition.

Written informed consent was obtained from the patient for publication of this case report and any accompanying images.

## Case report

A 54-year-old female was admitted to our department, after urological follow-up and suspicion of functional tumor of the urinary bladder. The patient had a history of repeated episodes of suprapubic abdominal pain, dysuria with occasional signs of urinary infection and hematuria over a 3-year period. These symptoms were usually treated with anti-infection drugs.

Her ambulatory urological examination started 6 months prior to admission, when suprapubic pain became more intense, with pelvic ultrasonography showing heterogeneous mass located on the posterior wall of the bladder. Cystoscopic examination revealed solitary submucosal mass of 50 mm in diameter, with normal mucosal covering. Transurethral tissue biopsy of the submucosal mass was taken. Unfortunately, it did not get sufficient amount of tissue material for histopathological examination. During the intervention, no hypertension or other signs of catecholamine excess occurred.

Because of the symptoms persistence and newly registered episodes of high blood pressure, the patient required further examination by the endocrinologist. Only at his insistence, the patient reported the occasional presence of weakness, dizziness, palpitations, headaches and sweating with episodes of sudden blood pressure rise, immediately following micturition. Nevertheless, the patient did not find it necessary to mention at the first time.

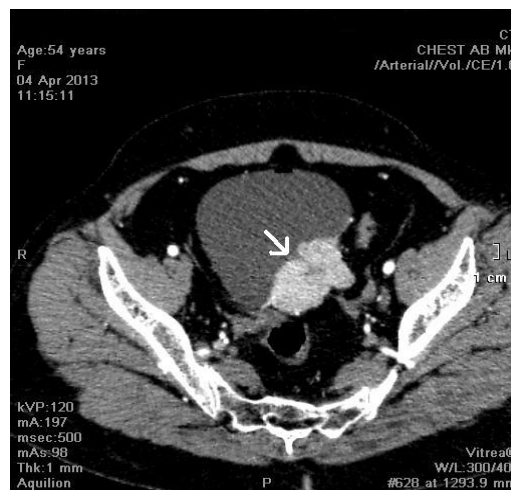On admission, physical examination of the patient was unremarkable. Except for discrete suprapubic palpatory sensitivity, we did not observe any unusual findings. The patient was normotensive, with heart rate of 80 beats *per*

minute, and with no organomegaly. The patient had no orthostatic hypotension. Electrocardiogram showed sinus rhythm, with rare supraventricular extrasystoles and no other abnormalities.

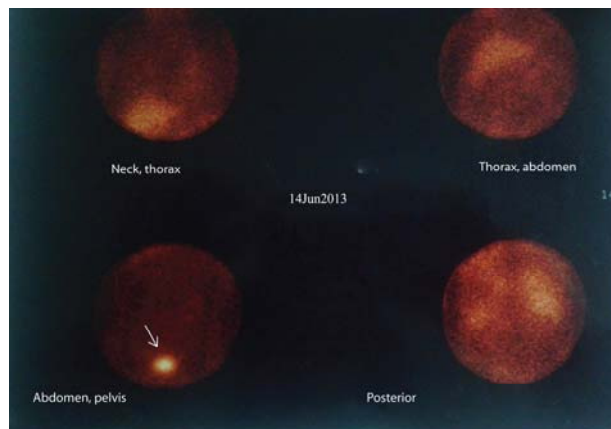
The patient had no medical history of cardiovascular illness or hypertension, and she did not take any lasting medications.

Due to the previous anamnestic data, additional endocrine test were performed. Laboratory blood test revealed the elevated serum metanephrine level of 271 pg/mL (normal range < 90 pg/mL), normetanephrine level of 728 pg/mL (normal range < 180 pg/mL) and chromogranin A level of 114 mcg/L (normal range < 100 mcg/L).

Abdominal and pelvic computed tomography (CT) scan demonstrated highly vascularized mass 53 mm × 35 mm × 50 mm in diameter on the upper-posterior wall of the urinary bladder (Figure 1). No signs of any metastatic disease were found. A <sup>131</sup>I-metaiodobenzylguanidine (<sup>131</sup>I-MIBG) scanning showed a single focus of increased radionuclide activity in urinary bladder (before and after micturition) suggesting residual urine, but also the presence of chromaffin tissue (Figure 2).



**Fig. 1 – Multislice computed tomography (MSCT) demonstrated a mass of 53 mm × 35 mm × 50 mm, located on the upper-posterior wall of the urinary bladder (white arrow).**

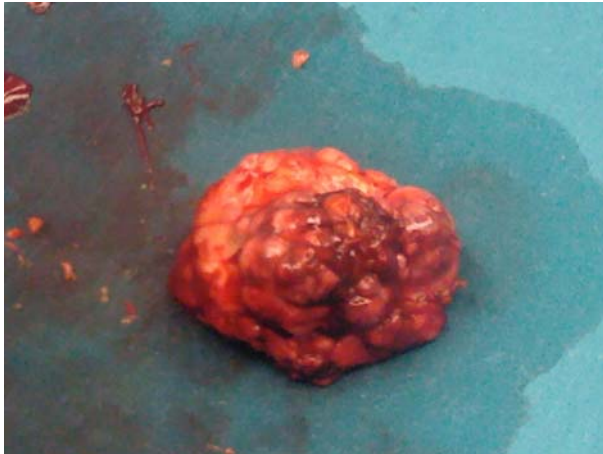


**Fig. 2 – Metaiodobenzylguanidin (MIBG) scan 48 h after administration of <sup>131</sup>I-MIBG-sequential images of neck, thorax, abdomen and pelvis (anterior and posterior projections). Radionuclide uptake is seen in the urinary bladder (white arrow).**

The diagnosis of paraganglioma of the urinary bladder was made.

During the three weeks of preoperative medical treatment with dual adrenoreceptor blocking agents (doxazocine followed by propranolol), our patient exhibited 4 episodes of acute blood pressure rise, up to 240/120 mmHg with the heart rate of 100 beats *per* minute, provoked by micturition. These episodes resolved spontaneously, or by sublingual calcium channel blockers.

The patient was operated and open partial cystectomy was performed revealing a submucosal mass of 50 mm in diameter, with a suspect vesical wall infiltration (Figure 3). No other tumor or lymphnode enlargement were found.



**Fig. 3 – Macroscopic appearance of paraganglioma of the urinary bladder.**

Despite preoperative medical preparation, blood pressure of the patient increased rapidly during the surgery. Postoperative period proceeded with mild hypotension and no complications.

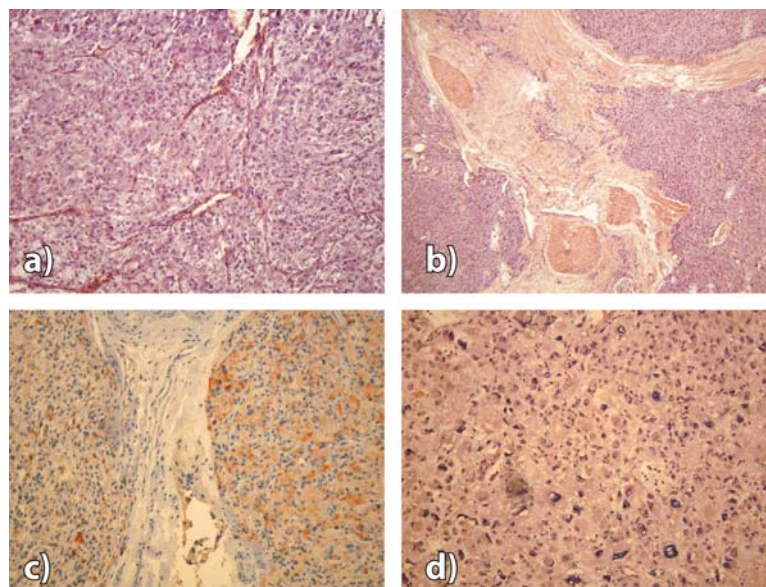
The histopathology result described infiltrative tumor growth with focal prominent cellular polymorphism and poor, well-vascularized tumor stroma. Mitotic figures were rare, and the proliferative activity was very low (Ki67 about 1%), with no tumor necrosis and lymphovascular invasion. Immunohistochemical examination showed strongly positive staining for chromogranin A, synaptophysin and vimentin; thus the diagnosis of paraganglioma was confirmed (Figure 4).

One month after the surgery, the patient was normotensive and micturition-related symptoms disappeared. Plasma levels of metanephrine and normetanephrine normalised. Six months after the surgery, repeated biohumoral measurement and pelvic ultrasonography showed no local recurrence of the tumor.

### Discussion

Urinary bladder paraganglioma is a rare neoplasm, accounting for only 0.06% of all bladder tumors and 6% of all extra-adrenal pheochromocytoma<sup>4</sup>. The tumor usually develops in young adult women. The majority of paragangliomas appear to be sporadic; still, approximately one-third to one-half are hereditary associated with familial paraganglioma, von Hippel-Lindau disease, neurofibromatosis type 1 or multiple endocrine neoplasia type 2<sup>5</sup>.

Since the first report in 1953, about 270 cases of bladder paraganglioma have been reported worldwide<sup>2,6-32</sup>. The most common presentation of bladder paraganglioma is a characteristic clinical picture resulting from a hypertensive crisis accompanied by headache, palpitations, flushes, dizziness or sweating. These symptoms are typically provoked by micturition or overdistension of the bladder, and appear in 90% of the patients<sup>6</sup>. Post-micturition syncope is presented in 65%, while painless hematuria appears in 60% of the patients<sup>7</sup>. Someti-



**Fig. 4 – Pathological findings (histological and immunocytochemical staining).**

- a) Typical arrangement of alveolar tumor cells ("Zellballen" growth pattern) (hematoxylin and eosin,  $\times 100$ );  
 b) Stromal septa with a beach of tumor cells (hematoxylin and eosin,  $\times 40$ ); The chief cells of the tumor have immunoreactivity to neuroendocrine markers; c) Chromogranin A is strongly positive (intense and diffuse cytoplasmic positive reaction in a large number of tumor cells) (3-amino-9-ethylcarbazole,  $100 \times$ ); d) Synaptophysin is positive (reaction is intensively detected in a large number of tumor cells) (Papanicolau,  $\times 100$ ).



mes patients present with long term complications of unregulated hypertension such as intracranial bleeding, retinopathy, cardiac failure or sudden cardiac death. Other symptoms include orthostatic hypotension, abdominal pain, weight loss, nausea, blurred vision, weakness, malaise and paresthesia, presented in 20% of the patients<sup>2-6</sup>.

In the presented patient, the medical history was atypical. From the very beginning she had dysuria with abdominal pain and the occasional presence of hematuria. Subsequently, she got mild, short duration, post-micturition symptoms related to excessive catecholamine secretion. These symptoms did not cause particular attention by the patient, so she did not mention any of them at the beginning of examination. Interestingly, cystoscopic examination and transurethral manipulation during biopsy did not provoke any typical signs and symptoms.

There are several similar presentations of bladder paraganglioma described in the literature. Li et al.<sup>7</sup> reported a case of unsuspected functional paraganglioma of the urinary bladder with a 2-year history of mild painless hematuria, with no hypertension attacks prior to surgery. Chen et al.<sup>8</sup> observed a male patient with gross hematuria and abdominal pain which radiated to the inguinal region suggesting ureteral stone. Only after the diagnosis of urinary bladder paraganglioma was conducted, he revealed previous presence of postural hypotension and palpitations. In the case of nonfunctional paraganglioma of the urinary bladder, lower abdominal pain or dysuria, could be the single present symptom<sup>9</sup>. There is also an unusual case of postponed detection of bladder paraganglioma, misdiagnosed with basilar-type migraine due to the permanent headache lasting for 8 years<sup>10</sup>. Rarely, the presence of dyspnea provoked by micturition could be the only sign of unrecognized bladder paraganglioma<sup>11</sup>.

In patients who are thought to have paraganglioma, biochemical test should be done to measure the levels of metanephrine and normetanephrine, since they are more sensitive than catecholamines<sup>33</sup>. These levels should be measured either in plasma or in a 24-h urine collection. Urinary levels, if determined shortly after or during the hypertensive crisis, have greater sensitivity. It is found that plasma-free metanephrines and urinary fractionated metanephrines offered higher sensitivity (99% and 97%, respectively) than plasma catecholamines, urinary catecholamines, total urinary metanephrines, and urinary vanillylmandelic acid<sup>33</sup>.

The levels of chromogranin A, acidic monomeric protein that is stored and secreted with catecholamines, are increased in more than 80% of patients. Its specificity for paraganglioma is low, and the level of chromogranin A can be increased in other neuroendocrine tumors, too<sup>34</sup>. The presented patient had more than a three-fold increase in normetanephrine plasma value, with slightly elevated chromogranin A plasma value, that is typical for paragangliomas.

Further diagnostic procedures include exact localization and morphological description. Using cystoscopy, paraganglioma are presented as a submucosal globular mass protruding into bladder, with smooth surface and intact mucosa. Although biopsy is usually not recommended, for provoking catecholamine excess by manipulation, we performed biopsy of the submucosal mass for the first time. As we mentioned

before, despite the endocrine activity of bladder tumor, our patient showed no adrenergic symptomatology or acute attack of hypertension during biopsy. CT scanning of the abdomen and pelvis is usually one of the first study performed. CT and magnetic resonance imaging (MRI) scans have similar sensitivity of 98–100%, but their specificity is only 70%<sup>35</sup>. For that reason it is recommended to perform functional imaging. The most commonly used functional study for detecting paragangliomas is scintigraphy with <sup>131</sup>I-MIBG, with the sensitivity ranging from 77% to 90% and a specificity of 95% to 100%<sup>36</sup>. Scintigraphy using <sup>123</sup>I-MIBG is reported to obtain superior images, with the sensitivity ranging from 83% to 100% and a high specificity from 95% to 100%, but the cost and shorter half-life of this isotope limits its use<sup>5</sup>.

During the last two decades, several novel functional imaging techniques have been developed and recommended. These involve somatostatin receptor scintigraphy with <sup>111</sup>In-pentetreotide and positron emission tomography (PET) using <sup>18</sup>F-fluorodeoxyglucose, <sup>18</sup>F-fluorodopa, and <sup>18</sup>F-fluorodopamine, particularly recommended in cases in which other functional imaging tests are negative<sup>18,36,37</sup>.

The diagnosis of bladder paraganglioma in the presented patient was confirmed by CT scan of highly vascularized mass in the posterior wall of the urinary bladder associated with a single focus of increased uptake of <sup>131</sup>I-MIBG in that region.

As we previously mentioned, extra adrenal paragangliomas can rarely be inherited as an isolated autosomal dominant trait, or as a part of the multiple endocrine neoplasia type II syndrome, as well as with neurofibromatosis and von Hippel-Lindau disease. Since the presented patient had no symptoms, clinical or biochemical manifestations suggesting any of these syndromes, no genotyping testing was conducted.

After localization of the tumor, surgical removal should be performed.

For all the patients with paraganglioma, it is essential to conduct adequate preoperative medical treatment based on antihypertensive control. An alpha-blocker, phenoxybenzamine, gradually increased up to 1–2 mg/kg body weight daily, is the first choice therapy. Beta-blockers should be taken only after alpha-blockers have been started, mostly if tachycardia is present<sup>2,4</sup>. We used doxazosin followed by propranolol for a 3-week period, since the presented patient had got 4 episodes of catecholamine excess after micturition in a preoperative period.

Surgical treatment modalities include transurethral resection, or open laparotomy with partial or total cystectomy, combined with pelvic lymph node dissection. Transurethral resection is not recommended in case of suspect invasion of the muscular layer. Total cystectomy is often performed in case of pelvic lymphadenopathy<sup>3,16</sup>. Some authors consider laparoscopic resection as the first choice modality in treatment of bladder paraganglioma<sup>15,38</sup>. Nevertheless, since paraganglioma is easy to recur it is recommended that the tumor and its peri-tissue should be resected completely. Since patients with localized tumors have the favorable prognosis, they could be treated with less radical modalities<sup>4,5,32</sup>. Our patient underwent open laparotomy and partial resection of the urinary bladder with *ex tempore* verification of no microinvasion into the bladder wall.

The final diagnosis is based upon histological and immunohistochemical analysis. Paragangliomas show histological features similar to adrenal pheochromocytoma. The chief cells of the tumor show immunoreactivity to neuroendocrine markers such as chromogranin A, synaptophysin and neuron-specific enolase<sup>31,39</sup>. It is difficult to histopathologically diagnose paraganglioma as malignant or benign. There is no certain way to predict which tumor will progress to malignancy. In clinical practice, the only reliable criterion of malignancy is the presence of distant metastases.

Due to the unpredictable course, late endocrinal manifestations and metastasis, long-term follow up is advised<sup>24</sup>. Although there are no official guidelines for postoperative follow-up, first measurement of plasma metanephrine and normetanephrine values are recommended a month after surgery, and later every 6 months for a period of 2 years. In the suspect cases, abdominal

and pelvic CT imaging is recommended every 3 months for a year; then every 6 months for the period of one year, and later yearly for the period of 3 years subsequently<sup>4,5</sup>.

### Conclusion

Paraganglioma of the urinary bladder is a rare neoplasm with varied clinical presentation, sometimes very subtle and easily overlooked. Since patients with localized tumor have the good prognosis, it is important to recognize possible symptoms in time, proceeding an accurate and detailed medical history. A combination of specific symptoms, biohumoral testing and image investigation is crucial in diagnosis, while the partial and total cystectomy is the treatment of choice. Since paraganglioma is more likely to recur or metastasize, it is essential to make a long term follow-up of these patients.

### R E F E R E N C E S

1. *Kantorovich V, Pacak K.* Pheochromocytoma and paraganglioma. *Prog Brain Res* 2010; 182: 343–73.
2. *Li W, Yang B, Che JP, Yan Y, Liu M, Li QY,* et al. Diagnosis and treatment of extra-adrenal pheochromocytoma of urinary bladder: case report and literature review. *Int J Clin Exp Med* 2013; 6(9): 832–9.
3. *Chrisoulidou A, Kaltsas G, Ilias I, Grossman AB.* The diagnosis and management of malignant pheochromocytoma and paraganglioma. *Endocr Relat Cancer* 2007; 14(3): 569–85.
4. *Beilan J, Lawton A, Hajdenberg J, Rosser C.* Pheochromocytoma of the urinary bladder: A systemic review of the contemporary literature. *BMC Urology* 2013; 13(1): 22.
5. *Disick GI, Palese MA.* Extra-adrenal pheochromocytoma: Diagnosis and management. *Curr Urol Rep* 2007; 8(1): 83–8.
6. *Deng J, Li H, Zhang Y, Liu G.* Functional paragangliomas of the urinary bladder: a report of 9 cases. *Chin J Cancer* 2010; 29(8): 729–34.
7. *Li S, Liu S, Li F, Yue Q, Huang X, Gong Q.* Unsuspected paraganglioma of the urinary bladder with intraoperative hypertensive crises: A case report. *Exp Ther Med* 2013; 6(4): 1067–9.
8. *Chen Y, Kuo HC.* A small pheochromocytoma of the urinary bladder with atypical symptoms. *Tzu Chi Med J* 2006; 18: 295–8.
9. *Xu D, Chen M, Liu Y, Gao Y, Cui X.* Non-functional paraganglioma of the urinary bladder: a case report. *J Med Case Reports* 2010; 4(1): 216.
10. *Pichler R, Heidegger I, Klinglmair G, Kroiss A, Uprimny C, Gasser RW,* et al. Unrecognized paraganglioma of the urinary bladder as a cause for basilar-type migraine. *Urol Int* 2014; 92(4): 482–7.
11. *El Khoury F, Jour I, Malaeb B, Assaf G.* Bladder paraganglioma. A case report. *J Med Liban* 2012; 60(3): 182–4.
12. *Oderda M, Michelin F, Appendino M, Gallo M, Senetta R, Pacchioni D,* et al. Primary bladder pheochromocytoma diagnosed by a vet. *Scand J Urol Nephrol* 2010; 44(3): 186–9.
13. *Tsai C, Wu W, Chueh K, Li W, Huang C, Wu C,* et al. Paraganglioma of the urinary bladder first presented by bladder bloody tamponade: two case reports and review of the literatures. *Kaohsiung J Med Sci* 2011; 27(3): 108–13.
14. *Kang SG, Kang SH, Choi H, Ko YH, Park HS, Cheon J.* Robot-assisted partial cystectomy of a bladder pheochromocytoma. *Urol Int* 2011; 87(2): 241–4.
15. *Wu FM, Kao SL, Thamboo TP, Tsang WC, Heng CT, Tiong HY.* Laparoscopic Partial Cystectomy for Symptomatic Paraganglioma of the Urinary Bladder: A Case Report. *Uro Today Int J* 2011; 4(1): art3.
16. *Zeitlin I, Dessau H, Lorberboym M, Beigel Y.* Malignant pheochromocytoma of the urinary bladder: challenges in diagnosis and management. *Isr Med Assoc J* 2011; 13(5): 311–3.
17. *Hanji AM, Roban VS, Patel JJ, Tanksbali RA.* Pheochromocytoma of the urinary bladder: a rare cause of severe hypertension. *Saudi J Kidney Dis Transpl* 2012; 23(4): 813–6.
18. *Manohar K, Mittal BR, Bhattacharya A, Kashyap R, Aggarwal MM, Mandal AK.* A rare case of malignant urinary bladder paraganglioma with distant metastases demonstrated by 18F-FDG PET/CT. *Clin Nuc Med* 2012; 37(6): 148–9.
19. *Beilan J, Lawton A, Hajdenberg J, Rosser C.* Locally advanced paraganglioma of the urinary bladder: a case report. *BMC Res Notes* 2013; 6: 156.
20. *Macedo F, Filgueiras CH, de Abreu C, Carlos L, Reis AA, Neto RM,* et al. Non-functionant urinary bladder paraganglioma. *Health Med* 2012; 6(2): 568–70.
21. *Christodoulidou M, Lucky M, Mansour P, Gammal M.* Incidental paraganglioma of the urinary bladder in a 66-year-old woman. *BMJ Case Rep* 2013; 2013. pii: bcr2013008771.
22. *Acharya S, Shukla S, Gupta A, Mahajan SN.* Extra Adrenal Pheochromocytoma Presenting as Hypertensive Crisis in a Young Male. *Ind Med Gazette* 2013; 238–41.
23. *Abn SG, Jang H, Han DS, Lee JU, Yuk SM.* Transurethral resection of bladder tumour (TURBT) as an optional treatment method on pheochromocytoma of the urinary bladder. *Can Urol Assoc J* 2013; 7(1–2): E130.
24. *Feng N, Li X, Gao H, Liu Z, Shi L, Liu W.* Urinary bladder malignant paraganglioma with vertebral metastasis: a case report with literature review. *Chin J Cancer* 2013; 32(11): 624–8.
25. *Malik AA, Afandi B, Jamil G, Akbter SM.* Paraganglioma of urinary bladder. *BMJ Case Rep* 2013; 2013. pii: bcr2013010063.
26. *Qian S, Yang L, Liu M, Li Y, Han P, Yuan J,* et al. Bladder paraganglioma during pregnancy characterized by bladder bloody tamponade with normotension: A case report and review of the literatures. *Health Med* 2013; 7(5): 1388–91.
27. *Han YJ, Shin HS, Jung YS, Rim H, Ock SY, Kim EJ.* Bladder pheochromocytoma presented as thunderclap headache triggered by urination and angina pectoris. *Kosin Med J* 2013; 28(2): 161–5.
28. *Kumar MU, Pande P, Savita SS, Ashwin PK, Yelikar BR.* An Extra-adrenal Pheochromocytoma Presenting as Malignant Hy-

- hypertension-A Report of two cases. *J Clin Diagn Res* 2013; 7(6): 1177-9.
29. *Lai Y, Chen D, Yu Z, Ni L, Yang S.* Non functioning paraganglioma of the urinary bladder: A case report and review of the literature. *Oncol Lett* 2014; 7(3): 891-3.
30. *Kempasiddaiab GM, Thimmaiah R, Gurappa M.* A rare case of early pregnancy with paraganglioma of urinary bladder. *Int J Cur Res Rev* 2014; 6(4): 15-20.
31. *Menon S, Goyal P, Suryavanshi P, Tongaonkar H, Joshi A, Baksbi G,* et al. Paraganglioma of the urinary bladder: a clinicopathologic spectrum of a series of 14 cases emphasizing diagnostic dilemmas. *Ind J Pathol Microbiol* 2014; 57(1): 19-23.
32. *Al-Zabirani AA.* Recurrent urinary bladder paraganglioma. *Adv Urol* 2010; 2010: 912125.
33. *Eisenhofer G, Goldstein DS, Walther MM, Friberg P, Lenders JW, Keiser HR,* et al. Biochemical diagnosis of pheochromocytoma: how to distinguish true- from false-positive test results. *J Clin Endocrinol Metab* 2003; 88(6): 2656-66.
34. *Lenders JW, Pacak K, Walther MM, Linehan W, Mannelli M, Friberg P,* et al. Biochemical diagnosis of pheochromocytoma: which test is best. *JAMA* 2002; 287(11): 1427-34.
35. *Brink I, Hoegerle S, Klisch J, Bley TA.* Imaging of pheochromocytoma and paraganglioma. *Fam Cancer* 2005; 4(1): 61-8.
36. *Ilias I, Yu J, Carrasquillo JA, Chen CC, Eisenhofer G, Whatley M,* et al. Superiority of 6-[18F]-fluorodopamine positron emission tomography versus [131I]-metaiodobenzylguanidine scintigraphy in the localization of metastatic pheochromocytoma. *J Clin Endocrinol Metab* 2003; 88(9): 4083-7.
37. *Liu Y, Dong S, Dong Z, Mao X, Shi X.* Diagnosis and treatment of pheochromocytoma in urinary bladder. *J Zhejiang Univ Sci B* 2007; 8(6): 435-8.
38. *Dilbaz B, Bayoglu Y, Oral S, Cavusoglu D, Uluoglu O, Dilbaz S.* Laparoscopic resection of urinary bladder paraganglioma: a case report. *Surg Laparosc Endosc Percutan Tech* 2006; 16(1): 58-61.
39. *Kliener KE, Cochran AJ.* A review of the histology, ultrastructure, immunohistology, and molecular biology of extra-adrenal paragangliomas. *Arch Pathol Lab Med* 1989; 113(11): 1209-18.

Received on April 9, 2014.

Revised on June 12, 2014.

Accepted on July 10, 2014.

Online First July, 2015.