



Aggravation of symptomatic occipital epilepsy of childhood by carbamazepine

Pogoršanje simptomatske okcipitalne dečje epilepsije izazvano karbamazepinom

Fadil E. Škrijelj, Mersudin Mulić

State University of Novi Pazar, Novi Pazar, Serbia

Abstract

Introduction. Carbamazepine can lead to aggravation of epileptic seizures in generalized epilepsies (primary or secondary) with clinical manifestations of absence (typical or atypical) and/or myoclonic seizures. However, some focal epilepsies can be also aggravated by the introduction of carbamazepine. **Case report.** We presented a 10-year-old boy born after a complicated and prolonged delivery completed by vacuum extraction, of early psychomotor development within normal limits. At the age of 8 years he had the first epileptic seizure of simple occipital type with generalization and urination. Brain magnetic resonance imaging (MRI) showed focal cortical reductions in the left parietal and occipital regions. Interictal EEG recorded slowed basic activities above the posterior regions of the left hemisphere, with intermittent occurrence of occipital sharp waves and bioccipital sharp and slow-wave complexes. Initially, treatment with valproate was administered; however, the addition of carbamazepine into therapy induced aggravation of seizures and EEG findings, changed behavior and poor performance at school. By withdrawal of carbamazepine the condition improved both clinically and in EEG findings. **Conclusion.** Childhood occipital epilepsy lesions show deterioration due to carbamazepine, which if administered induces aggravation of seizures, behavior changes, cognition with occurrence of long-term bilateral discharges, and posterior sharp and slow-wave high amplitude complexes recorded by EEG.

Key words:

epilepsies, partial; seizures; valproate acid; carbamazepine; child; treatment outcome; drug incompatibility.

Apstrakt

Uvod. Karbamazepin može dovesti do pogoršanja epileptičnih napada kod generalizovanih epilepsija (primarnih ili sekundarnih), koje u kliničkoj slici imaju apsanse (tipične ili atipične) i/ili mioklonusne napade. I neke fokalne epilepsije, međutim, mogu se pogoršati uvođenjem karbamazepina. **Prikaz bolesnika.** Prikazali smo dečaka, starog 10 godina, rođenog posle komplikovanog i produženog porođaja koji je završen vakuum ekstrakcijom, urednog ranog psihomotornog razvoja. U 8 godini imao je prvi epileptični napad, tipa jednostavnog okcipitalnog, sa generalizacijom i umokraivanjem. Nalaz snimanja magnetnom rezonancom (MRI) mozga ukazao je na fokalne kortikalne reduktivne promene parieto-okcipitalno, levo. Interiktusni EEG je beležio usporenu osnovnu aktivnost iznad zadnjih regiona leve hemisfere, sa povremenim izbijanjem okcipitalnih oštih talasa, i bi-okcipitalnih oštar talas-spori talas kompleksa. U početku dečak je lečen valproatom, a kada je u terapiju uveden i karbamazepin, došlo je do pogoršanja napada, EEG nalaza, promene ponašanja i lošeg uspeha u školi. Isključenjem karbamazepina stanje se popravilo, kako klinički, tako i u EEG nalazu. **Zaključak.** Leziona okcipitalne epilepsije u detinjstvu pokazuju pogoršanje sa karbamazepinom, jer posle njegovog uvođenja dolazi do pogoršanja napada, promena ponašanja, kognicije sa pojavom dugotrajnih bilateralnih pražnjenja i posteriornih oštar talas-spori talas kompleksa visoke amplitude u EEG.

Ključne reči:

epilepsije, parcijalne; konvulzije; valproinska kiselina; karbamazepin; deca; lečenje, ishod; lek, inkompatibilnost.

Introduction

The basic goal of antiepileptic therapy (AET) is to fully control seizures with a satisfactory quality of life of the patient. AET is primarily aimed at the suppression of clinical

manifestation of seizures, while the expected normalization of epileptiform EEG abnormalities is a reasonable therapeutic goal. The basic precondition of successful treatment is making the correct diagnosis of epilepsy. The type of seizures, the type of epileptic syndrome and etiology of epilepsy should be de-

terminated as soon as possible, as this will influence the choice of medication, mode of treatment and prognosis¹. Today AET is still the first-line method in the treatment of most epilepsies, while the choice of drugs is in constant increase².

Carbamazepine (CBZ) is an antiepileptic with a wide clinical application in treatment of focal and secondary generalised tonic-clonic (GTC) seizures. Idiopathic generalized epilepsies (IGE), such as juvenile absence epilepsy, juvenile myoclonic epilepsy and epilepsy with GTC seizures on awakening feature seizure aggravation when CBZ is introduced into therapy^{3, 4}. Epilepsies with clinical manifestations involving absences and/or myoclonic seizures, and EEG recording with bilateral generalized 4–6 Hz spike-and-wave complex discharges, show clinical and EEG worsening by introduction of CBZ⁴. CBZ-induced aggravation of focal idiopathic epilepsies is atypical form of childhood benign epilepsies with centro-temporal spikes (atypical BECTS)⁵, atypical cases of Panayiotopoulos syndrome⁶, and cases of late idiopathic occipital epilepsies of childhood (Gaustat type)⁷. Focal symptomatic epilepsies presenting aggravation by CBZ are occipital epilepsies of childhood with unilateral or bilateral occipital sharp-wave and slow-wave complexes recorded by EEG⁵. CBZ is also contraindicated in the following syndromes: Dravet, Dosse, Lennox-Gastaut, Angelman, Landau-Kleffner and epileptic syndrome with bilateral continuous spike-and-wave activity during slow-wave sleep...^{7–11}. Besides, their EEGs demonstrate bilateral discharges of spike-multiple spike and slow-wave complexes at 1–2.5 Hz, which clinically often correlates with atypical absences and myoclonic seizures. Misinterpretation of focal discharges as recorded by EEG in idiopathic generalized epilepsies and consecutive inclusion of CBZ, the medication for focal seizures, leads to the paradoxical aggravation of seizures¹².

Case report

We reported a 10-year-old boy, body weight (BW) 63.5 kg, body height (BH) 148 cm, born of the first term pregnancy after a complicated and prolonged delivery completed by vacuum extraction, with normal early psychomotor development, normal neurological and psychiatric status, negative heredity for epilepsy, febrile attacks, inflammatory and traumatic brain disorders. At the age of 8, one morning after breakfast, the boy developed the first epileptic seizure, which, according to the patient's case history and the parents initiated with optical images of bright colored circles, headache, version of the eyes and head to the left, tonic-clonic convulsions right-sided at onset and later of the whole body, loss of consciousness and urination. Seizures occurred every 1–2 months, during the day only. Standard EEG demonstrated a slow basic activity above the posterior region of the left hemisphere with occasional focal sharp spike-slow-wave complexes or slow-waves at 4–5 Hz in the left parietal-occipital and temporal-occipital regions (Figure 1). Short bi-occipital sharp and slow-wave complexes at 1.5 Hz, amplitude exceeding 100 μ V with left-sided predominance were also recorded. In view of such EEG findings in correlation with cortical MRI reductions in the left parietal-occipital re-

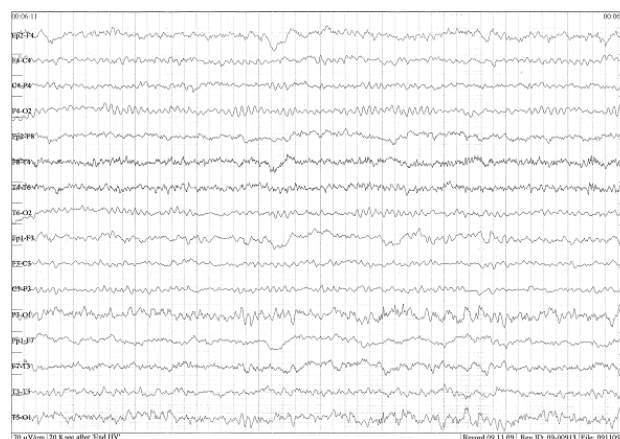


Fig. 1 – EEG before introduction of carbamazepine (CBZ) into therapy.

gion it was implicitly concluded that this was indicative of a symptomatic epileptic lesion of the occipital lobe with secondary generalization. Valproat (VAL) in the dose of 30 mg/kg/day was included into therapy, which resulted in a complete control of secondary GTC seizures over a 6-month period. As the patient still complained of occasional visual problems followed by headaches, CBZ in dose of 10 mg/kg/day was also included into therapy. After including of CBZ, GTC seizures relapsed, which led the neurologist to increase the dose of CBZ to 30 mg/kg/day, without previously performing a check-up EEG. Beside the aggravation of seizures, the parents noticed changes in the child's behavior: he seemed withdrawn, often aggressive and performed poorly at school. Being dissatisfied with the developed situation, the parents turned to another neurologist. EEG was performed showing the presence of long-term bilateral discharges of a posterior sharp wave-slow-wave complex at 1–1.5 Hz, amplitude exceeding 300 μ V (Figure 2), which are

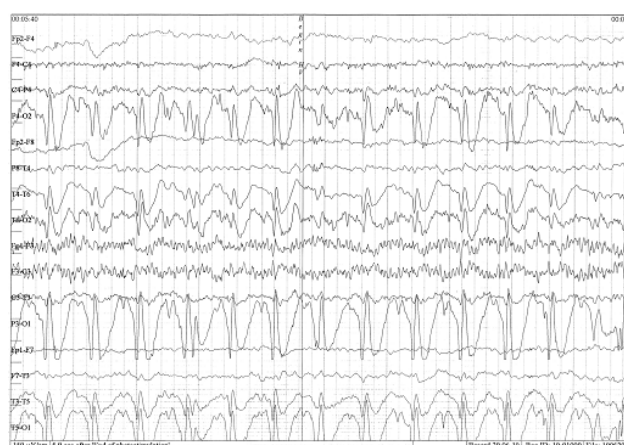


Fig. 2 – Long-term discharges of bilateral posterior high-voltage sharp-wave and slow-wave complex.

seen in aggravation by carbamazepine. On check-up, blood antiepileptic (VAL and CBZ) levels were within the therapeutic levels. Based on the deterioration of clinical features and EEG findings, it was concluded that CBZ was probably the cause of the developed condition. By withdrawal of CBZ, secondary GTC seizures ceased, as well as the long-standing

bilateral discharges of the high-voltage posterior sharp wave-slow-wave complex (Figure 3). Carbamazepine was replaced with lamotrigine, but having caused skin rash it had to be withdrawn. By a daily dose of 500 + 0 + 500 mg valproate and 25 + 0 + 25 mg topiramate, we achieved a full control even of simple occipital seizures. The patient has been without seizures for a year now, cognitive and affective disorders withdrew and his performance at school also improved.

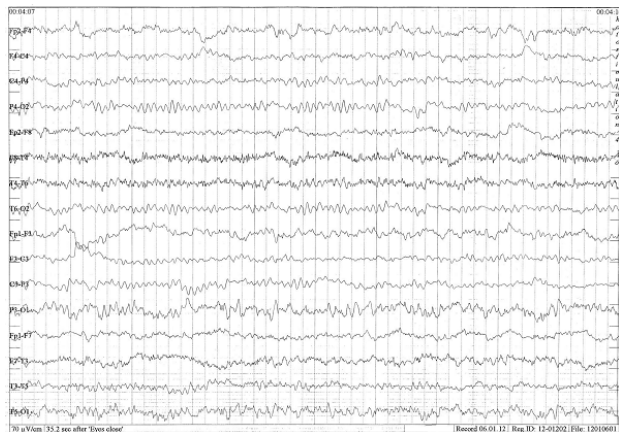


Fig. 3 – Discontinuation of bilateral posterior high-voltage sharp-wave and slow-wave complex discharge after withdrawal of carbamazepine (CBZ) from therapy.

Discussion

Occipital lobe epilepsies are not frequently seen in the clinical practice, and have a prevalence ranging from 5–10% of all epilepsies. They can be symptomatic, i.e. of cryptogenic etiology occurring at any age or idiopathic which as a rule occur in childhood¹³. In symptomatic occipital lobe epilepsies about 50% of children have MRI ischemic lesions of type porencephalia, periventricular leukomalacia or cerebral infarction¹⁴. The clinical semiology of seizures involves visual and oculomotor symptoms. Seizures are of simple focal type, while the occurrence of complex focal seizures is the sign of extra-occipital propagation of discharges in the parietal, temporal or frontal lobes. The visual symptomatology is predominated by elementary, quite rare and complex visual hallucinations, illusions and palinopsia. They are often in the form of small colorful circles moving across the visual field or rarely flashing and flickering lights¹⁵. Elementary visual hallucinations are often followed by oculomotor symptoms with tonic deviation of the eyes and head, epileptic nystagmus or eye blinking. Visual hallucinations are the key symptoms suggesting an occipital focus. If visual symptoms are not marked, the semiology of seizures and standard EEG can be a frequent cause of incorrect diagnosis, as they often reflect the condition of discharges propagation and less their initiation¹⁶. Interictal EEG shows occipital spikes and/or sharp wave slow-wave complexes in 57% of cases, unilaterally or bilaterally¹⁷. Bioccipital discharges of sharp wave and slow wave complexes (spike and slow-wave complex) occur in epilepsies of symptomatic and idiopathic etiology¹⁸. Prognosis is favorable in idiopathic and unfavorable in symptomatic

epilepsy when it essentially depends on the type and size of the causal lesion. Pharmacoresistance is seen in most cases with disorders of cortical development or tumor of the occipital lobe when surgical treatment is the method of choice¹⁷. By the example of our patient the deterioration of seizures occurred when, beside VAL, CBZ was introduced into therapy in order to control simple occipital seizures followed by headaches. Despite the parents' suggestion that seizures worsened after the introduction of CBZ, the neurologist increased CBZ dose without performing a check-up EEG; i.e. therapeutic effects of CBZ were not under concurrent clinical and EEG follow-up. CBZ can induce unusual electroclinical manifestations that can be explained by synchronization and increased bilateral EEG discharges¹⁹. It is well known that CBZ can increase present or activate new bilateral EEG discharges of spike-polyspike and spike-wave complex and sharp wave-slow wave complex, and that it is contraindicated in such cases^{11, 20}. Oxcarbazepine, vigabatrin, tiagabine and gabapentin are also contraindicated^{5, 9, 21}. Increased bilateral EEG discharges often result in exacerbation of seizures, as well as the occurrence of other type of seizures⁶. It should be pointed out that it is impossible to predict the effect of an antiepileptic on the EEG of a person with epilepsy and that some patients respond to antiepileptics on individual for a group unpredictable way²². In our patient, the deterioration of EEG findings induced by CBZ correlated with the aggravation of seizures, change of behavior and cognition. Studies have shown that long-term bilateral interictal discharges of spike-wave complex or sharp wave-slow wave complex, particularly in childhood, can be followed by transitory cognitive and behavioral disorders^{20, 23}. In children and adults with epilepsy, bilateral interictal EEG discharges of spike-polyspike and spike-wave complex or sharp wave-slow wave complex are a stabile predictor of aggravation by carbamazepine^{11, 12}. Our example shows that symptomatic lesions of occipital lobe epilepsy, which have unilateral and/or bilateral discharges of sharp-and-slow-wave complex in interictal EEG, can also manifest aggravation by CBZ. In such cases it is possible that there is also present an additional (probably genetic) factor that enables the reaction of aggravation by CBZ. Although epilepsy is primarily a clinical diagnosis, the correlation of epileptic seizures and EEG changes is necessary, both for diagnostics, as well as for the follow-up of antiepileptic therapy effects¹.

Conclusion

Epilepsy treatment with drugs inadequate for the given type of seizures has a deteriorating effect on epilepsy, and when the drug of choice causes clinical worsening correlating with the activation of new and increase of already present EEG discharges, aggravation by an antiepileptic should be taken into consideration. Lesional occipital epilepsies of childhood show aggravation by carbamazepine, which, if administered, induces aggravation of seizures, behavior changes, cognition with the occurrence of long-term bilateral discharges, and posterior sharp-wave and slow-wave high amplitude complexes recorded by EEG.

R E F E R E N C E S

1. *Shorvon SD*. The etiologic classification of epilepsy. *Epilepsia* 2011; 52(6): 1052–7.
2. *Stephen LJ, Brodie MJ*. Pharmacotherapy of epilepsy: newly approved and developmental agents. *CNS Drugs* 2011; 25(2): 89–107.
3. *Murthy JM*. Seizure aggravation with antiepileptic drugs in idiopathic generalized epilepsy. *Neurol India* 2011; 59(1): 51–2.
4. *Aurin S*. Treatment of juvenile myoclonic epilepsy. *CNS Neurosci Ther* 2008; 14(3): 227–33.
5. *Gayatri NA, Livingston JH*. Aggravation of epilepsy by anti-epileptic drugs. *Dev Med Child Neurol* 2006; 48 (5): 394–8.
6. *Kikumoto K, Yoshinaga H, Oka M, Ito M, Endoh F, Akiyama T, et al.*. EEG and seizure exacerbation induced by carbamazepine in Panayiotopoulos syndrome. *Epileptic Disord* 2006; 8(1): 53–6.
7. *Caraballo R, Koutroumanidis M, Panayiotopoulos CP, Fejerman N*. Idiopathic childhood occipital epilepsy of Gastaut: A review and differentiation from migraine and other Epilepsies. *J Child Neurol* 2009; 24(12): 1536–42.
8. *Moseley DB, Wirrell EC, Nickels K*. Generalized periodic epileptiform discharges in child with Dravet syndrome. *J Child Neurol* 2011; 26(7): 907–10.
9. *Nakken KO, Johannessen SI*. Seizure exacerbation caused by antiepileptic drugs. *Tidsskr Nor Lægeforen* 2008; 125(18): 2052–5. (Norwegian)
10. *Camfield P, Camfield C*. Monitoring for adverse effects of anti-epileptic drugs. *Epilepsia* 2006; 47(Suppl 1): 31–4.
11. *Pernucca E, Gram L, Avanzini G, Dulac O*. Antiepileptic drugs as a cause of worsening seizures. *Epilepsia* 1998; 39(1): 5–17.
12. *Crespel A, Genton P, Velizarova R, Coubes P, Gelisse P*. Wicket spikes misinterpreted as focal abnormalities in idiopathic generalized epilepsy with prescription of carbamazepine leading to paradoxical aggravation. *Neurophysiol Clin* 2009; 39(3): 139–42.
13. *Panayiotopoulos CP*. A Clinical guide to epileptic syndromes and their treatment. 2nd ed. London: Springer Healthcare Ltd; 2010. p. 135–47.
14. *Kuzniecky R*. Symptomatic occipital lobe epilepsy. *Epilepsia* 1998; 39(Suppl 4): S24–31.
15. *Blume WT, Wiebe S, Tapsell LM*. Occipital epilepsy: lateral versus mesial. *Brain* 2005; 128(5): 1209–25.
16. *Taylor I, Scheffer IE, Berkovic SF*. Occipital epilepsies: identification of specific and newly recognized syndromes. *Brain* 2003; 126 (4): 753–69.
17. *Jobst BC, Williamson PD, Thadani VM, Gilbert KL, Holmes GL, Morse RP, et al.*. Intractable occipital lobe epilepsy: Clinical characteristics and surgical treatment. *Epilepsia* 2010; 51(11): 2334–7.
18. *Andermann F, Zifkin B*. The benign occipital epilepsies of childhood: An overview of the idiopathic syndromes and of the relationship to migraine. *Epilepsia* 1998; 39 (Suppl 4): S9–23.
19. *Terney D, Ahving J, Skaarup CN, Wolf P, Beniczky S*. The slow-wave component of the interictal epileptiform EEG discharges. *Epilepsy Res* 2010; 90(3): 228–33.
20. *Prasad AN, Stefanelli M, Nagarajan L*. Seizure exacerbation and developmental regression with carbamazepine. *Can J Neurol Sci* 1998; 25(4): 287–94.
21. *Vendrame M, Khurana DS, Cruz M, Mehlin J, Valencia I, Legido A, et al.*. Aggravation of seizure and/or EEG features in children treated with oxcarbazepine monotherapy. *Epilepsia* 2007; 48(11): 2116–20.
22. *Luciano AL, Shorvon SD*. Results of treatment changes in patients with apparently drug-resistant chronic epilepsy. *Ann Neurol* 2007; 62(4): 375–81.
23. *Bhise VV, Burack GD, Mandelbaum DE*. Baseline cognition, behavior, and motor skills in children with new-onset idiopathic epilepsy. *Dev Med Child Neurol* 2010; 52(1): 22–6.

Received on June 28, 2012.

Revised on October 19, 2012.

Accepted on October 23, 2012.