



Efficacy of nanocrystalline bone substitute biphasic calcium phosphate/poly-DL-lactide-co-glycolide for periodontal intrabony defects filling

Efikasnost nanokristalnog zamenika kosti bifaznog kalcijum-fosfata-poli-DL-laktid-ko-glikolida za popunjavanje infrakoštanih defekata parodontcijuma

Momir Stevanović*, Vladimir Biočanin†, Milica Nedić*, Nenad Ignjatović§

*Department of Periodontology, Faculty of Medicine, University of Kragujevac, Kragujevac, Serbia; †Department of Dentistry, Faculty of Pharmacy and Health, University of Travnik, Travnik, Bosnia and Herzegovina; ‡Clinic of Periodontology and Oral Medicine, Faculty of Dentistry, Pančevo, Serbia; §Institute of Technical Sciences of the Serbian Academy of Sciences and Arts, Belgrade, Serbia

Abstract

Background/Aim. Different bone substitutes have been used for filling and reparation of intrabony defects. The aim of this study was to compare nanocrystalline material, biphasic calcium phosphate poly-DL-lactide-co-glycolide (BCP/PLGA) with deproteinised bovine bone (DPBB) and β -tricalcium phosphate (β -TCP) in the treatment of periodontal intrabony defects. **Methods.** The study included 24 patients with bilateral, intrabony defects in the region of the upper first and second premolar, and the upper first molar. On one side of the mouth, DPBB (BioOss®) was used to fill defects in upper premolars while β -TCP (RTR®) was used for the upper first molar. BCP/PLGA was applied into periodontal defects of the upper premolars and upper first molar of the opposite side. **Results.** The comparison of the BCP/PLGA and the β -TCP group, 6 months following filling of defects, showed a statistically significant reduction of periodontal pocket depth (PPD) and the position of the cement-enamel junction (CEJ) in the group with BCP/PLGA, when compared to the β -TCP group. The reduction of PPD and CEJ was similar in the groups treated with BCP/PLGA and DPBB. **Conclusion.** Significant reductions of PPD and CEJ were registered in the group with BCP/PLGA when compared to the β -TCP group.

Key words:

bone resorption; bone substitutes; oral surgical procedures; biocompatible materials; nanoparticles; treatment outcome.

Apstrakt

Uvod/Cilj. Različiti koštani zamenici koriste se za punjenje i reparaciju infrakoštanih defekata. Cilj rada bio je da se uporedi nanokristalni materijal – bifazni kalcijum-fosfat poli-DL-laktid-ko-glikolid (BCP/PLGA) sa deproteinizovanom goveđom kosti (DPBB) i β -trikalcijum fosfatom (β -TCP) u terapiji humanih parodontalnih infrakoštanih defekata. **Metode.** U studiju su bila uključena 24 pacijenata sa bilateralnim, infrakoštanim defektima u regiji gornjeg prvog i drugog premolara i prvog gornjeg molara. Slučajnim izborom defekti su punjeni DPBB (BioOss®) – gornji premolar i β -TCP (RTR®) – prvi gornji molar. BCP/PLGA bio je postavljan u parodontalne defekte gornjih premolara i prvog gornjeg molara sa suprotne strane. Plak indeks (PI), indeks krvarenja gingive (BI), pozicija cementnoglednog pripoja (CEJ) i dubina parodontalnog džepa (PPD) mereni su preoperativno i šest meseci nakon operacije. **Rezultati.** Poređenjem BCP/PLGA i β -TCP grupe utvrđena je statistički značajna redukcija PPD i CEJ šest meseci nakon operacije. Redukcija PPD i CEJ bila je slična u grupama koje su tretirane sa BCP/PLGA i DPBB. **Zaključak.** Značajno smanjenje PPD i CEJ registrovano je u grupi sa BCP/PLGA u poređenju sa β -TCP grupom.

Ključne reči:

kost, resorpcija; kost, zamenici; hirurgija, oralna, procedure; biokompatibilni materijali; koloidi; lečenje, ishod.

Introduction

Modern periodontal therapy is based on the use of natural or synthetic biomaterials for the filling and reparation of

intrabony defects. Different bone substitutes have been used for this purpose with various rates of success¹⁻³. Deproteinised bovine bone (DPBB) is considered the most tested bone substitute in periodontal surgery. It has been suggested that

DPBB possesses osteoconductive properties⁴, allowing the fast attachment of osteoblasts and deposition of new bone⁵. A significant reduction in depth of intrabony defects has been observed after implantation of DPBB⁶. Scabbia and Trombelli⁷ have indicated that implantation of DPBB produced significant improvement in terms of cement-enamel junction (CEJ) and the reduction of periodontal pocket depth (PPD) of human intrabony defects.

It has been shown that β -tricalcium phosphate (β -TCP) promotes osteogenesis and bone regeneration in intrabony defects in dogs with no signs of inflammatory reaction⁸. One of the major drawbacks of β -TCP is its rapid resorption. Jensen et al.⁹ showed almost complete resorption of β -TCP, 8 weeks after filling osseous defects in minipigs.

A new biocomposite material, biphasic calcium phosphate (BCP) poly-DL-lactide-co-glycolide (PLGA) – (BCP/PLGA), in which BCP granules are coated with bioresorbable PLGA polymer, was introduced as a bone substitute by Ignjatovic et al.¹⁰. A high level of osseous regeneration was obtained when using BCP/PLGA to fill intrabony defects in 10 patients¹⁰. Rapid and strong osteoconductivity was observed after implantation of hydroxyapatite PLGA (HAp/PLGA) for repairing critical size radius defects in rabbits¹¹.

There is however no bone substitute material which provides complete regeneration of intrabony periodontal defects. Until now, there has been no study that compared BCP/PLGA with other bone substitutes for filling of intrabony defects. The aim of this study was to evaluate the clinical outcome of a biocomposite material use of BCP/PLGA and to compare it with DPBB and β -TCP in the treatment of human periodontal intrabony defects.

Methods

Materials

Aqueous calcium nitrate [$\text{Ca}(\text{NO}_3)_2$] solution was added to a solution of ammonium phosphate [$(\text{NH}_4)_3\text{PO}_4$] at 50°C over a period of 60 min, while stirring at the rate of 100 rpm. The solution was then subjected to heat treatment for 60 min at 100°C. The obtained gel was dried at room temperature and calcined at 1,100°C for 6 h. In our previous studies, we showed that the obtained calcium phosphate powder consisted of HAp and β -TCP. Based on the previously described methodology, the mass content was calculated at 80% HAp and 20% β -TCP¹². This type of calcium phosphate is called BCP and is used for the production of BCP/PLGA composite biomaterial¹². BCP powder, whose roentgenograms and microstructure were examined in our previous papers¹³, was synthesized by precipitation.

PLGA (50:50) (Sigma Chemical Company, USA) was used as a polymer component. Granules of BCP were added into completely dissolved polymer, in amounts of 80 mass%. The solution was mixed at the speed of 30 rpm, and then methanol was added. After solvent evaporation, the particles were dried at room temperature for 24 h. The resulting granules of BCP/PLGA composite biomaterial were sterilized by γ rays (25 kGy) before use.

For crystallites sizes of Hap from BCP/DLPLG the Rietveld method was used¹⁴.

Composite production via the solvent–nonsolvent procedure provides a covering of BCP with PLGA polymer^{12–15}.

Characterisations of materials

Wide angle X-ray structural (WAXS) analysis of the BCP/PLGA composite biomaterial was carried out using a Philips PW 1710 diffractometer. Microstructure characterization was carried out using a JSM 5300 scanning electron microscope. The particle size distribution of powders was measured using a Mastersizer 2000 (Malvern Instruments Ltd.) and Shirocco dispersion unit.

Patients selection and surgical procedure

The study protocol was approved by the Ethical Committee of the Faculty of Dentistry, University of Belgrade (document number 123/2). The study included 24 patients, 14 women and 10 men, suffering from severe periodontal disease. The patients included in the study signed informed consent forms. The inclusion criteria were: otherwise healthy patients (ASA I) between 18–45 years of age who were non-smokers, and had not undergone any dental treatment in the last 2 weeks. The study exclusion criteria included: nursing mothers, pregnant women, those using any contraceptive medication or methods and patients using any analgesic agents within 24 h of the treatment. In addition, every patient had bilateral, three-wall, intrabony defects in the region of the upper first and second premolar, and upper first molar, \geq than 4 mm deep. This was a randomized, split mouth study, which included three groups: the group I – study group, (open flap debridement + BCP/PLGA), and two control groups: the group II (open flap debridement + deproteinised bovine bone, DPBB), and the group III – (open flap debridement + β -TCP). The intrabony defects were located on both the mesial and distal sides of the upper premolars and first molars.

The operative procedure started after local anaesthesia consisting of 2% lidocaine with adrenaline 1: 80 000 (Xylonor®, Septodont, France) was applied. The incision was intrasulcular and full thickness mucoperiosteal flaps at both vestibular and palatal sides were raised in order to expose entire intrabony defects. All granulation tissue was removed from intrabony defects and the roots were completely scaled and planed by hand and ultrasonic instruments.

After the open flap debridement was carried out, intrabony defects on the mesiopalatal or disto-palatal side of the upper premolars on one side of the mouth were filled with DPBB (BioOss®, Geistlich, Wolhausen, Switzerland), while β -TCP (RTR®, Septodont, France) was used on the mesiopalatal or disto-palatal side of the upper first molar. During the same appointment, BCP/PLGA was applied into periodontal defects of the upper premolars and upper first molar of the opposite side of the mouth. The implanted material was firmly packed into intrabony defects with a sterile amalgam rammer. Finally, the mucoperiosteal flaps were repositioned and sutured primarily with single interdental sutures (Ethicon®, Mersilk 4-0, USA).

The plaque index (PI), bleeding index (BI), position of the cement-enamel junction (CEJ) and PPD were recorded preoperatively as well as 6 months after the operation. All the measurements were made by the same investigator using the same type of manual periodontal probe (PCP 12, Hu-Friedy, Chicago, IL, USA) with a probe tip diameter of 0.4 mm. The PI was scored as: score 0 for no plaque; score 1 for a film of plaque adhering to the free gingival margin and adjacent area of the tooth, which cannot be seen with the naked eye, but only by using a disclosing solution or probe; score 2 for moderate accumulation of deposits within the gingival pocket, on the gingival margin and/or adjacent tooth surface, which can be seen with the naked eye; and score 3 for abundant soft matter within the gingival pocket and/or on the tooth and gingival margin. The BI was also registered before the treatment and 6 months following the operation and scored as: score 0 for no bleeding; score 1 for a single discrete bleeding point; score 2 for several isolated bleeding points or a single line of blood appears; score 3 where the interdental triangle fills with blood shortly after probing; and score 4 for profuse bleeding occurring after probing with blood flowing immediately into the marginal sulcus.

One month before the operative procedure, basic periodontal therapy, which included motivation and oral hygiene instructions as well as scaling and root planning with periodontal probes, was administered. In addition, where traumatic interdental contact was present, occlusal corrections were carried out. Furthermore, all inadequate fillings were replaced at least a month before.

Antibiotic therapy (Amoksicilin®, Galenika, Beograd, Serbia) was prescribed for one week postoperatively. Detailed hygiene instructions were given to every patient.

Statistics

Statistical analysis was carried out using IBM SPSS for Windows (version 19.0). The continuous variables, such as CEJ and PPD, were shown as a mean \pm SD. On the other hand, variables such as PI and BI were presented as category variables. The significance of differences for PI and BI between baseline and 6-month data, and between the groups 6 months following the treatment, was evaluated with a χ^2 -test. The significance of differences for CEJ and PPD between baseline and the 6-month period was evaluated using the Wilcoxon test, while the Man Whitney *U*-test was used to determine differences for CEJ and PPD between groups 6 months after the treatment. The level of significance was set at $p < 0.05$.

Results

Figure 1a shows the X-ray diffraction (XRD) patterns of BCP/PLGA composite biomaterials. The most intense peaks at $2\theta = 29^\circ(2\ 1\ 0)$ and $31.8^\circ(2\ 1\ 1)$ originate from HAp and that at $2\theta = 31^\circ(0\ 2\ 10)$ from (β -TCP). The crystallites sizes of HAp from BCP/DLPLG obtained from the XRD patterns were 98 nm.

Figure 1b shows a scanning electron microscope (SEM) image of the BCP/PLGA composite obtained according to

experimental procedure. BCP granules are coated with the polymer and their average diameter is about 100 μm .

Dry powder of BCP/PLGA was analyzed with the aim of establishing particle size distribution. Figure 1c) shows the particle size distributions for BCP/PLGA powder: $d_{10} = 1.519\ \mu\text{m}$; $d_{50} = 100.973\ \mu\text{m}$ and $d_{90} = 464.050\ \mu\text{m}$. The highest and the most important present fraction (d_{50}) has particles with the diameter of 100 μm . The results of particle size distribution are in accordance with SEM studies (Figure 1.b). Only 10% of all particles (d_{10}) have a maximum diameter of 1.52 μm .




Fig. 1 – a) X-ray diffraction pattern of biphasic calcium phosphate/poly-DL-lactide-co-glycolide; b) Scanning electron microscope image of BCP/PLGA; c) Particle size distributions of BCP/PLGA.

The PI and BI were significantly lower in all the three tested groups 6 months following the operation when compared to preoperative values (Tables 1 and 2). There were no tested teeth with the BI score of 4 before the treatment or 6 months following the operation.

The results of this study also demonstrated statistically significant reduction in PPD and CEJ in all the three tested groups, 6 months following the treatment (Figure 2).

The comparison of BCP/PLGA and β -TCP, 6 months following filling of defects, showed a statistically significant re-

Table 1

Comparison of plaque index (PI) before the treatment and 6 months after the operation

Tooth/Time of record	Teeth, n (%)				Total	p (χ^2 test)
	Score 0	Score 1	Score 2	Score 3		
16 baseline	-	14 (58.3)	8 (33.3)	2 (8.3)	24 (100)	< 0.0001*
16 after BCP/ PLGA	17 (70.8)	7 (29.2)	-	-	24 (100)	
15 baseline	-	14 (58.3)	8 (33.3)	2 (8.3)	24 (100)	< 0.0001*
15 after BCP/ PLGA	17 (70.8)	7 (29.2)	-	-	24 (100)	
14 baseline	-	14 (58.3)	8 (33.3)	2 (8.3)	24 (100)	< 0.0001*
14 after BCP/ PLGA	17 (70.8)	7 (29.2)	-	-	24 (100)	
24 baseline	-	11 (45.8)	11 (45.8)	2 (8.3)	24 (100)	< 0.0001*
24 after DPBB	18 (75.0)	6 (25.0)	-	-	24 (100)	
25 baseline	-	11 (45.8)	11 (45.8)	2 (8.3)	24 (100)	< 0.0001*
25 after DPBB	18 (75.0)	6 (25.0)	-	-	24 (100)	
26 baseline	-	11 (45.8)	11 (45.8)	2 (8.3)	24 (100)	< 0.0001*
26 after β -TCP	18 (75.0)	6 (25.0)	-	-	24 (100)	

*Statistically significant difference; BCP/PLGA – biphasic calcium phosphate/poly-DL-lactide-co-glycolide.

DPBB – deproteinised bovine bone; β -TCP – β -tricalcium phosphate.

Score: 0 – no plaque; 1 – a film of plaque adhering to the free gingival margin and adjacent area of the tooth, seen only by using a disclosing solution or probe; 2 – moderate accumulation of deposits within the gingival pocket, on the gingival margin and/or adjacent tooth surface seen with the naked eye; 3 – abundant soft matter within gingival pocket and/or on the tooth and gingival margin.

Table 2

Comparison of bleeding index (BI) before the treatment and 6 months after the operation

Tooth/Time of record	Teeth, n (%)				Total	p (χ^2 test)
	Score 0	Score 1	Score 2	Score 3		
16 baseline	1 (4.2)	9 (37.5)	7 (29.2)	7 (29.2)	24 (100)	< 0.0001*
16 after BCP/ PLGA	10 (41.7)	14 (58.3)	-	-	24 (100)	
15 baseline	1 (4.2)	7 (29.2)	11 (45.8)	5 (20.8)	24 (100)	< 0.0001*
15 after BCP/ PLGA	10 (41.7)	13 (54.2)	1 (4.2)	-	24 (100)	
14 baseline	1 (4.2)	9 (37.5)	9 (37.5)	5 (20.8)	24 (100)	< 0.0001*
14 after BCP/ PLGA	12 (50.0)	12 (50.0)	-	-	24 (100)	
24 baseline	1 (4.2)	8 (33.3)	10 (41.7)	5 (20.8)	24 (100)	< 0.0001*
24 after DPBB	13 (54.2)	11 (45.8)	-	-	24 (100)	
25 baseline	1 (4.2)	6 (25.0)	10 (41.7)	7 (29.2)	24 (100)	< 0.0001*
25 after DPBB	12 (50.0)	12 (50.0)	-	-	24 (100)	
26 baseline	1 (4.2)	8 (33.3)	9 (37.5)	6 (25.0)	24 (100)	< 0.0001*
26 after β -TCP	11 (45.8)	13 (54.2)	-	-	24 (100)	

For abbreviations see under Table 1;

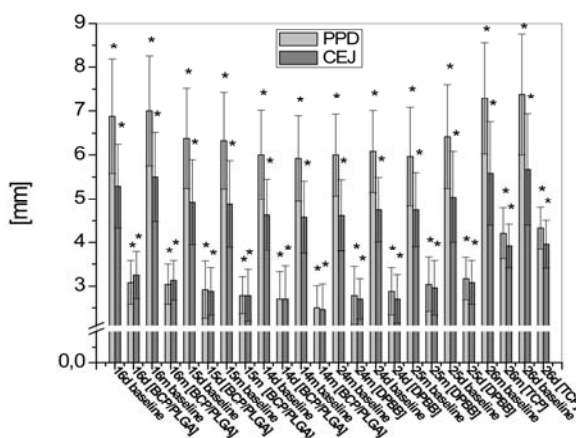


Fig. 2 – Reduction in periodontal pocket depth (PPD) and the cemento-enamel junction (CEJ) 6 months following the operation (d – distal side; m – mesial side; * – statistically significant; $p < 0.0001$). BCP/PLGA – biphasic calcium phosphate/poly-DL-lactide-co-glycolide.

duction of PPD and CEJ in the group with BCP/PLGA, when compared to the β -TCP group (Figure 3). The reduction in PPD and CEJ was similar in groups treated with BCP/PLGA and DPBB (Figure 3).

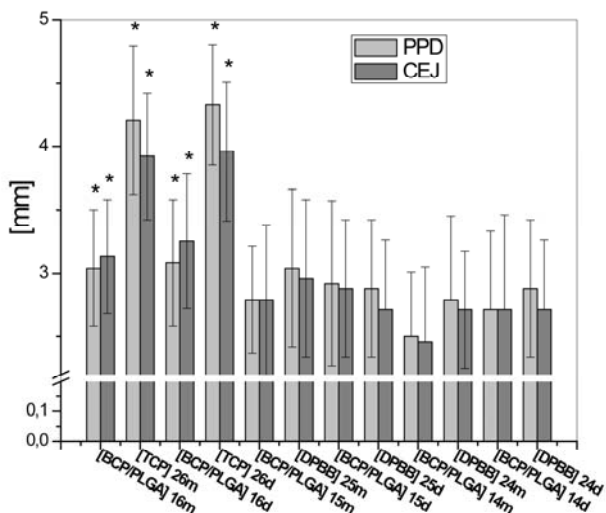


Fig. 3 – Comparison of periodontal pocket depth and level of cemento-enamel junction six months following the operation between tested groups (d – distal side; m – mesial side; * – statistically significant; $p < 0.0001$). BCP/PLGA – biphasic calcium phosphate/poly-DL-lactide-co-glycolide. TCP – beta-tricalcium phosphate; DPBB – deproteinised bovine bone.

Figure 4 shows one of 24 cases in this study. Figure 4a shows the intrabony defect on the mesial side of the upper first molar on X-ray film before the operation. Figure 4b shows the clinical appearance of the intrabony defect before the treatment and Figure 4c demonstrates the intraoperative view of the same defect. The defect was filled with BCP/PLGA powder (Figure 4d). After reconstruction, the mucoperiosteal flap was sutured with silk (Figure 4e). In the retroalveolar X-ray image, made 6 months after intervention, the new-formed bone in the defect on the mesial side of upper first molar is obvious (Figure 4f).

Discussion

The results of this study indicate that BCP/PLGA was more successful than β -TCP in periodontal intrabony defects filling when assessed six months following the treatment. In comparison to DPBB, the results obtained with BCP/PLGA were slightly better in terms of PPD and CEJ level reduction, but did not differ statistically. The improvement in PPD and CEJ obtained with the nanocrystalline bone substitute BCP/PLGA, could possibly be explained by its structure. XRD patterns show no peaks for PLGA polymer because this polymer is amorphous, which is in accordance with the XRD studies of PLGA of our previous research^{13, 15}. BCP coated with polylactide polymer enables protein adhesion prior to cell adhesion to the proteins on biomaterial^{16, 17}. It was shown that free surface energy decreased by adding BCP to the polymer component, and, consequently, allowed better interaction with surrounding cells¹⁸. Likewise, the bet-

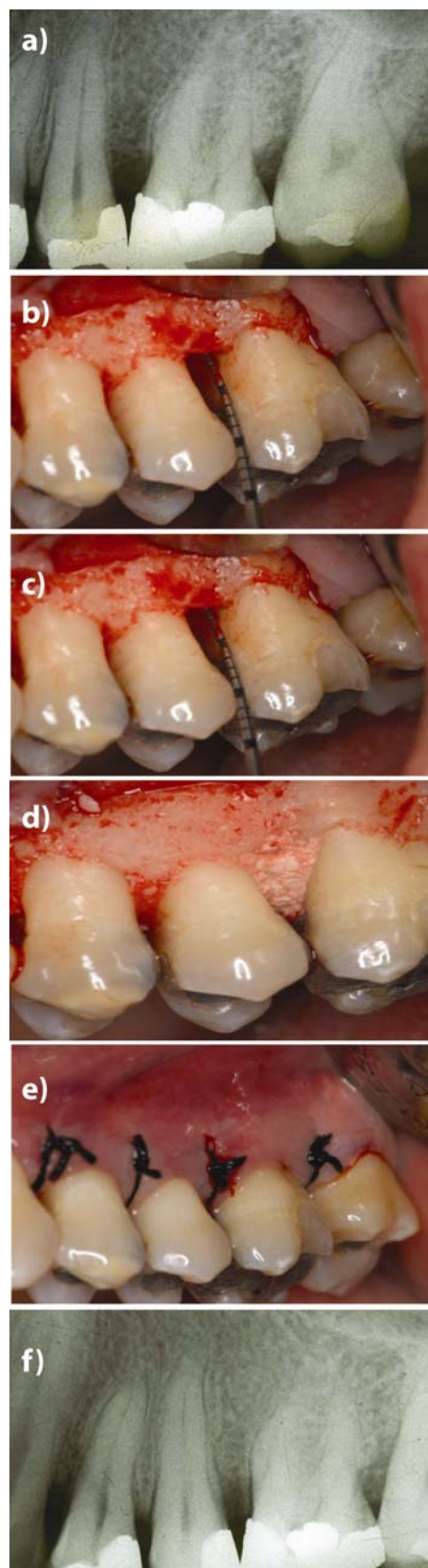


Fig. 4 – Filling the intrabony defect with biphasic calcium phosphate/poly-DL-lactide-co-glycolide (BCP/PLGA): a) X-ray image before the treatment; b) Clinical appearance of intrabony defect; c) Intraoperative view of intrabony defect; d) Applied BCP/PLGA; e) Sutured reconstruction; f) X-ray image after 6 months.

ter results realised with BCP/PLGA in comparison to β -TCP could be explained by the preventive effect of the polymer component against removal by the immune system¹⁹. In addition, it was already shown that BCP/PLGA enhanced osteoblast differentiation and production of alkaline phosphatase as a sign of its activity¹².

Implantation of β -TCP into intrabony defects demonstrated a significant reduction in PPD and CEJ after 6 months when compared to baseline levels. The results of our study are consistent with those of Saini et al.²⁰ who have demonstrated significant clinical improvement in the treatment of human intrabony defects filled with β -TCP. Neamat et al.⁸ in the study on dogs' periodontal intrabony defects showed that β -TCP promoted osteogenesis and bone regeneration. On the other hand, our results obtained with β -TCP were not as positive as those achieved with BCP/PLGA. A possible explanation could be β -TCP's rapid resorption. Due to the initial progressive degradation phase and the accumulation of phagocytising cells accompanying degradation of the material, the implant particles may not integrate with the bone²¹.

Our results showed that PPD and CEJ were similarly reduced after filling intrabony defects with DPBB and BCP/PLGA. This is in accordance with the study of Kim and Kim²² who presented similar bone formation after using DPBB and HA/PLGA in critical size rat calvarial defects. The studies with Biooss[®] as a bone substitute showed intrabony defect filling and reduction of PPD⁶, as well as osseous regeneration around dental implants⁴. Cordaro et al.²³ showed that bone-to-graft contact was greater with DPBB compared to β -TCP (48% vs 34% respectively), and, according to this finding, it can be concluded that DPBB has the higher osteoconductivity. Although we did not directly compare DPBB and β -TCP, good results obtained with DPBB as well as with BCP/PLGA may be explained by higher osteoconductivity than that achieved by β -TCP. Resorption of DPBB particles still remains a controversial issue. DPBB seems to be inert and stable over time and to remain sequestered in bone, marrow, and fibrovascular tissue (for up to 10 years)²⁴. Schlegel and Donath²⁵ showed histological

signs of DPBB particles 6 years following bone defects fill. On the other hand, Thaller et al.²⁶ demonstrated resorption of DPBB, which underwent normal physiologic bone remodelling in the rabbit calvarial model.

We found clinical and statistical improvement in terms of PPD and CEJ reduction in all the three groups 6 months following the operation. These results, obtained with each of the bone substitutes, are likely to be a consequence of the three-wall anatomy of intra-bony defects. The findings could be explained by the rich blood supply and growth factors deriving from each of three bony walls. This is in accordance with the study of Ellegaard and L  e²⁷, who reported that defect resolution was greater in a three-wall defect site than that in two-wall defects.

It is interesting to note that PI and BI showed statistically significant improvement 6 months following implantation of each bone substitute. The explanation for this may be better oral hygiene, closely connected with the reduction of PPD and CEJ.

Conclusion

The results of the present study indicate that both nanocrystalline biphasic calcium phosphate/poly-DL-lactide-co-glycolide and deproteinised bovine bone grafting biomaterials have clinically and statistically significant improvement in terms of cemento-enamel junction gain and periodontal pocket depth reduction when used for the treatment of intraosseous defects. In addition, it should be emphasised that (BCP/PLGA) demonstrated clinically and statistically significant reduction of periodontal pocket depth and cemento-enamel junction levels when compared to β -tricalcium phosphate 6 months following the treatment.

Acknowledgment

The authors sincerely thank to Prof. Ljubomir Todorovi c for his helpful suggestions in preparing the manuscript. This work has been funded by the Serbian Ministry of Education Science and Technological Development through the Grants No. 175021 and III45004.

R E F E R E N C E S

1. Nasr HF, Aichelmann-Reidy ME, Yukna RA. Bone and bone substitutes. *Periodontology* 2000; 19(1): 74–86.
2. Hanes PJ. Bone replacement grafts for the treatment of periodontal intrabony defects. *Oral Maxillofac Surg Clin North Am* 2007; 19(4): 499–512.
3. Baldini N, de Sanctis M, Ferrari M. Deproteinised bovine bone in periodontal and implant surgery. *Dent Mater* 2007; 27(1): 61–70.
4. Hammerle CH, Chiantella GC, Karring T, Lang NP. The effect of a deproteinized bovine bone mineral on bone regeneration around titanium dental implants. *Clin Oral Impl Res* 1998; 9(3): 151–62.
5. Tapety FI, Amizuka N, Uoshima K, Nomura S, Maeda T. A histological evaluation of the involvement of Bio-Oss in osteoblastic differentiation and matrix synthesis. *Clin Oral Implants Res* 2004; 15(3): 315–24.
6. Richardson CR, Mellonig JT, Brunsvold MA, McDonnell HT, Cochran DL. Clinical evaluation of Bio-Oss: a bovine-derived xenograft for the treatment of periodontal osseous defects in humans. *J Clin Periodontol* 1999; 26(7): 421–8.
7. Scabbia A, Trombelli L. A comparative study on the use of a HA/collagen/chondroitin sulphate biomaterial (Biostite) and a bovine-derived HA xenograft (Bio-Oss) in the treatment of deep intra-osseous defects. *J Clin Periodontol* 2004; 31(5): 348–55.
8. Neamat A, Gawish A, Gamal-Eldeen AM. beta-Tricalcium phosphate promotes cell proliferation, osteogenesis and bone regeneration in intrabony defects in dogs. *Arch Oral Biol* 2009; 54(12): 1083–90.
9. Jensen SS, Brogini N, H jrt ng-Hansen E, Schenk R, Buser D. Bone healing and graft resorption of autograft, anorganic bovine bone and beta-tricalcium phosphate. A histologic and histomorphometric study in the mandibles of minipigs. *Clin Oral Implants Res* 2006; 17(3): 237–43.
10. Ignjatovi c N, Ajdukovi c Z, Uskokovi c D. New biocomposite [biphasic calcium phosphate/ poly-DL-lactide-co-glycolide/biostimulative

- agent] filler for reconstruction of bone tissue changed by osteoporosis. *J Mater Sci Mater Med* 2005; 16(7): 621–6.
11. Zhang P, Hong Z, Yu T, Chen X, Jing X. In vivo mineralization and osteogenesis of nanocomposite scaffold of poly(lactide-co-glycolide) and hydroxyapatite surface-grafted with poly(L-lactide). *Biomaterials* 2009; 30(1): 58–70.
 12. Ignjatović NL, Liu CZ, Czernuszka JT, Uskoković DP. Micro- and nano-injectable composite biomaterials containing calcium phosphate coated with poly(DL-lactide-co-glycolide). *Acta Biomater* 2007; 3(6): 927–35.
 13. Ignjatović N, Suljovrujić E, Budinski-Simendić J, Krakovsky I, Uskoković D. Evaluation of Hot-Pressed Hydroxyapatite/Poly-L-lactide Composite Biomaterial Characteristics. *J Biomed Mater Res B Appl Biomater* 2004; 71(2): 284–94.
 14. Ignjatović N, Uskoković D. Biodegradable composites based on nano-crystalline calcium phosphate and bioresorbable polymers. *Advanced Appl Cer* 2008; 107(3): 142–7.
 15. Ignjatović N, Uskoković V, Ajduković Z, Uskoković D. Multifunctional hydroxyapatite and poly (D, L-lactide-co-glycolide) nanoparticles for the local delivery of cholecalciferol. *Mater Sci Eng C Mater Biol Appl* 2013; 33(2): 943–50.
 16. Ignjatović N, Ninkov P, Kojić V, Bokurov M, Srdić V, Krnojelac D, et al. Cytotoxicity and fibroblast properties during in vitro test of biphasic calcium phosphate/poly-dl-lactide-co-glycolide biocomposites and different phosphate materials. *Microsc Res Tech* 2006; 69(12): 976–82.
 17. Unger RE, Huang Q, Peters K, Protzer D, Paul D, Kirkpatrick CJ. Growth of human cells on polyethersulfone (PES) hollow fiber membranes. *Biomaterials* 2005; 26(14): 1877–84.
 18. Ignjatović N, Nastović A, Latinović V, Onjia A, Miljković M, Konstantinović V. Preparation and properties of polymeric and composite bioresorbable barrier membranes. *Mater Sci Forum* 2004; 453–4: 537–42. (Serbian)
 19. Vonarbourg A, Passirani C, Saulnier P, Benoit J. Parameters influencing the stealthiness of colloidal drug delivery systems. *Biomaterials* 2006; 27(24): 4356–73.
 20. Saini N, Sikri P, Gupta H. Evaluation of the relative efficacy of autologous platelet-rich plasma in combination with β -tricalcium phosphate alloplast versus an alloplast alone in the treatment of human periodontal infrabony defects: a clinical and radiological study. *Indian J Dent Res* 2011; 22(1): 107–15.
 21. Merten HA, Wiltfang J, Grohmann U, Hoenig JF. Intraindividual comparative animal study of alpha- and beta-tricalcium phosphate degradation in conjunction with simultaneous insertion of dental implants. *J Craniofac Surg* 2001; 12(1): 59–68.
 22. Kim SS, Kim BS. Comparison of osteogenic potential between apatite-coated poly(lactide-co-glycolide)/hydroxyapatite particulates and Bio-Oss®. *Dent Mater J* 2008; 27(3): 368–75.
 23. Cordaro L, Bosshardt DD, Palattella P, Rao W, Serino G, Chiapasco M. Maxillary sinus grafting with Bio-Oss or Straumann Bone Ceramic: histomorphometric results from a randomized controlled multicenter clinical trial. *Clin Oral Implants Res* 2008; 19(8): 796–803.
 24. Sartori S, Silvestri M, Forni F, Icaro Comaglia A, Tesi P, Cattaneo V. Ten-year follow-up in a maxillary sinus augmentation using anorganic bovine bone (Bio-Oss). A case report with histomorphometric evaluation. *Clin Oral Implants Res* 2003; 14(3): 369–72.
 25. Schlegel AK, Donath K. BIO-OSS - a resorbable bone substitute. *J Long Term Eff Med Implants* 1998; 8(3–4): 201–9.
 26. Thaller SR, Hoyt J, Dart A, Borjeson K, Tesluk H. Repair of experimental calvarial defects with Bio-Oss particles and collagen sponges in a rabbit model. *J Craniofac Surg* 1994; 5(4): 242–6.
 27. Ellegaard B, Løe H. New attachment of periodontal tissues after treatment of intrabony lesions. *J Periodontol* 1971; 42(10): 648–52.

Received on May 28, 2014.

Accepted on July 4, 2014.

Online First July, 2015.