



Posterior reversible encephalopathy syndrome – A case report

Sindrom posteriorne reverzibilne encefalopatije

Dejan Kostić*, Biljana Brkić-Georgievski†, Aleksandar Jovanovski*, Smiljana Kostić‡, Dražen Ivetić§, Leposava Sekulović*||

*Institute of Radiology, †Clinic for Neurology, §Clinic for Neurosurgery, Military Medical Academy, Belgrade, Serbia; ‡Special Hospital for Cerebrovascular Diseases „Sveti Sava“, Belgrade, Serbia; ||Faculty of Medicine of the Military Medical Academy, University of Defence, Belgrade, Serbia

Abstract

Introduction. Posterior reversible encephalopathy syndrome (PRES) is characterized by the following symptoms: seizures, impaired consciousness and/or vision, vomiting, nausea, and focal neurological signs. Diagnostic imaging includes examination by magnetic resonance (MR) and computed tomography (CT), where brain edema is visualized bilaterally and symmetrically, predominantly posteriorly, parietally, and occipitally. **Case report.** We presented a 73-year-old patient with the years-long medical history of hypertension and renal insufficiency, who developed PRES with the symptomatology of the rear cranium. CT and MR verified changes in the white matter involving all lobes on both sides of the brain. After a two-week treatment (antihypertensive, hypolipemic and rehydration therapy) clinical improvement with no complications occurred, with complete resolution of changes in the white matter observed on CT and MR. **Conclusion.** PRES is a reversible syndrome in which the symptoms withdraw after several days to several weeks if early diagnosis is made and appropriate treatment started without delay.

Key words:
brain diseases; syndrome; diagnosis; treatment outcome.

Apstrakt

Uvod. Sindrom posteriorne reverzibilne encefalopatije (PRES) karakterišu sledeći simptomi: epi napadi, poremećaji svesti i/ili vida, povraćanje, mučnina i fokalni neurološki znaci. Dijagnostičko snimanje obuhvata pregled magnetnom rezonancijom (MR) i kompjuterizovanom tomografijom (CT) gde se moždani edem vizuelizuje bilateralno i simetrično, preovlađuje posteriorno, parijetalno i okcipitalno. **Prikaz bolesnika.** Prikazali smo bolesnika starog 73 godine, dugogodišnjeg hipertoničara i bubrežnog bolesnika kod koga se razvio PRES sa simptomatologijom zadnje lobanjaske jame i verifikovanim promenama moždane bele mase na CT i MR, obostrano na svim režnjevima mozga. Nakon dve nedelje lečenja (antihipertenzivi, hipolipemici i rehidraciona terapija) nastupilo je kliničko poboljšanje bez ikakvih komplikacija i sa kompletnom rezolucijom promena bele moždane mase viđenim na CT i MR. **Zaključak.** PRES je reverzibilni sindrom čiji simptomi se povlače za nekoliko dana do nekoliko nedelja, ukoliko se rano postavi dijagnoza i odgovarajuće lečenje počne bez odlaganja.

Ključne reči:
mozak, bolesti; sindrom; dijagnoza; lečenje, ishod.

Introduction

Posterior reversible encephalopathy syndrome (PRES) is characterized by the following symptoms: epileptic seizures, consciousness impairment, visual abnormalities, nausea, vomiting and focal neurological signs. It was first described by Hinchey et al.¹ in 1996. based on the study of 15 cases. Since then this syndrome has been also designated by reversible posterior leukoencephalopathy syndrome, reversible posterior cerebral edema syndrome and reversible occipital parietal encephalopathy²⁻⁵.

Studies have shown that various conditions can lead to development of PRES, hypertension, autoimmune diseases, toxic agents, sepsis, preeclampsia/eclampsia, kidney diseases being among them^{1,6}. Regardless to this heterogeneity main pathophysiological mechanism which leads to development of this syndrome is cerebral vasogenic edema which occurs as a result of abnormality in blood flow through the brain – cerebral blood flow (CBF)⁷.

Diagnostical imaging includes magnetic resonance imaging (MR) and, less commonly, computed tomography (CT), where cerebral edema is visualized bilaterally and symmetrically

predominantly in posterior parietally and occipitally, but frontal and temporal lobes can also be affected, as well as basal ganglia, brainstem and cerebellum. Also, alongside with the white matter, cortical gray matter can be affected as well ⁸.

The diagnosis of PRES is complicated, since CT results are often normal or non-specific, and MR scanners not available in many centers. Standard MR sequences, which include T1-weighted images (T1W), T2-weighted images (T2W), fluid attenuated inversion recovery (FLAIR) and diffusion-weighted imaging (DWI) with apparent diffusion coefficient (ADC) map, as well as contrast T1W, are sufficient for the diagnosis.

The treatment should primarily consist of correction of the underlying causes which led to neurological symptomatology, and then symptomatic measures should be taken. Some patients may develop severe manifestations of PRES, such as coma or status epilepticus, which require intensive care unit (ICU) admission ^{9,10}.

PRES is a reversible syndrome, but in a small number of patients neurological deficit is permanent.

Death occurs in up to 15% of cases due to acute hemorrhage and ischemia ^{7,11-14}.

Case report

A 73-year-old patient was complaining of headache, instability while walking and loss of balance which lasted for a few days. The patient had a history of hypertension and chronic renal insufficiency. Arterial blood pressure reached 160/90 mmHg. Clinical presentation at admittance was dominated by symptomatology of posterior fossa with discreet right faciobrachial hemiparesis. Initially, CT scanning without application of contrast was performed showing the presence of both-sided hypodense zones, frontally more

prominent on the left as well as parietally right subcortically, which resembled mostly vasogenic edema (Figure 1).

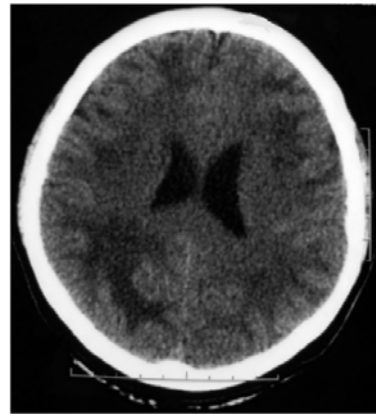


Fig. 1 – Native computed tomography (CT) scan showing hypodense zones on both sides of the frontal and parietal lobe, more pronounced on the right.

After CT, MR scanning was also performed in T1W, T2W, FLAIR, T2*, DWI with ADC map, as well as postcontrast T1W and 3D T1 FSPGR.

MR spectroscopy using 2D multivoxel SE 144 and single voxel SE 144 and SE 35 sequences with positioning of the volume of interest occipitoparietally was also performed.

This scanning showed cortico-subcortical temporopolar on both sides, parieto-occipital and posterior parietal both sidedly more dominant on the right, pachy, unsharply bordered, partly confluent lesions hyperintense in T2W and FLAIR sequence with mild compressive effect on occipital horn of the right lateral lobe, without postcontrastive enhancement of signal intensity (Figure 2).

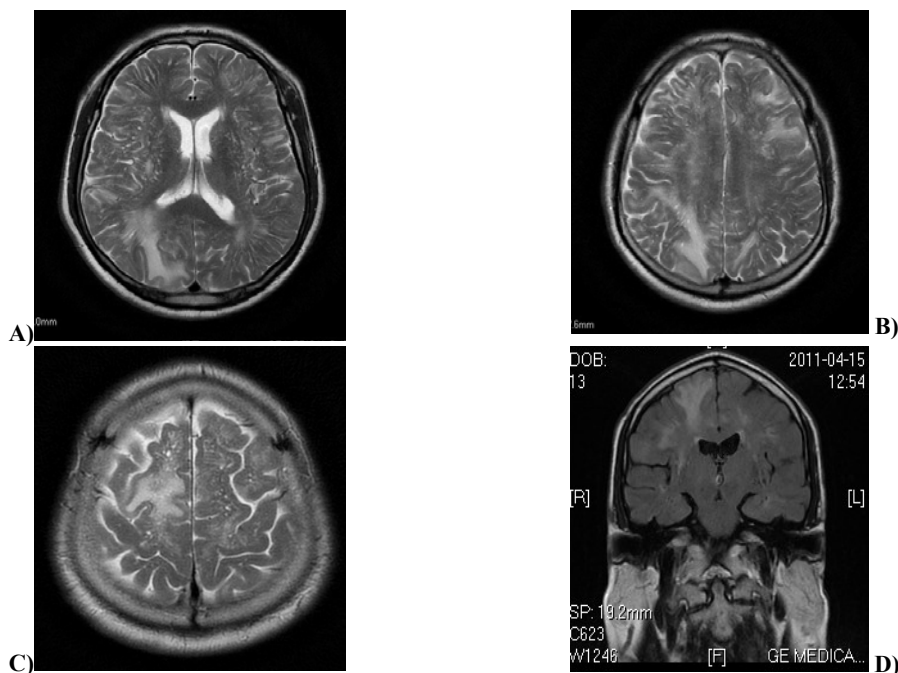


Fig. 2 – A) T2W axial tomogram showing the zones of vasogenic edema of cortical/subcortical localization in the parietal lobes, more pronounced on the right; B) T2W axial tomogram showing the asymmetric changes frontally on the left, parietally bilaterally, more pronounced on the right; C) T2W axial tomogram showing the changes frontally on the right; D) Coronal T2W axial tomogram showing vasogenic edema bilaterally frontally, pronounced on the right.

There were no signs of diffusion restriction. In DWI sequence occipitoparietally on the right there were no changes in signal intensity, but on ADC map hypointensity of the signal was observed, implicating the existence of vasogenic edema.

Based on the CT and MR scanning results the patient was referred to MR spectroscopy. Using 2D multivoxel spectroscopy the obtained spectres showed normal or slightly higher values of choline for the area in question (Cho/Cr), and NAA was slightly lower. By single voxel spectroscopy spectres of low absolute concentrations were obtained, ratio Cho/Cr did not significantly deviate from normal values for the area in question. NAA was lower. Resonance lines of lipides and lactates were not noticed. Diffusion Tensor Imaging (DTI) revealed that in the area of lesion occipitoparietally on the right fractional anizotropy was lower.

After diagnosing the patient was regularly treated with antihypertensive, antilypemic and rehydration therapy and was discharged two weeks later with arterial tension 140/80 mmHg and normalized neurological findings.

Control MR scanning, two months after the initial one, showed complete regression of T2W and FLAIR hyperintense changes which had previously affected cortex and subcortical white matter (Figure 3).

syndrome: acute hypertension, renal function disorder, immunosuppressive therapies being some of them¹. Other possible causes are eclampsia, transplantation, chemotherapy¹⁵, systemic infection, shock¹⁶ and insect bites^{17,18}.

Until recently it was thought that PRES typically affects the white matter, simetrically, predominantly in occipital and posterior parietal areas. Sporadically, changes were described in frontal and temporal lobes, basal ganglia, brain stem and cerebellum, as well as in cortical grey matter⁶.

Recent cohort studies showed that changes are asymmetric in 3–15% of cases, that occipital lobes are affected in 99%, and parietal lobes in 67% to 99% of cases. Changes are less often detected in frontal (68–89%) and temporal (40–83%)^{13,16,19,20} lobes of cerebral parenchyma. The brainstem is affected in 13–58%, cerebellum in 30–58%, and basal ganglia in 12–34% of cases^{16,19,20}. Till now changes are least often detected in the grey matter, i.e. in 10–44% of cases^{11,16,19,20}. In the presented case the changes were asymmetrical and affecting frontal, temporal, parietal and occipital lobes, cortical grey matter, as well as subcortical and deep cerebellar white matter.

The main pathophysiological mechanism which leads to this syndrome is cerebral vasogenic edema. Some authors think that the occurrence of edema is the consequence of a

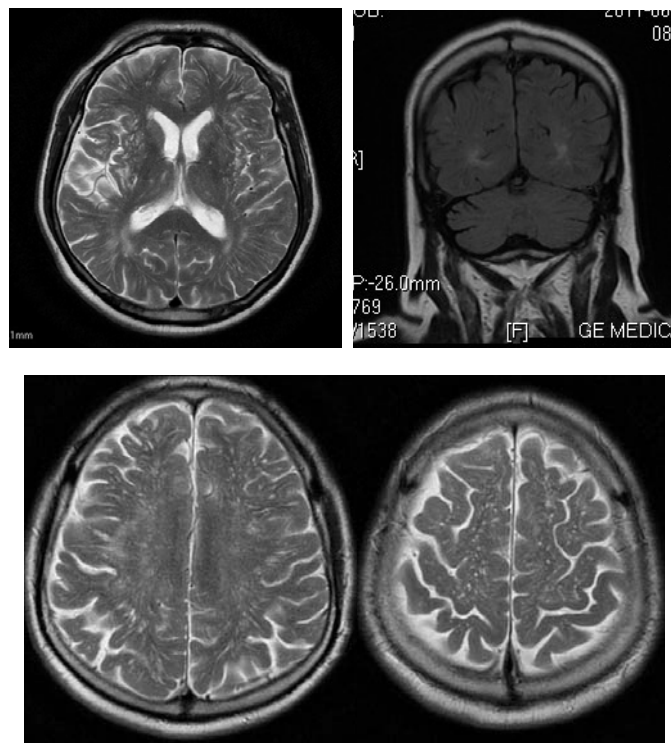


Fig. 3 – Control magnetic resonance imaging (MRI) after two month. T2W axial tomogram and coronal T2W tomogram showed almost complete regression of the lesion.

Discussion

PRES has been reported in patients aged 4 to 90 years, although most cases occur in young to middle-aged adults. Mechanical ventilation is required in 35% to 40% of patients^{12,13}. The average hospital stay is 20 days, and the mortality rate up to 15%^{12,13}. Numerous conditions may lead to the

disorder in cerebral autoregulation of blood flow through the brain. Other authors think that it is caused by endothelium dysfunction with cerebral hypoperfusion⁷.

CT scan is often normal or non-specific, as in our case. Topographic regions suggest the diagnosis of PRES²⁰.

T2W sequence shows lesions of higher intensity signal, which indicates the existence of edema, and T1W shows low

intensity signal. Changes in PRES are best seen in FLAIR sequence, as hyperintense zones cortically and/or subcortically⁸ and such changes are more often frontally localized compared to the posterior presentation using this technique²¹.

Signal intensity on the DWI sequence is normal, but it is higher on ADC²².

Fractional isotrophy shows zones of decrease, which indicates a mild damage of brain paths which can be reversible and it is in accordance with a mild decrease of the values of N-acetylaspartate (NAA) obtained by MR spectroscopy^{23,24}.

MR spectroscopy is not superior to conventional MR sequences, but it helps us to rule out other etiology of changes. Signal intensity increase after application of contrast agents is seen in about one half of cases¹⁹.

In recent years susceptibility-weighted imaging (SWI) is used for detecting microhemorrhages. This examination shows a higher occurrence rate of microhemorrhage in this syndrome which is associated with vasculopathy²⁵.

All those characteristics of lesions were also seen in our case.

Many conditions may resemble PRES. The differential diagnosis of findings obtained by the examination of the brain using MR imaging in patients with abnormalities of cerebellar white matter includes the following^{5,26}: acute disseminated encephalomyelitis (ADEM) in which, unlike the PRES, lesions in T1 can be hypo- to isointense, in DWI the signal is without changes, and on ADC map an increase of signal intensity is seen, changes being contrast uptaken²⁷; in progressive multifocal leukoencephalopathy (PML) in DWI new and active lesions show hyperintensity of signal, the old ones hypointensity, while in ADC map new and active lesions are hypointense and the old ones are hyperintense²⁸; in cerebral autosomal dominant arteriopathy with subcortical infarcts and leukoencephalopathy (CADASIL) in DWI and ADC sequences the restriction of diffusion always occurs,

and the changes after *iv* application of contrast do not show signs of signal hyperintensity, changes symmetrically affect basal ganglia and white matter widening the perivascular space²⁹; in acute ischemia a restriction of diffusion does exist (signal hyperintensity in DWI, signal hypointensity in ADC map) without contrast increase of signal intensity³⁰; in mitochondrial encephalomyopathy, lactic acidosis, and stroke-like (MELAS) episodes signal hyperintensity occurs in T1 W sequence, in T1 W and T2 FLAIR it is hypointense, and in DWI iso- or hypointense. In ADC it is iso or hyperintense. The increase in signal intensity may occur post-contrastively³¹; in CNS vasculitis lesions show a decrease in signal intensity in T1 W, an increase in signal intensity in T1 W and FLAIR, and in DWI and ADC. Signal hyperintensity occurs post-contrastively³²; in creutzfeldt – jakob disease the changes are isointense in T1 W, hyperintense in T2 W, T2 FLAIR and DWI, and in ADC they are hypointense³³.

Conclusion

Posterior reversible encephalopathy syndrome has no specific clinical presentation and mortality rate is up to 15% of cases due to acute hemorrhage and ischemia. Studies show that magnetic resonance scanning is crucial for diagnosing, monitoring the course and assessing the treatment effectiveness of this syndrome.

Although the name of the syndrome implicates that posterior cerebral circulation is affected, the changes are often localized in frontal and temporal lobes, as noted in our case study, as well as in the structures of brain stem and cerebellum.

Because of the complications (hemorrhage, ischemia), as well as the lethal outcome, the acronym denoting this clinicoradiological entity has been challenged.

We consider that a suggestion to change the term into potentially reversible encephalopathy syndrome should be accepted.

R E F E R E N C E S

1. Hinchey J, Chaves C, Appignani B, Breen J, Pao L, Wang A, et al. A reversible posterior leukoencephalopathy syndrome. *N Engl J Med* 1996; 334(8): 494–500.
2. Fugate JE, Claassen DO, Cloft HJ, Kallmes DF, Kozak OS, Rabinstein AA. Posterior reversible encephalopathy syndrome: associated clinical and radiologic findings. *Mayo Clin Proc* 2010; 85(5): 427–32.
3. Bartynski WS. Posterior reversible encephalopathy syndrome, part 1: fundamental imaging and clinical features. *AJNR Am J Neuroradiol* 2008; 29(6): 1036–42.
4. Bartynski WS. Posterior reversible encephalopathy syndrome, part 2: controversies surrounding pathophysiology of vasogenic edema. *AJNR Am J Neuroradiol* 2008; 29(6): 1043–9.
5. Legriel S, Pico F, Azoulay E. Understanding posterior reversible encephalopathy syndrome. In: Vincent JL, editor. *Annual Update in Intensive Care and Emergency Medicine*. Berlin: Springer; 2011. p. 631–53.
6. Schwartz RB, Jones KM, Kalina P, Bajakian RL, Mantello MT, Garada B, et al. Hypertensive encephalopathy: findings on CT, MR imaging, and SPECT imaging in 14 cases. *AJR Am J Roentgenol* 1992; 159(2): 379–83.
7. Schwartz RB, Bravo SM, Klufas RA, Hsu L, Barnes PD, Robson CD, et al. Cyclosporine neurotoxicity and its relationship to hypertensive encephalopathy: CT and MR findings in 16 cases. *AJR Am J Roentgenol* 1995; 165(3): 627–31.
8. Casey SO, Sampaio RC, Michel E, Trumit CL. Posterior reversible encephalopathy syndrome: utility of fluid-attenuated inversion recovery MR imaging in the detection of cortical and subcortical lesions. *AJNR Am J Neuroradiol* 2000; 21(7): 1199–206.
9. Servillo G, Striano P, Striano S, Tortora F, Boccella P, De RE, et al. Posterior reversible encephalopathy syndrome (PRES) in critically ill obstetric patients. *Intensive Care Med* 2003; 29(12): 2323–6.
10. Kozak OS, Wijidicks EF, Manno EM, Miley JT, Rabinstein AA. Status epilepticus as initial manifestation of posterior reversible encephalopathy syndrome. *Neurology* 2007; 69(9): 894–7.
11. Yoon SD, Cho BM, Oh SM, Park SH, Jang IB, Lee JY. Clinical and radiological spectrum of posterior reversible encephalopa-

- thy syndrome. *J Cerebrovasc Endovasc Neurosurg.* 2013; 15(3): 206–13.
12. Lee VH, Wijidicks EF, Manno EM, Rabinstein AA. Clinical spectrum of reversible posterior leukoencephalopathy syndrome. *Arch Neurol* 2008; 65(2): 205–10.
 13. Burnett MM, Hess CP, Roberts JP, Bass NM, Douglas VC, Josephson SA. Presentation of reversible posterior leukoencephalopathy syndrome in patients on calcineurin inhibitors. *Clin Neurol Neurosurg* 2010; 112(10): 886–91.
 14. Legriel S, Schraub O, Azoulay E, Hantson P, Magalhaes E, Coquet I, et al. Determinants of recovery from severe posterior reversible encephalopathy syndrome. *PLoS One* 2012; 7(9): e44534.
 15. Marrone LC, Marrone BF, de la Puerta RJ, Gadonski G, da Costa JC. Gemcitabine monotherapy associated with posterior reversible encephalopathy syndrome. *Case Rep Oncol* 2011; 4(1): 82–7.
 16. Bartynski WS, Boardman JF, Zeigler ZR, Shaddock RK, Lister J. Posterior reversible encephalopathy syndrome in infection, sepsis, and shock. *AJNR Am J Neuroradiol* 2006; 27(10): 2179–90.
 17. Lob HH, Tan CH. Acute renal failure and posterior reversible encephalopathy syndrome following multiple wasp stings: a case report. *Med J Malaysia* 2012; 67(1): 133–5.
 18. Luiz C, Porcello M. Posterior Reversible Encephalopathy Syndrome Following a Scorpion Sting. *J Neuroimaging* 2013; 23: 535–6.
 19. Bartynski WS, Boardman JF, Zeigler ZR, Shaddock RK, Lister J. Posterior reversible encephalopathy syndrome in infection, sepsis, and shock. *AJNR Am J Neuroradiol* 2006; 27(10): 2179–90.
 20. McKinney AM, Short J, Truwit CL, McKinney ZJ, Kozak OS, SantaCruz KS, et al. Posterior reversible encephalopathy syndrome: incidence of atypical regions of involvement and imaging findings. *AJR Am J Roentgenol* 2007; 189(4): 904–12.
 21. Covarrubias DJ, Luetmer PH, Campeau NG. Posterior reversible encephalopathy syndrome: prognostic utility of quantitative diffusion-weighted MR images. *AJNR Am J Neuroradiol* 2002; 23(6): 1038–48.
 22. Kastrup O, Schlamann M, Moeninghoff C, Forsting M, Goerliche S. Posterior Reversible Encephalopathy Syndrome: The Spectrum of MR Imaging Patterns. *Clin Neuroradiol* 2014; (In Press)
 23. Lee S, Kim SH, Lee SH, Baek HJ, Shon HS, Kim SS. Serial MR spectroscopy in relapsing reversible posterior leukoencephalopathy syndrome. *Neurologist* 2009; 15(6): 338–41.
 24. Alexander AL, Lee JE, Lazar M, Field AS. Diffusion tensor imaging of the brain. *Neurotherapeutics* 2007; 4(3): 316–29.
 25. Sonnerille R, Klein IF, Wolff M. Update on investigation and management of postinfectious encephalitis. *Curr Opin Neurol* 2010; 23(3): 300–4.
 26. Thurnber MM, Post MJ, Rieger A, Kleibl-Popov C, Loeve C, Schindler E. Initial and follow-up MR imaging findings in AIDS-related progressive multifocal leukoencephalopathy treated with highly active antiretroviral therapy. *AJNR Am J Neuroradiol* 2001; 22(5): 977–84.
 27. McKinney AM, Sarikaya B, Gustafson C, Truwit CL. Detection of microhemorrhage in posterior reversible encephalopathy syndrome using susceptibility-weighted imaging. *AJNR Am J Neuroradiol* 2012; 33(5): 896–903.
 28. O'Sullivan M. Leukoaraiosis. *Pract Neurol* 2008; 8(1): 26–38.
 29. Hugonnet E, Da Ines D, Boby H, Claise B, Petitcolin V, Lannareix V, Garcier JM. Posterior reversible encephalopathy syndrome (PRES): features on CT and MR imaging. *Diagn Interv Imaging* 2013; 94(1): 45–52.
 30. Culebras A, Kase CS, Masden JC, Fox AJ, Bryan RN, Grossman CB, et al. Practice guidelines for the use of imaging in transient ischemic attacks and acute stroke. A report of the Stroke Council, American Heart Association. *Stroke* 1997; 28(7): 1480–97.
 31. Matthews PM, Tampieri D, Berkovic SF, Andermann F, Silver K, Chitayat D, et al. Magnetic resonance imaging shows specific abnormalities in the MELAS syndrome. *Neurology* 1991; 41(7): 1043–6.
 32. Pomper MG, Miller TJ, Stone JH, Tidmore WC, Hellmann DB. CNS vasculitis in autoimmune disease: MR imaging findings and correlation with angiography. *AJNR Am J Neuroradiol* 1999; 20(1): 75–85.
 33. Kallenberg K, Schulz-Schaeffer WJ, Jastrow U, Poser S, Meissner B, Tschampa HJ, et al. Creutzfeldt-Jakob disease: comparative analysis of MR imaging sequences. *AJNR Am J Neuroradiol* 2006; 27(7): 1459–62.

Received on May 29, 2014.

Revised on July 7, 2014.

Accepted on July 9, 2014.

Online First August, 2014.