



Sarcoidosis of the pleura – A case report

Sarkoidoza pleure

Dragana Jovanović*†, Violeta Vučinić*†, Ruža Stević†‡, Marina Roksanđić Milenković*, Natalija Samardžić*, Marta Velinović*, Mihailo Stjepanović*

*Clinic for Lung Diseases, Clinical Center of Serbia, Belgrade, Serbia; †Faculty of Medicine, University of Belgrade, Belgrade, Serbia; ‡Center for Radiology and Magnetic Resonance Imaging, Clinical Center of Serbia, Belgrade, Serbia

Abstract

Introduction. Pleural involvement is an uncommon manifestation of sarcoidosis. It may manifest as pleural effusion, pneumothorax, pleural thickening and nodules, hydropneumothorax, trapped lung, hemothorax, or chylothorax. The incidence of pleural effusion with sarcoidosis ranges from 0% to 5% but has been reported to be as high as 7.5%. Pleural effusions complicate sarcoidosis in < 3% of patients. **Case report.** We reported a 64-year-old male patient with chronic multiorgan sarcoidosis. This patient developed pleural sarcoidosis with massive pleural effusion several years after the diagnosis of sarcoidosis. A definitive diagnosis of a sarcoid pleural effusion was based on a biopsy demonstrating noncaseating granuloma. The patient responded well to the treatment (methotrexate and methylprednisolone) with a complete withdrawal of pleural effusion following five weeks of the treatment beginning. **Conclusion.** The presented patient is a rare case of pleural involvement of sarcoidosis with massive effusion, who responded well to the treatment.

Key words:
sarcoidosis; pleural effusion; biopsy; therapeutics.

Apstrakt

Uvod. Zahvaćenost pleure je retka manifestacija sarkoidoze. Može se manifestovati kao pleuralni izliv, pneumotoraks, pleuralno zadebljanje, noduli, kao hidropneumotoraks, zarobljena pluća, hemotoraks ili hilotoraks. Učestalost pleuralnog izliva kod sarkoidoze kreće se od 0% do 5%, ali može biti i do 7,5%. Zahvaćenost pleure kod sarkoidoze javlja se kod < 3% bolesnika. **Prikaz bolesnika.** Prikazan je bolesnik, star 64 godine, sa hroničnom multiorganskom sarkoidozom. Bolesnik je razvio pleuralnu sarkoidozu sa masivnim pleuralnim izlivom nekoliko godina nakon postavljanja dijagnoze sarkoidoze. Definitivna dijagnoza sarkoidoznog pleuralnog izliva postavljena je na osnovu biopsije koja je pokazala nekazeifikovani granulom. Bolesnik je dobro reagovao na lečenje metotreksatom i metilprednisolonom, sa kompletnim povlačenjem pleuralnog izliva posle pet nedelja lečenja. **Zaključak.** Ovo je redak slučaj pleuralne zahvaćenosti sarkoidozom sa masivnim pleuralnim izlivom koji je dobro reagovao na lečenje.

Ključne reči:
sarkoidoza; pleura, izliv; biopsija; lečenje lekovima.

Introduction

Pleural involvement is an uncommon manifestation of sarcoidosis. It may be manifested as a pleural effusion, pneumothorax, pleural thickening and nodules, hydropneumothorax, trapped lung, hemothorax, or chylothorax¹⁻⁴. Clinically significant pleural manifestations occur in 2% to 4% of patients with sarcoidosis^{1, 2, 4, 5-9}. With the introduction of computed tomography (CT) scans, especially high resolution CT, awareness of pleural manifestations of sarcoidosis has increased, thus allowing detection of more subtle cases of pleural involvement. Pleural manifestations of sarcoidosis may arise at the initial presentation, or at a later stage in the development of known sarcoidosis. The devel-

opment of pleural sarcoidosis does not appear to have any clear prognostic value. Often the diagnosis is based on clinical findings without histologic proof because when the disease is present elsewhere, most pleural sarcoidosis does not require a biopsy to treat the patient properly. A total of 145 biopsy-proven cases of pleural involvement with sarcoidosis have been reported up to 2000⁴.

Case report

A 64-year-old male patient, had been treated since 1982 for type II diabetes. In 1992 a bronchoscopy with a transbronchial biopsy was performed because of both-sided lung lesions and hilar adenopathy, and sarcoidosis of the lung was

verified. He was treated with corticosteroids for several months successfully. A few years later, because of complaints of cardiac rhythm disorder, holter monitoring and radionuclid ventriculography were done and confirmed the myocardial sarcoidosis. From that moment, on several occasions he was treated due to clinical, biochemical and radiographic signs of deterioration of chronic multiorgan sarcoidosis. Chest radiography from 2000 presented the stable phase of sarcoidosis when the patient was receiving a maintenance dose of corticosteroids. At that time, remission of sarcoidosis was verified. Whenever trying to discontinue steroid treatment, the sarcoidosis relapsed, and deterioration became evident. Thus, by 2002 the patient was treated with corticosteroids, but because of a glycoregulation impairment as a consequence of this long-term treatment, the corticosteroids were discontinued and methotrexate introduced. In October 2002 a relapse of sarcoidosis was verified with radiographic findings of marked hilar adenopathy and both-sided interstitial changes in the lung parenchyma (Figure 1).

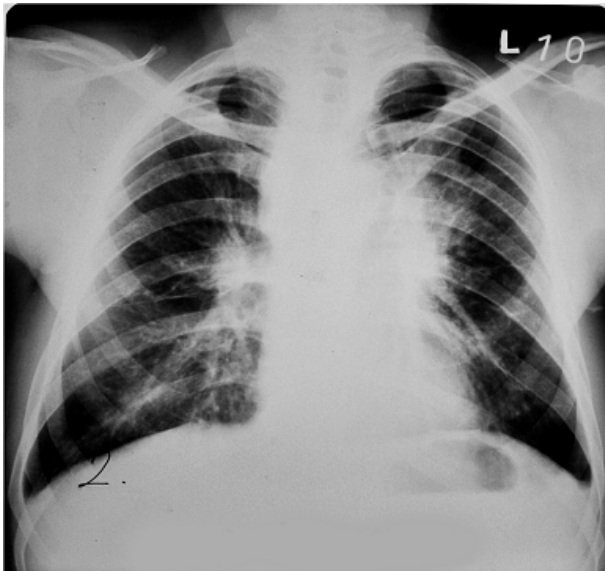


Fig. 1 – Chest radiography: hilar adenopathy and both-sided interstitial changes in the lung parenchyma.

The serum angiotensin converting enzyme (ACE) level was 39 U/L, and the calcium level in 24 h urine was 7.41 mmol/L. All the other clinical and biochemical findings were normal. A bronchoscopy was performed, the endoscopic finding showed extramural compression to the inner wall of the left main bronchus. A histologic analysis of transbronchial biopsy confirmed sarcoidosis. The methotrexate treatment dose was increased with the favorable effect of sarcoidosis remission achieved soon. Then the drug dose was set to the maintenance one.

Almost a year later at the check-up, the patient complained of progressive dyspnea and chest radiography revealed the shadow of a left-sided massive pleural effusion (Figure 2).

The serum level of ACE was 124 U/L (normal range less than 52 U/L) and the calcium 24-urine level was ele-

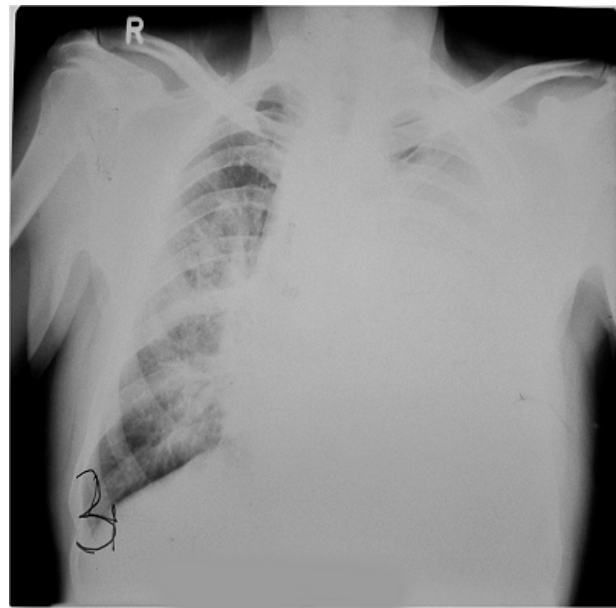


Fig. 2 – Chest radiography: left-sided massive pleural effusion.

vated – 7.2 mmol/L. The patient was hospitalized again, underwent thoracocentesis when 2 L of serous content were evacuated, characterized as a paucicellular, lymphocyte-predominant exudate. Then a pleuroscopy with pleural biopsy was performed. The histologic finding was noncaseating granulomas, indicative for pleural sarcoidosis (Figure 3).

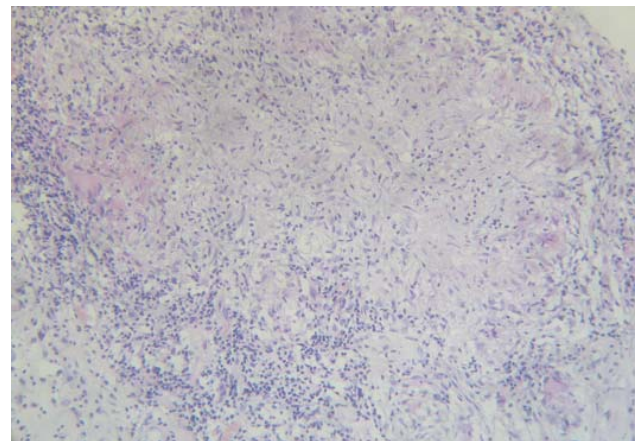


Fig. 3 – Histologic finding of noncaseating granulomas (HE, × 100)

Other causes of pleural effusion were excluded. Following the diagnosis, the methotrexate dose was increased to 10 mg *per week* and 20 mg daily of methylprednisolone was introduced. After 5 weeks of the treatment, a complete withdrawal of the pleural effusion was evident (Figure 4). After that the methotrexate dose was set to the maintenance one of 5 mg *per week*, and methylprednisolone to 15 mg every second day. After three months methylprednisolone was withdrawn.

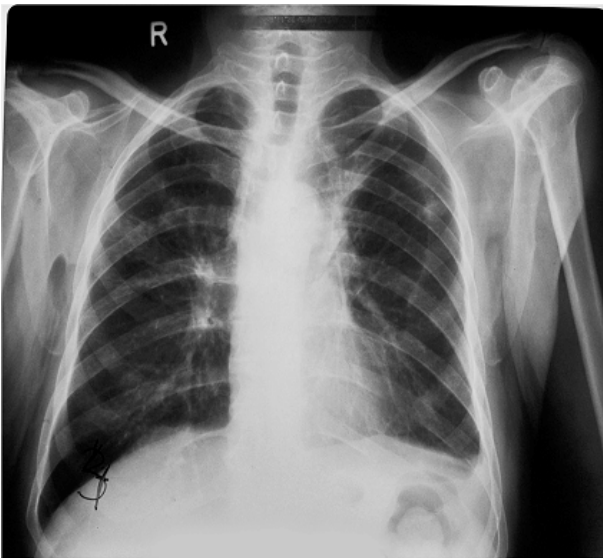


Fig.4 – Chest radiography: complete withdrawal of the pleural effusion.

Discussion

The incidence of pleural effusion with sarcoidosis ranges from 0% to 5%^{2,4,9} but has been reported to be as high as 7.5%⁸. Pleural effusions complicate sarcoidosis in < 3% of patients and, when present, are usually asymptomatic^{1,4}. We presented the case of sarcoid-related massive pleural effusion as the clinical manifestation of a relapse of sarcoidosis with progressive dyspnea as its only symptom. An analysis of the published references up to 1985 that included reports of pleural involvement with sarcoidosis^{4-6, 8-11} shows that out of a total of 3,146 sarcoidosis cases, 76 (2.4%) of them had pleural effusions¹⁰. However, in another report only three pleural effusions were detected among 2,775 patients with pulmonary sarcoidosis¹². Because sarcoid-related pleural effusions are rare, it should not be assumed that a pleural effusion occurring in a sarcoid patient is sarcoid-related; other causes of pleural effusion should be considered². We undertook all the available investigations to rule out tuberculosis and malignancy which are the most frequent causes of massive pleural effusion in our population, as well as other granulomatous diseases. The definitive diagnosis of sarcoid pleural effusion relies on a biopsy demonstrating noncaseating granuloma, with the exclusion of alternate granulomatous diseases. In a recent prospective study, thoracic ultrasonograms were performed in 181 consecutive outpatients with sarcoidosis². Pleural effusions were detected in five (2.8%) but only three (1.1%) patients were attributed to sarcoidosis; two were a manifestation of congestive heart failure. The mechanism of pleural effusion formation in patients with sarcoidosis is presumably similar to that of other infiltrative diseases. Involvement of the pleura may lead to increased capillary permeability. Superior vena cava obstruction¹³, endobronchial sarcoidosis leading to bronchial stenosis and lobar atelectasis¹⁴, trapped lung^{15,16} and lymphatic disruption with the development of chylothorax have been reported as a cause of sarcoid-related pleural effusions.

Our patient had left-side massive pleural effusion unlike the majority of published cases. Sarcoidosis-related pleural effusions occur slightly more commonly in the right lung (45%) than in the left lung (33%)⁴. The reason for the right-sided predominance is unclear and is not related to organ involvement. Bilateral effusions have been reported in 22% of cases⁴.

The onset of pleural effusion ranges from being coincidental with the first diagnosis of sarcoidosis¹⁷ to occurring several years after the diagnosis was made. The latter was the case we have described, our patient had progressive and profound dyspnea lasting for several weeks. In most cases published, the effusions were an incidental finding^{2,4,5,9,17-20}. Patients with a sarcoid pleural effusion usually have extensive parenchymal disease (radiographic stage 2 or stage 3) as it was the case in our report, but also frequently have extrathoracic sarcoidosis^{8,9,11,21}. In a series of pleural sarcoidosis with biopsy of visceral and parietal pleural surfaces performed, most cases were radiographic stage II and III sarcoidosis²². It appears that with progression of the parenchymal disease, the prevalence of pleural effusions decreases, while that of pleural thickening and pneumothorax increases⁴. Nevertheless, sarcoid-related pleural effusions can occur in all Scadding radiographic stages. There are no specific radiologic features of the pleural effusions that occur in sarcoidosis to suggest the cause, except for the presence of associated parenchymal disease or intrathoracic lymphadenopathy. Although being generally small to moderate, occasionally effusions can be massive^{5,9,11,18-21}, the same situation being with our patient who had left-sided massive sarcoid-related pleural effusion; sometimes they can be bilateral^{5,8,11,14,16,20-23} and rarely loculated²⁴. Sarcoid-related pleural effusions have been described as exudates or transudates; our patient had serous, paucicellular, lymphocyte-predominant exudate. However, most series^{4,5,8,9,11,13,14-16,18-22,25-28} have not reported the criteria used to classify these pleural effusions. Higgins et al.² have thus summarized the pleural fluid characteristics of all sarcoid-related pleural effusions reported in the literature. The majority of sarcoid-related pleural effusions are exudative. The appearance of the pleural fluid is most commonly serous, sporadically it is serosanguinous^{11,15,19,22} and an extremely rare finding is a bloody pleural effusion. The nucleated cell count is typically low at $\leq 1,100$ cells/ μ L. Lymphocytosis occurs in two thirds of cases^{1,2,4,5,9}, with predominance of CD₄ lymphocytes^{1,4}. Few cases of pleural fluid eosinophilia have been reported²⁹⁻³¹. The typical finding in sarcoid pleural effusions is a paucicellular, lymphocyte-predominant exudate, with a pleural fluid/serum protein ratio more consistently in the exudative range than the pleural fluid lactate dehydrogenase (LDH) criterion, as was the case with outpatient's effusion. The dyssynchrony between the pleural fluid protein and LDH ratios suggests that the pathogenesis of sarcoid-related pleural effusions is most consistent with increased capillary permeability with minimal pleural space inflammation. A definitive diagnosis of sarcoid pleural effusion in the presented case relied on the pleural biopsy sample demonstrating noncaseating granulomas, with the exclusion of granulomatous diseases of

known etiology, which is in accordance with the standard diagnostic approach. When it comes to treatment, our patient was treated for chronic sarcoidosis with methotrexate for a longer period of time up to the development of pleural effusion. As sarcoid pleural effusion was diagnosed, the drug dose was increased to 10 mg *per week* and for the following 3 months methylprednisolone was also prescribed in daily doses of 15 mg every second day. With the withdrawal of effusion, methotrexate was set to the maintenance dose of 5 mg *per week*. According to the literature, sarcoid pleural effusions may resolve spontaneously or require corticosteroids for resolution. The majority of these effusions, unlike the presented case, resolve spontaneously. The time of spontaneous resolution is variable, but most resolve in 1 to 3 months^{2,5,8,9,18,27}. However, there are reports of resolution at 2 weeks with corticosteroid therapy²⁰ and for as long as 6 months with or without corticosteroids^{9,14}. If the effusion is symptomatic and recurrent, steroid therapy is recommended for symptomatic relief and to hasten the resolution of the ef-

fusion. Incomplete resolution of these effusions has been reported with eventual progression to chronic pleural thickening⁸ or a trapped lung^{15,16}. Decortication has been successful in relieving dyspnea in a patient who had lung entrapment from sarcoidosis^{1,4,15,27}.

Conclusion

The presented patient is a rare case of pleural involvement of sarcoidosis with massive effusion, who responded well to the treatment.

Acknowledgements

This work was supported by the Ministry of Education, Science and Technological Development of the Republic of Serbia, contract No. 175046, 2011–2014.

Statement of interest

The authors declare no conflict of interest.

R E F E R E N C E S

- Lynch J, Ma Y, Koss M, White E. Pulmonary Sarcoidosis. *Semin Respir Crit Care Med* 2007; 28(1): 53–74.
- Huggins JT, Doelken P, Sabn SA, King L, Judson MA. Pleural effusions in a series of 181 outpatients with sarcoidosis. *Chest* 2006;129(6): 1599–604.
- Battesti JP, Azoulay E. Atypical forms of sarcoidosis. *Formes atypiques de sarcoidose*. *Ann Med Interne* 2001; 152(1): 51–7.
- Soskel NT, Sharma OP. Pleural involvement in sarcoidosis. *Curr Opin Pulm Med* 2000; 6(5): 455–68.
- Nicholls AJ, Friend JA, Legge JS. Sarcoid pleural effusion: three cases and review of the literature. *Thorax* 1980; 35(4): 277–81.
- Soskel N, Sharma OP. Pleural Involvement in Sarcoidosis: Case Presentation and Detailed Review of the Literature. *Semin Respir Med* 1992; 13(06): 492–514.
- Warsbansky ME, Shantes HM, Rozo A. Sarcoidosis involving the thyroid and pleura. *Sarcoidosis Vasc Diffuse Lung Dis* 1997; 14(2): 165–8.
- Wilen SB, Rabinovitz JG, Ulreich S, Lyons HA. Pleural involvement in sarcoidosis. *Am J Med* 1974; 57(2): 200–9.
- Sharma OP, Gordonson J. Pleural effusion in sarcoidosis: a report of six cases. *Thorax* 1975; 30(1): 95–101.
- Rockoff SD, Rohatgi PK. Unusual manifestations of thoracic sarcoidosis. *AJR Am J Roentgenol* 1985; 144(3): 513–28.
- Chusid EL, Siltzbach LE. Sarcoidosis of the pleura. *Ann Intern Med* 1974; 81(2): 190–94.
- Kostina ZI, Ivanovskii VB, Volosbko IV, Kol'nikova OV, Kborovskaia LA. Diagnosis and treatment of pleural lesions in sarcoidosis of the respiratory organs. *Probl Tuberk* 1992; 7–8: 21–3. (Russian)
- Gordonson J, Trachtenberg S, Sargent EN. Superior vena cava obstruction due to sarcoidosis. *Chest* 1973; 63(2): 292–3.
- Poe RH. Middle-lobe atelectasis due to sarcoidosis with pleural effusion. *N Y State J Med* 1978; 78(13): 2095–7.
- Heidecker JT, Judson MA. Pleural effusion caused by trapped lung. *South Med J* 2003; 96(5): 510–1.
- Claiborne RA, Kerby GR. Pleural sarcoidosis with massive effusion and lung entrapment. *Kans Med* 1990; 91(4): 103–5.
- Gardiner IT, Uff JS. Acute pleurisy in sarcoidosis. *Thorax* 1978; 33(1): 124–7.
- Selroos O. Exudative pleurisy and sarcoidosis. *Br J Dis Chest* 1966; 60(4): 191–6.
- Berte SJ, Pfofenbauer MA. Massive pleural effusion in sarcoidosis. *Am Rev Respir Dis* 1962; 86: 261–4.
- Johnson NM, Martin ND, McNicol MW. Sarcoidosis presenting with pleurisy and bilateral pleural effusions. *Postgrad Med J* 1980; 56(654): 266–7.
- Beekman JF, Zimmert SM, Chun BK, Miranda AA, Katz S. Spectrum of pleural involvement in sarcoidosis. *Arch Intern Med* 1976; 136(3): 323–30.
- Salazar A, Mañá J, Corbella X, Vidaller A. Sarcoid pleural effusion: a report of two cases. *Sarcoidosis* 1994; 11(2): 135–7.
- Kovnat PJ, Donoboe RF. Sarcoidosis involving the pleura. *Ann Intern Med* 1965; 62: 120–4.
- Loughney E, Higgins BG. Pleural sarcoidosis: a rare presentation. *Thorax* 1997; 52(2): 200–1.
- Everett ED, Overholt EL. Sarcoidosis and pleural effusion. *Milit Med* 1968; 133(9): 731–3.
- Tommasini A, Di VG, Facchinetti F, Festi G, Schito V, Cipriani A. Pleural effusion in sarcoidosis: a case report. *Sarcoidosis* 1994; 11(2): 138–40.
- Cohen M, Sabn SA. Resolution of pleural effusions. *Chest* 2001; 119(5): 1547–62.
- Ilan Y, Ben-Yehuda A, Breuer R. Pleural effusion: the presenting radiological manifestation of sarcoidosis. *Isr J Med Sci* 1994; 30(7): 535–6.
- Chao DC, Hassenpflug M, Sharma OP. Multiple lung masses, pneumothorax, and psychiatric symptoms in a 29-year-old African-American woman. *Chest* 1995; 108(3): 871–3.
- Werf VT, Vennik PH. Rare presentation or lead time bias in pleural sarcoidosis. *Thorax* 1997; 52(8): 752.
- Tudela P, Haro M, Marti S, Roig J. Eosinophilic pleuritis as the presenting form of sarcoidosis. *Med Clin (Barc)* 1992; 99(14): 558. (Spanish)

Received on August 14, 2012.

Revised on January 7, 2013.

Accepted on January 9, 2013.