



Coronectomy of two neighbouring ankylosed mandibular teeth – A case report

Koronektomija dva susedna ankilotična mandibularna zuba

Vladimir Biočanin*, Ljubomir Todorović†

*Department of Oral Surgery, Faculty of Medical Science, University of Kragujevac, Kragujevac, Serbia; †Clinic of Oral Surgery, Faculty of Dental Medicine, University of Belgrade, Belgrade, Serbia

Abstract

Introduction. Intentional partial odontectomy or coronectomy is primarily advocated in situations with intimate relationships between the roots of the tooth indicated for extraction and the inferior alveolar nerve (IAN). The aim of this report was to present a patient with two neighbouring infraoccluded teeth in the right mandible indicated for extraction prior to prosthetic rehabilitation, which were coronectomied as to prevent injuring of the IAN and causing iatrogenic fracture of the mandibular body. **Case report.** Coronectomy of both teeth was performed as recommended in the literature. The patient had no special discomfort after the operation or deficit in sensitive nerve function, and the wound healed uneventfully. The patient was followed regularly during a 2- year period. **Conclusion.** The presented case suggests coronectomy as quite beneficial solution for avoiding serious problems (injuring of the IAN and possible fracture of the mandible) and making feasible forthcoming prosthetic rehabilitation.

Key words:

tooth ankylosis; mandible; oral surgical procedures; treatment outcome.

Apstrakt

Uvod. Parcijalna odontektomija, ili koronektomija, prvenstveno se preporučuje u situacijama u kojima postoji blizak odnos korenova zuba indikovanih za ekstrakciju i donjeg zubnog nerva (DZN). Cilj ovog rada bio je da se prikaže bolesnica sa dva susedna infraokludirana zuba u mandibuli sa desne strane, indikovanih za ekstrakciju pre protetske rehabilitacije, koji su parcijalno ekstrahovani radi prevencije povrede DZN i jatrogene frakture tela donje vilice. **Prikaz bolesnice.** Koronektomija oba zuba izvedena je u skladu sa preporukama iz literature. Bolesnica nije imala nikakve posebne nelagodnosti posle operacije niti poremaćaj funkcije DZN, a rana je zarasla bez komplikacija. Bolesnica je redovno kontrolisana tokom dve godine. **Zaključak.** Kod prikazane bolesnice, koronektomija se pokazala kao korisno rešenje kojim su izbegnute ozbiljne komplikacije (povreda donjeg zubnog nerva i moguća fraktura mandibule) čime je omogućena sledstvena protetska rehabilitacija.

Ključne reči:

zub, ankiloza; mandibula; hirurgija, oralna, procedure; lečenje, ishod.

Introduction

Modern dentistry is based on conservative thinking and use of minimally invasive procedures¹. In oral surgery, intentional partial odontectomy (coronectomy) could be an example of such a principle. This procedure has raised a special attention in the last decade of previous century and at the beginning of this century after several reports on its benefits²⁻⁵. It is primarily advocated in situations with intimate relationships between the roots of the tooth indicated for extraction (mainly lower third molars) and the inferior alveolar nerve (IAN)^{3,6}.

However, there are still some controversies about the procedure that does not follow a customary principle of oral surgery practice – to finish tooth extraction removing all parts of the tooth. These controversies are related to the lack of knowledge on the long-term outcome of root remnants and possible complications of the procedure, for example apical periodontitis associated with the pulp necrosis⁷. There are, also, some other possible problems with root remnants, such as postoperative pain, dry socket or root migration after some elapse of time⁸.

It is interesting that coronectomy has been primarily recommended for protecting the IAN when there is a need

for removal the impacted lower third molar. Coronectomy is recommended for treating of ankylosed teeth too, but mainly as a method for preservation of alveolar ridge for subsequent prosthetic rehabilitation⁹. The aim of this report was to present a patient with two neighbouring ankylosed and infraoccluded teeth in the mandible indicated for extraction prior to prosthetic rehabilitation, which were coronectomied to prevent injuring of the IAN and causing iatrogenic fracture of the mandibular body.

Case report

A 42-year-old female patient was referred by her private dentist to the Clinic of Oral Surgery, Faculty of Dental Medicine in Belgrade, for extraction of two infraoccluded teeth in the right mandible, the second premolar and first molar, prior to prosthetic rehabilitation. The patient was warned by her dentist to a possibility of injuring the IAN during tooth extraction, and even causing an iatrogenic fracture of the mandible. That doubt was confirmed by the panoramic X-ray, which pointed out a close relationship of the mandibular canal to the first molar roots (Figure 1) – the fact that was confirmed by computed tomography (CT). Even more, a close relationship of the second premolar and the IAN could also be noticed at CT. We decided to perform coronectomy of both teeth to prevent both prospective unfavorable outcomes, and explained that proposal to the patient, which she accepted.

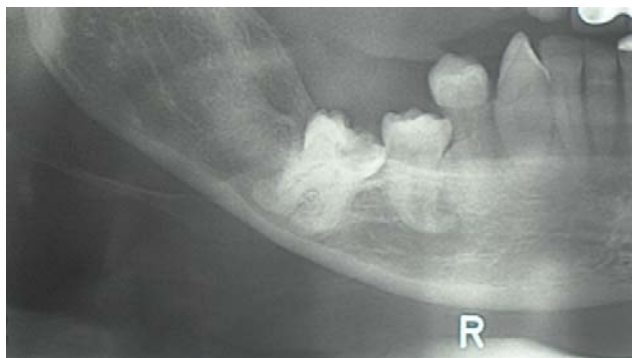


Fig. 1 – Closed relationship of the first molar roots to the mandibular canal.

Coronectomy was performed as recommended, sectioning the crowns of both teeth and part of the roots, approximately 3 mm below the buccal and the lingual bony margins (Figure 2). In the region of the mental foramen the nerve was completely visible, but it was not injured. Wound debridement was done as usual, closing the wound primarily. The patient did not have any special discomfort after the operation, only slight pain and swelling, and did not have any deficit in sensitive nerve function; the wound healed uneventfully and sutures were removed after a week.

The patient was followed regularly and three digital panoramic X-rays, one of those presented at Figure 3, were made in 6-month intervals in order to control the position of root remnants. The last panoramic x-ray, done two years

postoperatively did not show any movement of the roots left in the mandible; the molar roots were fully covered by bone and premolar roots only partially (Figure 4).

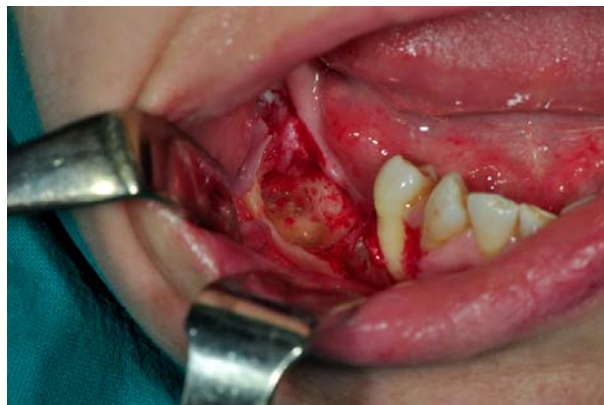

Fig. 2 – Intraoral view of the coronectomied teeth.

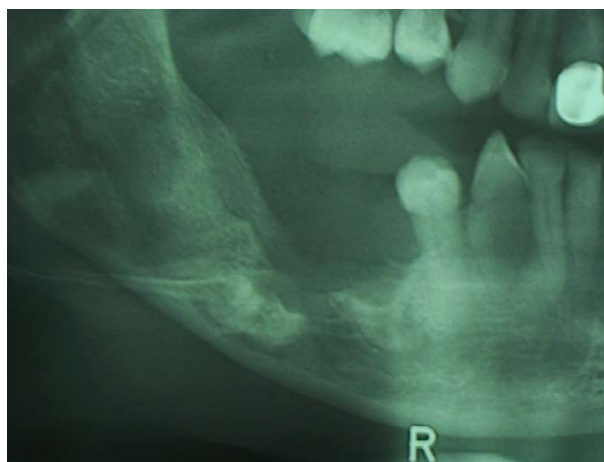

Fig. 3 – Panoramic view of the right mandible and the coronectomied teeth six months after the operation.

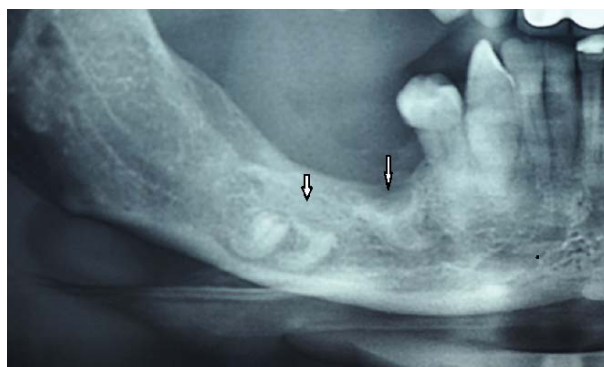

Fig. 4 – Panoramic view of the right mandible and the coronectomied teeth two years after the operation.

Discussion

Removal of impacted or partially impacted lower third molars is a very common procedure in oral surgery, accompanied with a number of temporary and mainly non-serious complications. One of the most embarrassing complications is IAN injury during the procedure, which may impair the

nerve function for an unpredictable period of time, even permanently¹⁰. To avoid such outcome when there is an intimate relationship between tooth roots and the IAN, intentional partial odontectomy or coronectomy is recommended for protecting the IAN^{3,5,6}. In the presented patient, this procedure showed to be quite beneficial not only for avoiding IAN injury, but also a probable fracture of the mandible, as both ankylosed teeth occupied almost the whole diameter of otherwise tiny mandibular corpus.

Ankylosis of two mandibular permanent neighbouring teeth, the first molar and the second premolar, is not a common situation. Ankylosis usually affects teeth after dental trauma¹¹. We could not claim what had caused ankylosis of those teeth; trauma, however, could not be disclosed in the patient's medical or dental history. Ankylosed teeth seem to be very difficult to extract without extensive bone removal. Therefore, coronectomy of ankylosed teeth was recommended as a suitable method for alveolar ridge preservation prior to prosthetic reconstruction or implant placement^{9,12}.

In the presented patient, insisting to complete extraction of both ankylosed teeth (the first lower molar and the second premolar) would almost certainly provoke an injury of the mandibular canal content, with concomitant bleeding and future neural deficit, and probably cause a mandibular fracture. Moreover, extensive bone removal needed for complete removal of ankylosed teeth would definitely interfere with

forthcoming prosthetic rehabilitation. Choosing coronectomy, the patient was submitted to shorter surgery and much lesser surgical stress than if the complete extraction was attempted, both serious complications (impairment of nerve function and mandibular fracture) were avoided and subsequent prosthetic rehabilitation was enabled.

Conclusion

Although we cannot report on long-term data of the undertaken procedure, not any of the cited questionable outcomes (postoperative pain, dry socket, root migration) has been encountered till now. However, having in mind the fact that long-term data concerning the outcome of the roots left *in situ* still lack, we believe that real indication for coronectomy exists primarily in situations with a clear benefit of avoiding serious complications. We consider that the presented patient just stands for such a case.

Acknowledgements

The authors are grateful to Mrs. Gordana Todorović for improving English of the paper.

This study was supported by the Serbian Ministry of Education, Science and Technological Development, Grant No. 175021.

R E F E R E N C E S

1. Patel V, Moore S, Sprout C. Coronectomy - oral surgery's answer to modern day conservative dentistry. *Br Dent J* 2010; 209(3): 111-4.
2. Freedman GL. Intentional partial odontectomy: review of cases. *J Oral Maxillofac Surg* 1997; 55(5): 524-6
3. Pogrel AM, Lee JS, Muff DF. Coronectomy: a technique to protect the inferior alveolar nerve. *J Oral Maxillofac Surg* 2004; 62(12): 1447-52.
4. Renton T, Hankins M, Sprate C, McGurk M. A randomised controlled clinical trial to compare the incidence of injury to the inferior alveolar nerve as a result of coronectomy and removal of mandibular third molars. *Br J Oral Maxillofac Surg* 2005; 43(1): 7-12.
5. O'Riordan BC. Coronectomy (intentional partial odontectomy of lower third molars). *Oral Surg Oral Med Oral Pathol Oral Radiol Endod* 2004; 98(3): 274-80.
6. Dolanmaz D, Yildirim G, Isik K, Kucuk K, Ozturk A. A preferable technique for protecting the inferior alveolar nerve: coronectomy. *J Oral Maxillofac Surg* 2009; 67(6): 1234-8.
7. Garcia-Garcia A. Coronectomy: a questionable procedure. *J Oral Maxillofac Surg* 2005; 63(5): 723-5.
8. Leung YY, Cheung LK. Safety of coronectomy versus excision of wisdom teeth: a randomized controlled trial. *Oral Surg Oral Med Oral Pathol Oral Radiol Endod* 2009; 108(6): 821-7.
9. Cobenca N, Stabholz A. Decoronation: A conservative method to treat ankylosed teeth for preservation of alveolar ridge prior to permanent prosthetic reconstruction: literature review and case presentation. *Dent Traumatol* 2007; 23(2): 87-94.
10. Smith WP. The relative risk of neurosensory deficit following removal of mandibular third molar teeth: the influence of radiography and surgical technique. *Oral Surg Oral Med Oral Pathol Oral Radiol* 2013; 115(1): 18-24.
11. Sapir S, Shapira J. Decoronation for the management of an ankylosed young permanent tooth. *Dent Traumatol* 2008; 24(1): 131-5.
12. Filippi A, Pohl Y, von Arx T. Decoronation of an ankylosed tooth for preservation of alveolar bone prior to implant placement. *Dent Traumatol* 2001; 17(2): 93-5.

Received on April 13, 2013.

Revised on May 26, 2013.

Accepted on June 25, 2013.