



Obstetric complications of placenta previa percreta

Akušerske komplikacije placente previje perkrete

Radmila Sparić*, Ljiljana Mirković*†, Uroš Ravilić*, Tijana Janjić*

*Clinic of Gynecology and Obstetrics, Clinical Center of Serbia, Belgrade, Serbia;

†Faculty of Medicine, University of Belgrade, Belgrade, Serbia

Abstract

Introduction. Placenta previa is related to severe maternal and fetal morbidity. The increasing incidence of cesarean delivery rate causes a marked increase in abnormally invasive placenta over the past decades. The abnormally invasive placenta is becoming the foremost cause of obstetric hemorrhage and postpartum hysterectomy, causing a significant maternal and fetal morbidity and even mortality. Maternal morbidity in such cases also comprise politransfusion, development of disseminated intravascular coagulation, uterine rupture, cystostomy, fistula formation, ureteral stricture, intensive care unit admission, infection, and prolonged hospitalization, adult respiratory distress syndrome, renal failure, septicemia and even death. **Case report.** A 38-year-old gravida 3, para 2, was admitted to our hospital at 27 weeks of gestation as an emergency due to vaginal bleeding, previously diagnosed with an anterior placenta previa. Following tocolytic therapy, bleeding stopped. The patient was informed on the diagnosis and the possibility of life-threatening hemorrhage necessitating preterm delivery. She was given corticosteroids to enhance fetal lung maturity. At 28 weeks of gestation, she experienced massive vaginal bleeding, and a decision was made to perform emergency cesarean section. We made a corporeal transverse uterine incision well above the uterovesical fold and tortuous vessels, at the same time avoiding the superior edge of the placenta. The placenta was found to be densely adherent to the lower uterine segment, penetrating through it and infiltrating the posterior wall of the urinary bladder. An attempt to remove the placenta resulted in injury to the bladder wall and the uterine rupture at a previous cesarean scar. The decision was made to perform total abdominal hysterectomy with placenta left *in situ*. At present, both mother and the baby are well. **Conclusion.** Anticipation and the surgeon's judgment are leading factors for surgery, from the choice of uterine incision type to the decision to proceeding to hysterectomy in order to reduce maternal morbidity.

Key words:

placenta previa; risk assessment; cesarean section; hysterectomy; treatment outcome.

Apstrakt

Uvod. Placenta previja je stanje koje je povezano sa teškim maternalnim i fetalnim morbiditetom. Povećanje incidencije carskih rezova dovelo je do značajnog povećanja abnormalno invazivne placente u prošloj deceniji. Abnormalno invazivna placenta je jedan od vodećih uzroka postpartalnih histerektomija, krvarenja kao i značajnog broja maternalnog i fetalnog morbiditeta i mortaliteta. Maternalni morbiditet u ovakvim slučajevima kompromituje transfuziju, dovodi do razvoja diseminovane intravaskularne koagulacije, do rupture uterusa, cistostomije, formiranja fistule, uretralnih striktura, dovodi do povećanja broja prijema u jedinice intenzivne nege, do infekcija, produženja hospitalizacije, razvoja adultnog respiratornog distres sindroma, otkazivanja bubrega, septicemije, čak i do smrti. **Prikaz bolesnika.** Trudnica, stara 38 godina, u trećoj trudnoći, primljena je u našu kliniku u 27 nedelji gestacije kao hitan slučaj zbog vaginalnog krvarenja. Prethodno kod trudnice dijagnostikovano je postojanje placente previje. Nakon primenjene tokolitičke terapije krvarenje je prestalo. Trudnica je informisana o dijagnozi i o mogućem, po život ugrožavajućem krvarenju, koje može prouzrokovati prevremeni porođaj. Primila je kortikosteroidnu terapiju u cilju maturacije fetalnih pluća. U 28 nedelji gestacije trudnica je obilno vaginalno prokrvarila, te je doneta odluka da se uradi hitan carski rez. Učinjen je transverzalni rez na telu uterusa iznad plike vezikouterine i proširenih krvnih sudova, izbegavajući gornji vrh placente. Placenta je probila ožiljak na donjem segmentu uterusa i infiltrirala se u zadnji zid mokraćne bešike, pa bi došlo do povrede mokraćne bešike i rupture uterusa ukoliko bi se pokušalo manuelno odvajanje i to na mestu ožiljka od prethodnog carskog reza. Totalna abdominalna histerektomija urađena je sa placentom na mestu upravo zbog mogućeg krvarenja. Majka i beba sada su dobro. **Zaključak.** Predviđanje i odluka hirurga odlučujući su faktori za operaciju, od izbora uterusne incizije pa do odluke da se nastavi ka histerektomiji, sve u cilju sniženja maternalnog morbiditeta.

Ključne reči:

placenta previja; rizik, procena; carski rez; histerektomija; lečenje, ishod.

Introduction

Placenta previa is related to severe maternal and fetal morbidity. Its incidence is growing due to the rising rate of cesarean sections and advanced maternal age on delivery¹. Increasing incidence of cesarean delivery rate is also causing a marked increase of abnormally invasive placenta over the past decades^{2,3}. It is 1 in 533 deliveries and the occurrence has risen 10-fold over the last five decades, which can mainly be attributed to the increased number of cesarean deliveries^{3,4}.

Therefore, abnormally invasive placenta is becoming the foremost cause of obstetric hemorrhage and postpartum hysterectomy, because it usually results in significant maternal and fetal morbidity and even mortality³. Most of the women with abnormally invasive placenta present with known predisposing factors³. Both placenta previa and abnormally invasive placenta have the same major risk factors, namely tissue insult and scarring. The usual causes are previous cesarean section, myomectomy, hysteroscopic surgery, suture of uterine perforation, infection and dilatation and curettage^{3,5}. The risk of abnormally invasive placenta increases proportionately with the number of previous cesarean deliveries⁶. Advanced maternal age is an independent risk factor for both conditions³. In the subgroup of women with placenta previa the risk of abnormally invasive placenta is predominantly increased. In the presence of placenta previa, the risk of having placenta accreta rises from 24% in women with one cesarean section to 67% for women with three previous cesarean sections⁶.

Abnormally invasive placenta is categorized into accreta/increta/percreta in the order of increasing severity and invasion of placental villi through the myometrium. The most severe form is placenta percreta, which involves placental penetration through the full thickness of the uterine wall and in some cases into adjacent organs such as urinary bladder, broad ligament, cervix, uterine artery and bowel⁵. Separation of such placenta from the uterine wall can lead to extensive hemorrhage. Placenta percreta with urinary bladder invasion is a principally uncommon, life-threatening complication of pregnancy⁶. It poses a significant risk of hemorrhage and carries a very high morbidity and mortality risk for both mother and the fetus.

The majority of women with abnormally invasive placenta require a hysterectomy. Although successful conservative management has been described, there are currently inadequate data to endorse this approach to management routinely^{6,7}. Maternal morbidity in cases of placenta percreta also comprises politransfusion, development of disseminated intravascular coagulation, uterine rupture, cystostomy, fistula formation, ureteral stricture, intensive care unit admission, infection, and prolonged hospitalization, adult respiratory distress syndrome, renal failure, septicemia and even death⁶⁻⁸.

Case report

A 38-year-old woman gravida 3, para 2, was admitted to our hospital at 27 weeks of gestation as an emergency due

to vaginal bleeding. The patient had a history of prior two cesarean sections, the first 9 years before and the second 4 years prior to the present pregnancy. She had been previously diagnosed with anterior placenta previa. Apart from several episodes of mild vaginal bleeding, her antenatal course was uneventful.

Her vital signs on admission were stable and hemoglobin was 102 g/L. Coagulation profile was normal. An ultrasound examination showed normal fetal anatomy and growth and confirmed the diagnosis of placenta previa. Following tocolytic therapy, bleeding stopped. The patient was informed of the diagnosis and the possibility of life-threatening hemorrhage necessitating preterm delivery. She was given corticosteroids to enhance fetal lung maturity and antibiotic prophylaxis. The patient was followed conservatively without further complications for 6 days.

At 28 weeks of gestation, she experienced massive vaginal bleeding, and a decision was made to perform emergency cesarean section under general anesthesia. Both the patient and her family were informed on the possible complications and a prior informed written consent to the probability of emergency cesarean hysterectomy and its associated morbidity was obtained.

On opening the abdominal wall by making lower median laparotomy incision omentum was found densely adherent to the anterior uterine wall, limiting its visualization and necessitating omental resection. We found the engorgement of the vessels around the vesicouterine peritoneal fold and the bladder outer surface, because of which we made a corporeal transverse uterine incision well above the uterovesical fold and tortuous vessels, at the same time avoiding the superior edge of the placenta. A male fetus with Apgar scores of 2 and 3 at 1 and 5 min, respectively, weighing 1,240 g was delivered. The neonate was transferred into neonatal intensive care unit. The placenta was found to be densely adherent to the lower uterine segment, penetrating through it and infiltrating the posterior wall of the urinary bladder. An attempt to remove the placenta resulted in injury to the bladder wall and the uterine rupture at a previous cesarean scar.

The patient became hypotensive, with blood systolic pressure 60 mm Hg and a heart rate 150 beat per min. The decision was made to perform a total abdominal hysterectomy with placenta left *in situ*. Intraoperative urologic consultation was obtained, which confirmed ureteric patency and trigon uninjured. The bladder wall was repaired in 2 layers.

Intraoperative coagulation studies were: platelets 80 000/ μ L, prothrombin time 26.6 s (reference values 10–13), international normalized ratio 2.48 (reference values 0.8–1.2), partial thromboplastin time (PTT) 112 s (normal range 60–70 s), fibrinogen 0.59 g/L (normal range 1.5–4.5 g/L), antithrombin III 14.6 (reference values 80–120), D dimer 3.12 (<0.5).

Over the course of 210-min surgical procedure massive blood transfusion was necessary: 11 units of packed red blood cells and 1,200 mL of autologous blood in order to replace blood loss. The patient was also given 10 units of fresh frozen plasma, 12 units of platelets, 10 units of cryoprecipi-

tate, 1,500 mL of colloid and 3,800 mL of crystalloid. She also received a course of prophylactic intravenous antibiotics. She was transferred to the intensive care unit where she received an additional of 3 units of packed red blood cells. The patient was monitored in the intensive care unit for 5 days.

The postoperative course was uneventful. The urinary catheter was left in place for 13 days. The patient was discharged within 2 weeks after the surgery voiding well. During follow up in the outpatient department there were no complications, including urological ones. The baby spent 26 days in the neonatal intensive care unit, and was discharged 69 days after the delivery without early neonatal sequelae. At present, both the mother and the baby are well.

The pathology report showed the placental villi extending through the myometrium of the lower uterine segment thus confirming the diagnosis of placenta previa percreta causing uterine rupture (Figure 1).

aging have been shown to be useful in antenatal diagnosis^{3,7}. In the presented case, the diagnosis was not recognized until emergency delivery. Prediction of abnormally invasive placenta relies on adequate screening with ultrasound, which was not performed in the presented case. Taking into account the rise in cesarean delivery rate, it would be recommendable to perform a routine screening for abnormally invasive placenta in cases with the presence of risk factors, such as the presented one. It is also advisable to use magnetic resonance imaging in cases with doubtful bladder and parametrial invasion³.

This case report demonstrates that, even in the absence of sophisticated diagnostic techniques, such as 3-dimensional ultrasound and magnetic resonance imaging, a high index of suspicion and an experienced surgeon can provide favorable results. Necessity to bear in mind possibility of abnormally invasive placenta in women with major risk factors is essential for good outcomes in such cases.

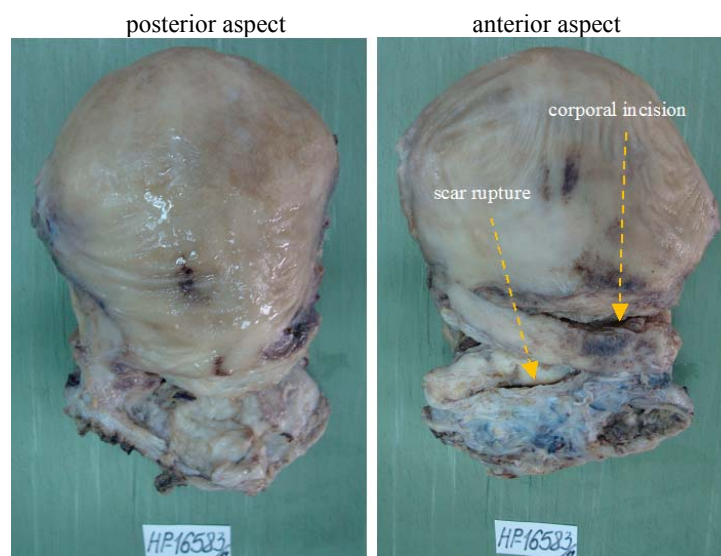


Fig. 1 – Macroscopic appearance of the uterus

Discussion

The incidence of abnormally invasive placenta has been reported to be increasing, and a persistent rise in cesarean delivery rates will cause its further rise^{9,10}. This condition has been present worldwide as the primary indication for emergency postpartum hysterectomy, accounting for up to 50% of all emergency peripartum hysterectomies nowadays^{1,2,5}. According to the results of our previous research, based on histological diagnosis, prevalence of abnormally invasive placenta in our institution is 0.19 *per* 1,000 deliveries (0.06% of cesarean sections)¹.

The presented 38-year-old patient had most of the significant risk factors for placenta percreta, namely 2 prior cesarean sections, anterior placenta previa. When a multipara with previous cesarean sections is found to have placenta previa, as in the presented case, the possibility of abnormally invasive placenta should be born in mind. Gray scale, color and power Doppler, as well as three-dimensional ultrasonography and magnetic resonance im-

The maternal morbidity in women with abnormally invasive placenta is high, especially in cases of placenta percreta⁸. The maternal mortality ranges from 7% to 22% in the literature⁶. In a meta-analysis of placenta percreta with bladder invasion published by Washecka and Behling⁸ there were three maternal deaths out of 54 cases. Maternal outcome can be significantly improved with the prenatal diagnosis³. Lethal outcome is more frequent in patients like ours, with antenatally unrecognized abnormally invasive placenta. The main cause of death in such cases is hemorrhage and disseminated intravascular coagulation⁶. The use of cell salvage has been advocated in the literature in woman with anticipated massive hemorrhage³. In the presented case, autologous blood salvage was used without any complications registered. The literature data suggests that mean blood loss at cesarean delivery in such cases is over 2.5 L, which explicates the routine use of intraoperative autologous blood salvage³. As presented in this case, the use of autologous blood transfusion can contribute favorable maternal outcome.

Extensive hemorrhage and urinary complications can be caused by manual removal of the placenta previa percreta, as in the presented case. The prenatal diagnosis of the condition in risk cases is important as scheduled cesarean hysterectomy can reduce maternal morbidity and mortality. With this attitude, there is concern for risk of neonatal morbidity because of premature birth as well. More data are necessary before making recommendations about the optimal timing of delivery in such women.

Treatment options vary from conservative approaches to obstetric hysterectomy³. Hysterectomy is considered to be the gold standard in management, particularly for women who do not wish to continue their fertility⁵. At the moment, this procedure seems to be the only appropriate treatment available but fertility-sparing options need to go into further research⁵. Having in mind uterine rupture, bladder involvement, age and patient's obstetric history, as well as intractable hemorrhage we undoubtedly performed emergency cesarean hysterectomy as a lifesaving procedure in the presented case, without considering conservative management. The conservative options include leaving the placenta *in situ*, awaiting either spontaneous resorption or expulsion. It is also manageable with prophylactic or therapeutic uterine artery embolization, internal artery ligation and methotrexate, uterine compression sutures and/or over sewing of the placental vascular bed. Because of collateral vasculature in the pelvis, hypogastric artery occlusion does not completely stop uterine blood flow and success rate in arresting hemorrhage with this technique⁶. The outcome of leaving the placenta in

place varies extensively, and includes complete remission, an intrauterine infection requiring prolonged administration of antibiotics, delayed vaginal bleeding and hysterectomy³. There are cases reported with placenta percreta that was left *in situ* with good outcome with adjuvant therapy given, including methotrexate, transarterial embolization of the uterine arteries or both³. The potential benefits of fertility sparing management must be weighed against the associated risks and the possibility of recurrent abnormally invasive placenta in these women. Surgery in cases of abnormally invasive placenta can cause injury to adjacent organs thus increasing maternal morbidity and mortality. Cystostomy is usually necessary, to facilitate dissection of the bladder⁸. Urological complications of placenta percreta with bladder involvement include massive hematuria, bladder laceration, urinary tract fistula, ureteric transection, cystectomy and small capacity bladder⁸. Preoperative ureteric stent placement may help reduce the risk of ureteric injury³. Recognition of bladder injuries at operation is paramount to prevent urinary fistula formation and further operation³.

Conclusion

Anticipation and the surgeon's judgment must be leading factors for surgery, from the choice of uterine incision type to the decision to proceeding to hysterectomy in order to reduce maternal morbidity. In addition, we suggest informed consent for cesarean delivery to include data about increased risk of abnormally invasive placenta in future pregnancies.

R E F E R E N C E S

1. *Mirković Lj, Janjić T, Sparić R, Ravlić U, Raslić Z.* Placenta accreta: incidence and risk factors. *J Perinat Med* 2013; 41(Suppl 1): 1196.
2. *Sparić R, Dokić M, Argirović R, Kadija S, Bogdanović Z, Milenković V.* Incidence of postpartum post-cesarean hysterectomy at the Institute of gynecology and obstetrics, Clinical center of Serbia, Belgrade. *Srp Arh Celok Lek* 2007; 135(3-4): 160-2. (Serbian)
3. *Doumouchtsis SK, Arulkumaran S.* The morbidly adherent placenta: an overview of management options. *Acta Obstet Gynecol* 2010; 89(9): 1126-33.
4. *Wu S, Kocherginsky M, Hibbard JU.* Abnormal placentation: twenty-year analysis. *Am J Obstet Gynecol* 2005; 192(5): 1458-61.
5. *Comstock CH.* The antenatal diagnosis of placental attachment disorders. *Curr Opin Obstet Gynecol* 2011; 23(2): 117-22.
6. *Guleria K, Gupta B, Agarwal S, Suneja A, Vaid N, Jain S.* Abnormally invasive placenta: changing trends in diagnosis and management. *Acta Obstet Gynecol Scand* 2013; 92(4): 461-4.
7. *Allabdin S, Voigt S, Htwe TT.* Management of placenta previa and accreta. *J Obstet Gynaecol* 2011; 31(1): 1-6.
8. *Wasbecka R, Behling A.* Urologic complications of placenta percreta invading the urinary bladder: a case report and review of the literature. *Hawaii Med J* 2002; 61(4): 66-9.
9. *Zizza A, Tinelli A, Malvasi A, Barbone E, Stark M, de Donno A, et al.* Cesarean section in the world: a new ecological approach. *J Prev Med Hyg* 2011; 52(4): 161-73.
10. *Silver LE, Hobel CJ, Lagasse L, Luttrull JW, Platt LD.* Placenta previa percreta with bladder involvement: new considerations and review of the literature. *Ultrasound Obstet Gynecol* 1997; 9(2): 131-8.

Received on October 10, 2013.

Revised on November 11, 2013.

Accepted on November 22, 2013.