



Challenges in treatment of postinfarction ventricular septal defect and heart failure

Izazovi u lečenju postinfarktognog septalnog defekta i srčane slabosti

Ljupčo Mangovski*, Rainer Kozlik-Feldmann[†], Miodrag Perić^{**},
Ljiljana Jovović*, Mihajlo Farkić*, Dragica Dekić*

*Cardiovascular Institute “Dedinje”, Belgrade, Serbia; [†]Department of Pediatric Cardiology and Intensive Care Medicine Ludwig-Maximilians-University Munich, Munich, Germany; ^{**}Faculty of Medicine, University of Belgrade, Belgrade, Serbia

Abstract

Introduction. Acquired ventricular septal defect (VSD) is uncommon, but serious mechanical complication of acute myocardial infarction with poor outcome and high mortality rate in surgically or medically treated patients. **Case report.** We report a 58-year-old male patient admitted to our hospital six days following acute inferior myocardial infarction complicated by ventricular septal rupture with signs of heart failure. Coronary angiography revealed 3-vessel disease, with proximally occluded dominant right coronary artery. Transthoracic echo exam revealed aneurysm of a very thin inferior septum and the basal portion of the inferior left ventricular wall, with septal wall rupture. One of the VSD dimensions was 15 mm and left- to right shunt was calculated 2 : 1. Since the patient was at too high risk for surgical closure, transcatheter closure of VSD was chosen as a better option. Under short intravenous sedation, 24 mm Am-

platzer device was implanted percutaneously with transesophageal echo guidance. The post-procedural result revealed a small residual shunt, but it was followed by significant improvement of the patient's clinical status. A 24h Holter ECG monitoring did not show cardiac rhythm or conduction disturbances. Coronary angiography was repeated ten days following the procedure, after hemodynamic stabilization of the patient, with direct stenting of the circumflex artery and the intermediate artery. Ostial left descending artery lesion was left for further functional significance assessment. **Conclusion:** Percutaneous closure with a septal occluder device can be definitive primary treatment for anatomically suitable patients or it can serve as a bridge to surgical treatment.

Key words:
myocardial infarction; heart, septal defects, ventricular; heart failure; heart catheterization; treatment outcome.

Apstrakt

Uvod. Stečeni ventrikularni septalni defekt (VSD) je retka ali ozbiljna mehanička komplikacija akutnog infarkta miokarda sa lošom prognozom i visokom stopom mortaliteta kod bolesnika lečenih hirurškim putem ili konzervativno. **Prikaz bolesnika.** U radu je prikazan bolesnik, star 58 godina, koji je primljen u našu instituciju šest dana nakon akutnog infarkta miokarda, komplikovanim rupturom inferoseptalnog dela septuma i znacima srčane insuficijencije. Koronarografija urađena u regionalnoj bolnici pokazala je trosudovnu koronarnu bolest sa proksimalno okludiranom, dominantnom, desnom koronarnom arterijom. Transtorakalnim ehokardiografskim pregledom ustanovljena je aneurizma vrlo istanjenog inferiornog septuma i bazalnog dela inferiornog zida leve komore, sa rupturom septuma. Jedna od dimenzija defekta bila je 15 mm, sa izračunatim Qp: Qs odnosom od 2 : 1. S obzirom na to da je bolesnik bio pod jako visokim rizikom od hirurške korekcije defekta, odlučeno je da se pristupi transkateter-

skom zatvaranju VSD, kao boljoj opciji za bolesnika. Pod kratkom intravenskom sedacijom, postavljen je Amplatzer okluder 24 mm, uz neprekidnu transezofagealnu ehokardiografiju. Postproceduralnim ehokardiografskim pregledom ustanovljeno je prisustvo malog rezidualnog šanta, ali uz značajno poboljšanje hemodinamskog statusa. Na bolesnikovom 24-časovnom Holter elektrokardiogramu nisu registrovani poremećaji srčanog ritma. Deset dana nakon intervencije, urađena je ponovna koronarografija i stentiranje cirkumflekne arterije i ramus intermedijusa. Ostijalna lezija na prednjoj descendentnoj arteriji ostavljena je za dalju funkcionalnu dijagnostiku. **Zaključak.** Transkatetersko zatvaranje ventrikularnog septalnog defekta septalnim okludrom može biti definitivni način lečenja bolesnika sa anatomski pogodnim defektima, ali i poslužiti za premošćavanje do hirurškog lečenja.

Ključne reči:
infarkt miokarda; srce, ventrikulski septumski defekti; srce, insuficijencija; kateterizacija srca; lečenje ishod.

Introduction

Acquired ventricular septal rupture (VSD) is uncommon, but a serious mechanical complication of acute myocardial infarction (AMI) with the prevalence of 0.2–0.34%¹ and mortality rate up to 90% in medically treated patients¹. It occurs mostly within the first week after acute myocardial infarction¹. The American College of Cardiology/American Heart Association guidelines recommend urgent surgery repair of post infarction VSD (PIVSD) and coronary artery bypass grafting (CABG), even in hemodynamically stable patients². But despite advances in surgical care, the operative mortality remains 25–87%^{3,4} especially if associated with major risk factors such as cardiogenic shock (88% mortality vs 29% in those without cardiogenic shock)⁵, renal failure or other comorbidities. Mantovani et al.⁶ reported that posterior defect have higher mortality rate (50% vs 25% for anterior defect). Major residual shunt after surgery is also reported by Deja et al.⁷ in up to 40%. Since 1988 alternative treatment has been accepted as the option of choice in anatomically suitable patients with a high risk for surgical closure – transcatheter closure.

Case report

We reported our first transcatheter closure of PIVSD in a 58-year-old male patient with no previous chest pain history and due to pain in epigastrium first admitted to the regional gastroenterology department and the same day transferred to cardiology department under the diagnosis of inferior AMI. Angiography was done in the regional hospital revealing 3-vessel coronary disease with occlusion of the right coronary artery (RCA). On the day 2 postinfarction the patient deteriorated with new harsh holosystolic murmur – ultrasound confirmed ventricular septum rupture (VSR). The patient was admitted to our hospital six days following AMI with VSR and sign of heart failure. New York Heart Association (NYHA) functional class was III. The patient was

dyspnoic without chest pain, with the increased heart rate and blood pressure of 90/60 mmHg. Electrocardiogram (ECG) on admission showed sinus rhythm, with the heart rate of 95/min, Q- and negative T-wave in diaphragmal leads. Physical examination also revealed harsh pansystolic murmur along the left sternal border and rales over the lung fields, distended jugular veins. Transthoracic echo exam confirmed aneurysm of the inferior septum and basal segment of the inferior wall with VSR, one of dimensions being 15 mm (Figure 1a and b). Left-to-right shunt (Qp/Qs) was calculated as 2 : 1, and left ventricle ejection fraction was estimated as 45%. The patient was not supported with the intra-aortic balloon pump since it was not available in the regional hospital. Upon admission to our hospital, the heart team was consulted, but cardiac surgeons refused to do combined CABG and VSR closure surgery, because of the high perioperative risk due to recent myocardial infarction, large and anatomically complex VSR and hemodynamic instability of the patient (Euroscore II 10.54%). Transcatheter closure (TCC) was chosen as a better option. After the necessary equipment became available, the procedure was performed 14 days after acute myocardial infarction under sedation and transesophageal echo guidance, which was used for detailed assessment of the size and localization of VSR. Access was obtained from the right femoral vein and the right and left femoral artery. A left ventriculography was done in the left anterior oblique view with cranial angulation and aneurysm of the very thin inferior septum with septal rupture was confirmed (Figure 2a). The Amplatzer wire was advanced through VSR into the pulmonary artery (PA) and then snared in the PA with a Lasso catheter and exteriorized through the right femoral vein, forming arteriovenous loop (Figure 2B). An appropriate size delivery sheath was advanced with VSD 24 occluder across the defect into the left ventricle. After the device had been deployed (Figure 2c, d

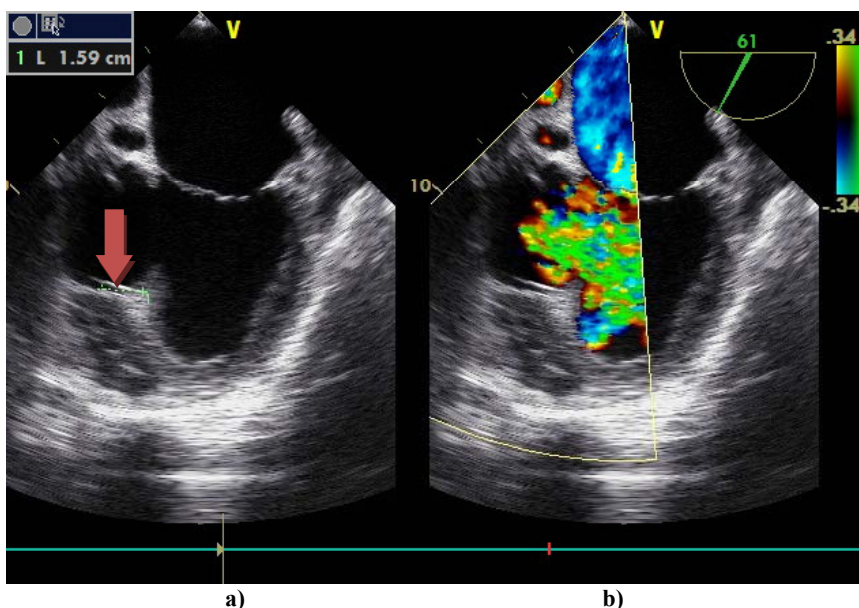


Fig. 1 – Transesophageal exam (stop frame) without (a) and with color Doppler (b) showing aneurysm of the inferior septum and basal segment of the inferior wall with ventricular septal rupture (arrow).

and e) left ventriculography and transesophageal echo were performed confirming a small residual shunt (Figure 3). Peri-procedural, the patient got acetylsalicylic acid, clopidogrel, unfractionated heparin.

Post-procedural monitoring showed improvement of the hemodynamical and clinical status of the patient. 24-h Holter ECG did not show any cardiac rhythm or conduction disturbances. Ten days after the procedure, coronary angiography

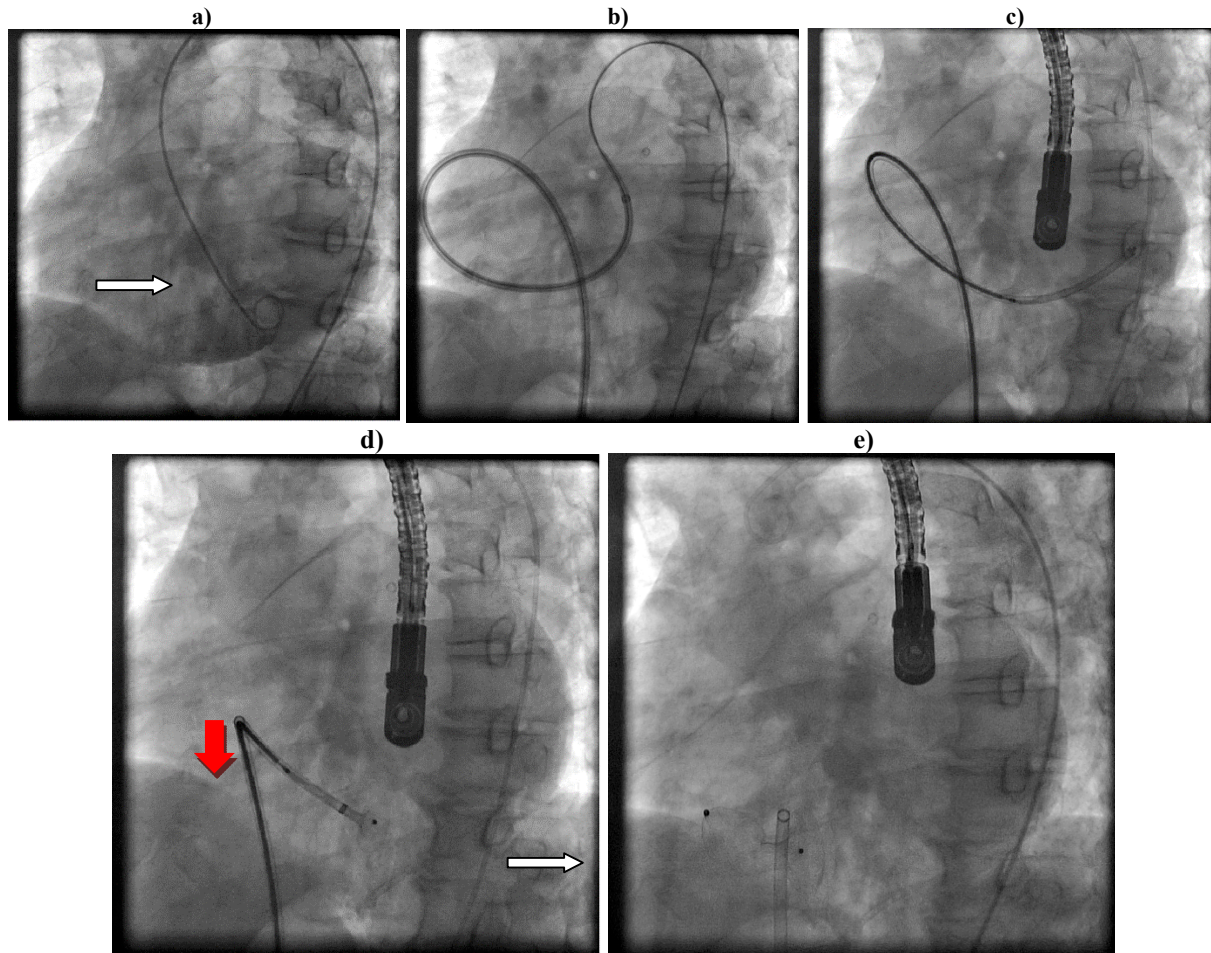


Fig. 2 – Angiographic steps in closure of muscular ventricular septal defect (VSD):

a) Left ventricle angiogram demonstrates the presence of a basal-septal VSD (white arrow); b) An Amplatzer wire was advanced through a VSD into the pulmonary artery and with a Lasso catheter exteriorized through the right femoral vein, forming arteriovenous loop; c) The wire goes across the VSD from the left ventricle with a delivery sheath in the left ventricle where the device advances; d) The left sided disc advances into the left ventricle (red arrow); e) After the right sided disc has been deployed into the correct position, the device is released from the delivery cable.

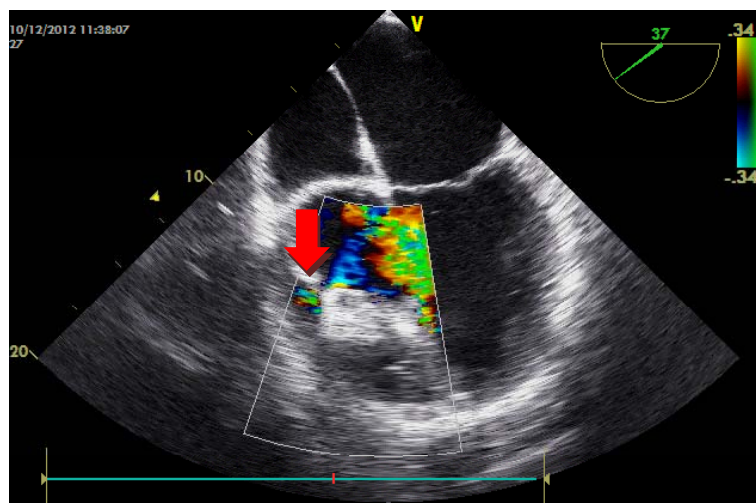


Fig. 3 – Transesophageal exam images of Amplatzer muscular ventricular septal defect (VSD) device after VSD closure with a small residual shunt.

was repeated with direct stenting of the intermediate artery and circumflex artery. The ostial left anterior descending coronary artery assessed as with < 50% stenosis was left for further functional assessment. After a month the patient was discharged in the NYHA II class with recommended therapy ASA, clopidogrel, ACE inhibitors, beta blocker, statin and spironolactone.

Discussion

TCC can be a definitive treatment or a bridge to surgical or PCI procedure in unstable patients considering that patients with PIVSD usually have single- vessel coronary disease⁸ (45% vs 21% for 3- vessel coronary disease). Timing of TCC of PIMVSD is one of the major determinants of outcome. When TCC is performed during an acute phase, Thiele et al.⁹ reported high mortality up to 65% as in surgically treated patients, but when done in the subacute phase Bialkowski et al.¹⁰ reported successful implantation in 73% and overall mortality of 26%. The size of the defect has influence on the outcome, since the available devices have a limitation regarding the size. Since the major residual shunt or device embolization are reported when the defect is > 15 mm¹¹, larger defects should undergo surgical treatment. Our procedure was done 14 days after myocardial infarction, and the size of the defect was 15 mm with a very thin wall. Amplatzer perimembranous VSD occluder was the option of choice, but due to technical problem, a VSD muscular occluder was used. After the procedure, Holzer et al.¹² reported a high percent of residual shunt but only 18% were moderate. In the patient presented residual shunt was noticed but it was not significant, with a reduction

in Qp/Qs. Although malignant arrhythmias can appear during or after the procedure¹⁰ cardiac rhythm and conduction disturbances were not present in the presented patient. Indication for percutaneous revascularization of the infarct-related artery with plain old balloon angioplasty (POBA) or stent after diagnostic angiography and before Amplatzer implantation was discussed but was not indicated because at the time of admission to our center, myocardial infarction was in the subacute phase: the patient was without chest pain, and the aneurysm was already formed in the inferior septal myocardium, with significant VSD and dominant symptoms were those of heart failure and not of ischemia. It was the decision of heart team that percutaneous coronary intervention of the infarct-related artery would not improve the patient's clinical status nor it would solve the mechanical problem of the complication.

The presented patient was in stable condition 6 months after the procedure, in the NYHA functional class I-II. The plan for further treatment is clinical and echo control and noninvasive assessment of the potentially ischemic left anterior descending artery (LAD) area and the stent treated artery.

Conclusion

Transcatheter closure should be considered more frequently as a treatment modality in suitable patients with post myocardial infarction ventricular septal defect. The development of hybrid procedures and more sophisticated devices will also improve the outcomes in patients with transcatheter closure of post myocardial infarction ventricular septal defect.

R E F E R E N C E S

1. *Crenshaw BS, Granger CB, Birnbaum Y, Pieper KS, Morris DC, Kleiman NS, et al.* Risk factors, angiographic patterns, and outcomes in patients with ventricular septal defect complicating acute myocardial infarction. GUSTO-I (Global Utilization of Streptokinase and TPA for Occluded Coronary Arteries) Trial Investigators. *Circulation* 2000; 101(1): 27–32.
2. *Antman EM, Anbe DT, Armstrong PW, Bates ER, Green LA, Hand M, et al.* ACC/AHA guidelines for the management of patients with ST-elevation myocardial infarction—executive summary: a report of the American College of Cardiology/American Heart Association Task Force on Practice Guidelines (Writing Committee to Revise the 1999 Guidelines for the Management of Patients With Acute Myocardial Infarction). *Circulation* 2004; 110(5): 588–636.
3. *Bouchart F, Besson JP, Tabley A, Redonnet M, Mouton-Schleifer D, Haas-Hubscher C, et al.* Urgent surgical repair of postinfarction ventricular septal rupture: early and late outcome. *J Card Surg* 1998; 13(2): 104–12.
4. *Menon V, Webb JG, Hillis LD, Sleeper LA, Abboud R, Dzavik V, et al.* Outcome and profile of ventricular septal rupture with cardiogenic shock after myocardial infarction: a report from the SHOCK Trial Registry. Should we emergently revascularize Occluded Coronaries in cardiogenic shock. *J Am Coll Cardiol* 2000; 36(3 Suppl A): 1110–6.
5. *Moore CA, Nygaard TW, Kaiser DL, Cooper AA, Gibson RS.* Postinfarction ventricular septal rupture: the importance of location of infarction and right ventricular function in determining survival. *Circulation* 1986; 74(1): 45–55.
6. *Mantovani V, Mariscalco G, Leva C, Blanzola C, Sala A.* Surgical repair of post-infarction ventricular septal defect: 19 years of experience. *Int J Cardiol* 2006; 108(2): 202–6.
7. *Deja MA, Szostek J, Widenka K, Szafron B, Spyt TJ, Hickey MS, et al.* Post infarction ventricular septal defect - can we do better. *Eur J Cardiothorac Surg* 2000; 18(2): 194–201.
8. *Maltais S, Ibrahim R, Basmadjian A, Carrier M, Bouchard D, Cartier R, et al.* Postinfarction ventricular septal defects: towards a new treatment algorithm. *Ann Thorac Surg* 2009; 87(3): 687–92.
9. *Thiele H, Kaulfersch C, Daehner I, Schoenauer M, Eitel I, Borger M, et al.* Immediate primary transcatheter closure of postinfarction ventricular septal defects. *Eur Heart J* 2009; 30(1): 81–8.
10. *Bialkowski J, Szekutnik M, Kusa J, Kalamus Z, Gasior M, Przybylski R, et al.* Transcatheter closure of postinfarction ventricular septal defects using Amplatzer devices. *Rev Esp Cardiol* 2007; 60(5): 548–51. (Spanish)
11. *Attia R, Blauth C.* Which patients might be suitable for a septal occluder device closure of postinfarction ventricular septal rupture rather than immediate surgery. *Interact Cardiovasc Thorac Surg* 2010; 11(5): 626–9.
12. *Holzer R, Balzer D, Amin Z, Ruiz CE, Feinstein J, Bass J, et al.* Transcatheter closure of postinfarction ventricular septal defects using the new Amplatzer muscular VSD occluder: Results of a U.S. Registry. *Catheter Cardiovasc Interv* 2004; 61(2): 196–201.

Received on August 16, 2013.

Revised on October 16, 2013.

Accepted on December 10, 2013.