



## *Epidermolysis bullosa* of the esophagus – A case report

### Bulozna epidermoliza jednjaka

Maja Radić, Darka Hadnadjev

Center of Radiology, Clinical Center of Vojvodina, Novi Sad, Serbia

#### Abstract

**Introduction.** *Epidermolysis bullosa* is a rare skin disease which could be hereditary or acquired with autoimmune mechanism. Even though it is known that epidermolysis bullosa appears on various mucosa, the esophagus is seldom affected. **Case report.** We reported 19-year-old female patient who had been admitted due to dysphagia and odynophagia to solid food. Erythematous changes with bullae and excoriations could be found on the hands, feet, elbows and knees. The patient underwent barium swallow which revealed retaining of contrast in the vallecules and piriform recesses, as well as dilatation of meso- and hypopharynx – upper achalasia syndrome. The cause was stenosis at the level of upper functional sphincter of the esophagus, 10 mm in length with benign appearance. Small leakage of contrast into the trachea was visible at the later stage of examination, concomitant with volume load of the pharynx. Bullae were not detected. The whole esophagus was fairly uniformly stenotic and had fibrotic appearance. **Conclusion.** The authors emphasize that barium swallow can provide sufficient information regarding stenosis, dynamics of the disorder, as well as the stage of the disease. Furthermore, we highlight the importance of providing a complete diagnostic strategy in all dermatology patients who could simultaneously have mucous changes.

**Key words:**  
epidermolysis bullosa; esophagus; diagnosis.

#### Apstrakt

**Uvod.** Bulozna epidermoliza (*epidermolysis bullosa* – EB) je retko kožno oboljenje koje može biti nasledno ili stečeno po autoimunom mehanizmu. Poznato je da EB zahvata i sluzokožu. Ipak, jednjak je retko zahvaćen. **Prikaz bolesnika.** U radu je prikazana devetnaestogodišnja bolesnica sa tegobama disfagije i odinofagije na čvrstu hranu. Na rukama, stopalima, laktovima i kolenima videle su se eritematozne promene sa bulama i ekzorijacijama. Urađeni su akt gutanja i pasaža jednjaka s kontrastom (BaSO<sub>4</sub>) tokom kojih je ustanovljeno njegovo zadržavanje u valekulama i piriformnim recesusima, dilatacija mezo- i hipofarinksa sa benignom stenozom od 10 mm u visini gornjeg funkcionalnog sfinktera jednjaka, što je definisano kao sindrom gornje ahalezije. Istovremeno sa volumnim opterećenjem farinksa video se linearni prodor kontrasta u disajno stablo. Bule nisu viđene, a ceo jednjak je bio sužen, fibroznog izgleda. **Zaključak.** Važno je istaći da se aktom gutanja i pasažom jednjaka dobija dovoljno informacija o stepenu stenoze, dinamici poremećaja i stadijumu bolesti. Važno je da se naglasi da je kod bolesnika sa kožnim promenama i tegobama sa digestivnim traktom potrebno uraditi radiološki pregled digestivnog trakta s obzirom na to da mogu da postoje udružene promene na sluzokoži koje su i uzrok tegoba.

**Ključne reči:**  
epidermoliza, bulozna; jednjak; dijagnoza.

#### Introduction

*Epidermolysis bullosa* is a rare skin disease characterized by nail dystrophy, formation of vesicles and bullae as a response to minimal trauma. Most frequently it affects elbows, knees, palms and feet<sup>1,2</sup>.

The disease can be hereditary (there are two autosomal dominant and one autosomal recessive forms) or acquired with autoimmune mechanism. Furthermore, it can be subclassified based on histological findings – depending on the

level of skin in which bullae are formed (epidermis, *lamina propria* and dermis).

Symptoms appear very early in life, usually at infant age, but sometimes the first signs appear in adolescence. This depends on the form of the disease.

Although *epidermolysis bullosa* appears on mucosa, esophagus is seldom affected.

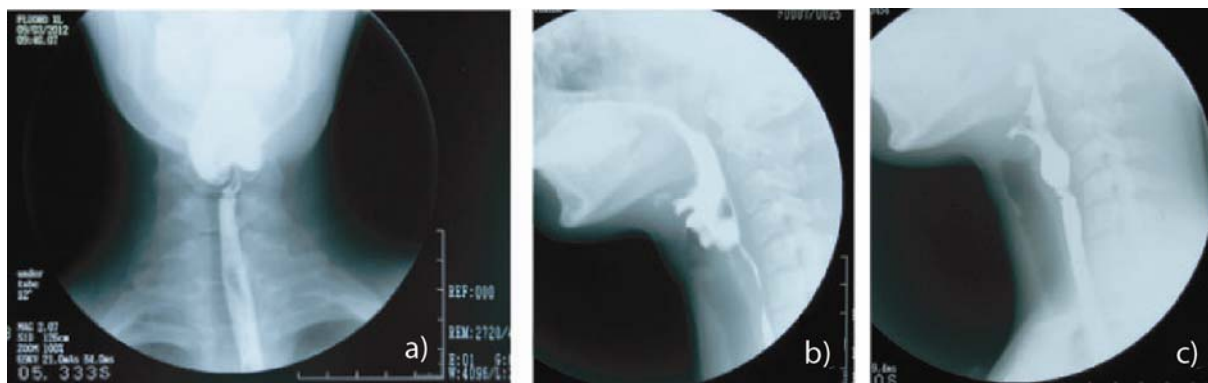
Here, we presented a patient with the whole esophagus stenotic with prestenotic dilatation and consecutive leakage of contrast material into the respiratory tract.

### Case report

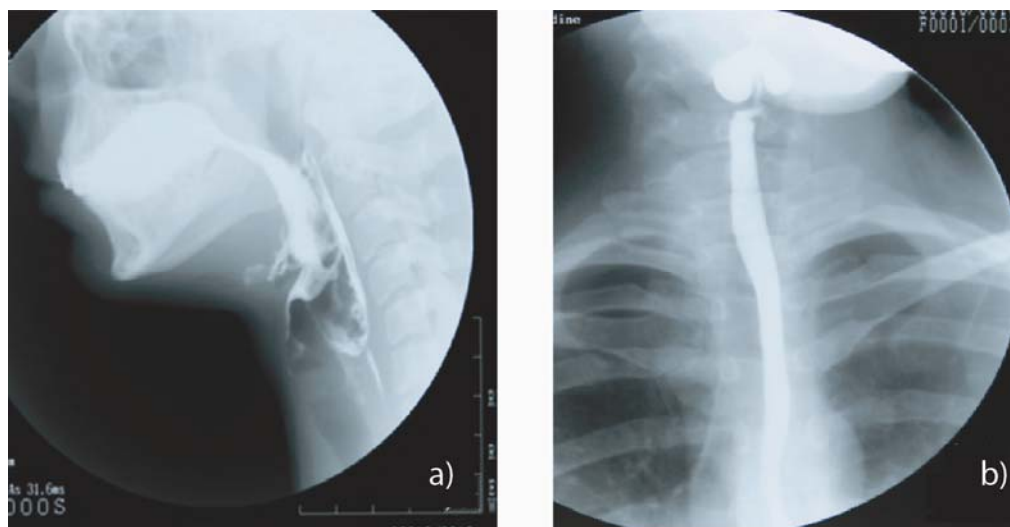
A 19-year-old female patient was admitted due to dysphagia and odynophagia to solid food. The symptoms first appeared a few months before admission and aggravated.

Laboratory findings (including blood count, serum electrolytes, sedimentation rate) showed a decreased level of hematocrit and hemoglobin while other parameters were within the range of normal.

The patient underwent radiological examination because of



**Fig. 1 – a) Anteroposterior view – retaining of contrast in the piriform recesses, dilatation of the pharynx and distal stenosis; b) Lateral view – dilatation of the hypo- and mesopharynx; c) Lateral view – level of stenosis**



**Fig. 2 – a) Lateral view – linear leakage of contrast into the trachea; b) Dynamic study – whole esophagus stenotic, with smooth margins and slow peristalsis.**

ted. The patient denied hematemesis, vomiting and melena. The family history was negative for similar diseases. The patient noticed skin changes before but paid no attention to them because, as she stated, her skin had always been fragile. When scratching it, small ulcers appeared turning into scars.

Physical examination revealed that the patient was ill nourished, slightly anemic and dehydrated. Oral mucosa appeared normal and without pathological changes. Nails had normal appearance. Skin was pale and its turgor was decreased. Erythematous changes with bullae and excoriations could be found on the hands, feet, elbows and knees. Lung examination revealed no pathology. The abdomen was slightly tender on light and deep palpation. There were no signs of defance or rebound tenderness.

difficulties with swallowing: barium swallow and evaluation of esophageal passage.

The oral phase of examination showed no pathological changes. The retaining of contrast in the valleculas and piriform recesses was seen, as well as dilatation of meso- and hypopharynx at the level of the upper functional sphincter of the vel of upper the functional sphincter of the esophagus. Stenosis was 10 mm in length and slightly tortuous, had the subtotal width and reduced elasticity (Figures 1a-c).

This was defined as upper achalasia syndrome. Also, there was a thin leakage of contrast into the trachea (Figure 2a).

Dynamic study (7 frames *per* second) revealed a completely stenotic esophagus whose contours were smooth with slow peristalsis and diminished antegrade propulsion. Bullous changes were absent (Figure 2b)

Esophagoscopy was not performed. Histological findings of skin changes biopsy showed that the level of skin where changes appeared was dermis.

### Discussion

*Epidermolysis bullosa* is a rare skin condition. Its etiology is hereditary (inherited in autosomal dominant or recessive patterns) or acquired when its etiology is autoimmune.

Further subclassification is based on histological findings. Depending on the level of skin where changes appear, it can be divided into *epidermolysis bullosa simplex* (epidermis, autosomal dominant pattern), junctional (junction of epidermis and basal membrane, also autosomal dominant), dystrophic (changes are inside dermis leading to scarring, inherited both autosomal dominant and recessive) and *epidermolysis bullosa acquisita* (acquired form, autoimmune etiology). Based on histological findings of skin changes, we concluded that our patient had dystrophic form.

Dysphagia first appears in the first decade of life in the majority of patients<sup>3</sup>. In the presented patient, symptoms occurred somewhat later, in the second decade of life, even though skin changes are likely to appear sometime before. It is highly unlikely that the presented patient had a recessive form of the disease because it did not appear in early childhood. Genetical mapping is under way.

*Epidermolysis bullosa* affects not only skin but mucosa as well. Pathophysiological mechanism is identical on both skin and mucosa – first bullae and vesicles form, then ulcers, all leading to scarring. Of course, erosions appear more often on mucosa. Trauma of the mucosa leads to formation of bullae and erosion forms after a bulla bursts. Reparative processes lead to formation of segmental stenosis<sup>4</sup>.

Even though *epidermolysis bullosa* appears on mucosa (eye, oral, nasal, anal, genital), the esophagus is seldom affected. The cause of esophageal changes is not known in the literature, but it is suspected that the trigger is a minor but repetitive food trauma.

Most frequently, the disease affects the proximal and distal third of the esophagus<sup>5</sup>. A very rare form of the disease, as in the presented patient, is when the whole esophagus is affected.

In further management, patients should be referred to the gastroenterologist who could perform endoscopic examination and biopsy of changes. Some patients have oral changes which make esophagoscopy impossible to perform. In the presented patient it was not the case – no changes of oral mucosa were seen. Sometimes a very narrow esophagus could disable endoscopic examination, thus a pediatric esophagoscope is used.

The therapy for the disease is administration of steroids and for partial stenosis – dilatation, palliative gastrostoma and colon transplant<sup>6,7</sup>.

Barium swallow provided information about stenosis, dynamics of the disorder as well as the stage of the disease. The cause of upper achalasia (with clinically significant stasis of contrast in the valliculas and piriform recessuses) was stenosis at the level of the upper functional sphincter of the esophagus. Stenosis was 10 mm in length and slightly tortuous, had the subtotal width and reduced elasticity. It had radiological features of benign stenosis.

Small leakage of contrast into the trachea was visible at the later stage of examination, which was concomitant with stenosis and volume load of the pharynx.

Bullae were not detected. The whole esophagus was fairly uniformly stenotic and had fibrotic appearance (lumen was reduced with smooth margins, slow peristalsis and diminished anterograde propulsion).

The symptoms of this disease resemble bullous pemphigoid but bullous pemphigoid affects older population.

### Conclusion

Generally, this insidious disease has to be considered in all patients who have difficulties with swallowing together with skin changes. In this way, one can improve the quality of patient's life and postpone complications. The presented patient was in the advance stage of the disease with fibrosis of the esophagus, segmental stenosis at the level of the upper esophageal sphincter, volume load of the pharynx and ensuing leakage of contrast into the respiratory tract. What was atypical in the presented case was that the entire esophagus was affected unlike proximal or distal third which are more common. Barium swallow can provide sufficient information regarding stenosis, dynamics of the disorder as well as the stage of the disease

### REFERENCES

1. Tishler JM, Han SY, Helman CA. Esophageal involvement in epidermolysis bullosa dystrophica. *AJR Am J Roentgenol* 1983; 141(6): 1283–6.
2. Mardsen F, Sambrook G, Mac Donald A, Main R. Epidermolysis bullosa of the oesophagus with oesophageal web formation. *Thorax* 1974; 29(3): 287–95.
3. Mauro MA, Parker LA, Hartley WS, Renner JB, Mauro PM. Epidermolysis bullosa: radiographic findings in 16 cases. *AJR Am J Roentgenol* 1987; 149(5): 925–7.
4. Luedtke P, Levine MS, Rubesin SE, Weinstein DS, Laufer I. Radiologic diagnosis of benign esophageal strictures: a pattern approach. *Radiographics* 2003; 23(4): 897–909.
5. Levine MS, Rubesin SE. Diseases of the esophagus: diagnosis with esophagography. *Radiology* 2005; 237(2): 414–27.
6. Warren RB, Warner TF, Gilbert EF, Pellet JR. Acquired double-barrel oesophagus in epidermolysis bullosa dystrophica. *Thorax* 1980; 35(6): 472–6.
7. Sebbat S, Amirie SA. Oesophageal reconstruction for complete stenosis due to dystrophic epidermolysis bullosa. *Thorax* 1977; 32(6): 697–9.

Received on July 27, 2013.

Revised on February 16, 2014.

Accepted on February 18, 2014.