



Efficacy of long-acting somatostatin analogs in recurrent variceal bleeding in a patient with pre-hepatic portal vein thrombosis

Delotvornost leka dugotrajnog dejstva analognog somatostatina kod bolesnice sa ponovljenim varikoznim krvarenjem i trombozom prehepatične portne vene

Tamara Alempijević*†, Ana Balović†, Aleksandra Pavlović-Marković*†,
Dino Tarabar‡§, Miodrag Krstić*†, Predrag Miljić*||, Miloš Bjelović*¶

*Faculty of Medicine, University of Belgrade, Belgrade, Serbia; †Clinic for Gastroenterology and Hepatology, ‡Institute for Hematology, §First Surgical University Hospital Clinic, Clinical Centre of Serbia, Belgrade, Serbia; ‡Clinic for Gastroenterology, Military Medical Academy, Belgrade, Serbia; §Faculty of Medicine of the Military Medical Academy, University of Defence, Belgrade, Serbia

Abstract

Introduction. Bleeding from esophageal varices is a serious medical problem because of the risk of recurrent bleeding and high mortality rate (17–54%). Gastroesophageal varices develop in 50% of cirrhotic patients with portal hypertension, but can also develop in other pre- or post-hepatic causes of portal hypertension. **Case report.** We reported a 48-year-old female patient with portal hypertension caused by mesenteric vein thrombosis due to congenital thrombophilia. The patient was hospitalized several times because of recurrent gastroesophageal bleeding. Thrombosis of portal, lienal and mesenteric veins was diagnosed using multislice computed tomography (MSCT) angiography. Sclerotherapy and/or variceal ligation could not be used due to variceal size and distribution. Beta blockers were ineffective. Balloon tamponade and octreotide were used in each massive bleeding episode. Carvedilol therapy was introduced but rebleeding occurred. Surgical treatment was considered a high risk procedure due to massive thrombosis of mesenteric veins, patient's general condition and high risk of postoperative thrombotic events. Thus, long-acting

somatostatin analogue – Sandostatin® LAR was initiated at a dose of 30 mg *im*/month. The patient responded to the therapy well and variceal bleeding did not occur for the following 3 months. After 3 months another episode of gastric variceal hemorrhage occurred and surgical treatment was reconsidered. Total gastrectomy was performed in order to prevent repeated bleeding from large gastric varices and the patient recovered successfully, and after 1 year is symptom-free. **Conclusion.** Long-lasting somatostatin analogue was used for the first time in treatment of gastroesophageal variceal hemorrhage in the patient with prehepatic portal hypertension. It was effective as temporary therapeutic option allowing the improvement of the patients general condition and adequate planning of elective surgical procedure. Further reports are needed in order to compare efficacy in treatment of patients with variceal bleeding, where poor outcome is expected.

Key words:
esophageal and gastric varices; hemorrhage; venous thrombosis; diagnosis; octreotide; digestive system surgical procedures; treatment outcome.

Apstrakt

Uvod. Krvarenje iz variksa jednjaka predstavlja ozbiljno medicinsko stanje s obzirom na veliki rizik i od recidiva i smrtnog ishoda (17–54%). Variksi jednjaka i želuca razvijaju se kod 50% bolesnika sa cirozom jetre i portnom hipertenzijom, mada i druga pre- i posthepatična oboljenja mogu dovesti do njihovog stvaranja. **Prikaz bolesnika.** Prikazali smo bolesnicu staru 48 godina, sa portnom hipertenzijom prouzrokovanom mezenterijalnom venskom trombozom usled kongenitalne trombofilije. Bolesnica je više puta bila hospitalizovana zbog recidivantnog masivnog varikoznog krvarenja. Tromboza portne, lijenalne i mezenterijalne vene dijagnostikovana je uz pomoć multislajsne kompjuterizovane tomografije

(MSCT) angiografije. Endoskopska terapija nije bila izvodljiva s obzirom na veličinu i lokalizaciju variksa. Krvarenje je svakog puta sanirano balon tamponadom i parenteralno sandostatinom. Beta blokatori bili su bez efekta. Hirurška terapija bila je veoma rizična zbog lošeg opšteg stanja i moguće postoperativne tromboze. Stoga je u terapiju uključen dugodelujući analog somatostatina – Sandostatin LAR u dozi od 30 mg *im*/mesečno. Bolesnica je adekvatno reagovala na ovu terapiju i bila bez epizoda krvarenja tri meseca. Nakon tri meseca ponovo su prokvarili gastroezofagealni varikoziteti, ali s obzirom na značajno bolje opšte stanje odlučeno je da se bolesnica podvrgne hirurškom lečenju. Urađena je toatalna gastrektomija, nakon čega se bolesnica oporavila i godinu dana kasnije bila bez tegoba.

Zaključak. Lek dugotrajnog dejstva, analog somatostatina, prvi put smo primenili za lečenje krvarenja iz gastroezofagusnog variksa kod bolesnice sa prehepatičnom portalnom hipertenzijom. Pokazao se delotvornim kao privremena opcija lečenja koja je popravila opšte stanje bolesnice i omogućila adekvatno planiranje elektivne hiruške procedure. Neophodna su dalja saopštenja da bi se uporedila efikasnost lečenja

bolesnika sa krvarenjem iz variksa, posebno tamo gde se ne očekuje povoljan ishod.

Ključne reči: jednjak i želudac, variksi; krvarenje; tromboza, venska; dijagnoza; oktreotid; hirurgija digestivnog sistema, procedure; lečenje, ishod.

Introduction

The most important cause of portal hypertension is liver cirrhosis, nevertheless portal vein thrombosis can also occur as a consequence of procoagulant mutations. Factor II G20210A is a mutation found in 4 out of 10 patients with idiopathic portal vein thrombosis (PVT)¹.

Variceal hemorrhage is the most serious complication of portal hypertension and accounting for 17–57% of all deaths in cirrhotic patients^{2,3}. The prognosis associated with variceal bleeding is overall much better in patients without significant liver impairment, *ie* those with non-cirrhotic portal vein thrombosis. The main therapeutic goals in patients with gastroesophageal varices is prevention of initial bleeding episode, control of acute variceal bleeding and prevention of recurrent variceal bleeding. Endoscopic sclerotherapy, endoscopic

Case report

A 48-year-old female was admitted with massive hematemesis and melena to the Clinic. Emergency esophagogastroduodenoscopy (EGD) revealed bleeding and esophageal and gastric varices (Figure 1.). Bleeding was controlled using blood volume restitution, vasoactive drugs and balloon tamponade. The personal history of the patient revealed 8 spontaneous miscarriages, one complicated with ileus. At the age of 28 variceal bleeding occurred, was treated with beta blockers and for 20 years no rebleeding occurred. At the age of 44, routine ultrasound examination revealed enlarged spleen and PVT and congenital thrombophilia (mutation of prothrombin gene G20210A) was diagnosed.

Thrombosis of portal, lienal and mesenteric veins was diagnosed using MSCT angiography. After repeated EGD it was

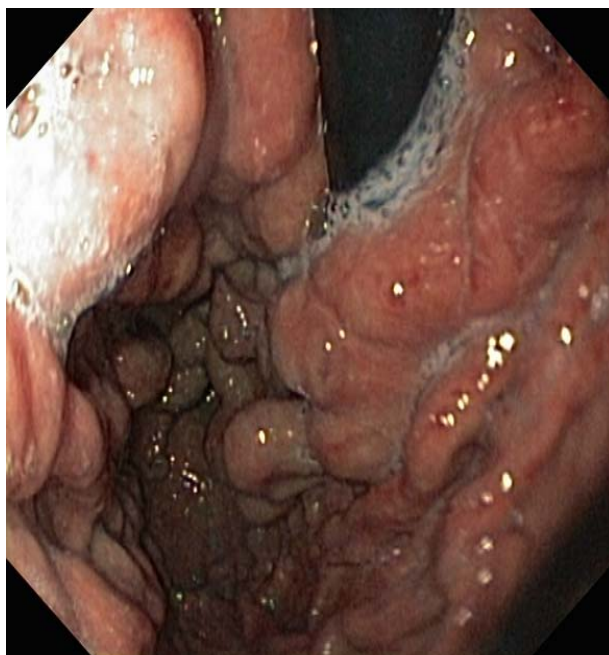

Fig. 1 – Macroscopic appearance of gastric varices and hypertensive gastropathy

variceal ligation and pharmacological treatment today have the overall success rate of 90%.

We presented a patient with recurrent variceal bleeding due to mesenteric vein thrombosis caused by congenital thrombophilia in whom long-acting somatostatin analogue was successfully used in control of repeated variceal bleeding for 3 months allowing patient stabilization and careful elective surgery planning.

concluded that sclerotherapy and/or variceal ligation would not be adequate solution due to variceal size and distribution. Beta blockers were introduced, but recurrent variceal bleeding occurred leading to multiple hospital admissions and blood transfusions. Balloon tamponade was used in massive bleeding episodes as a temporary therapy until definitive treatment. Octreotid was used for five days, but every time the therapy was discontinued, rebleeding occurred. There was no response to

oral and parenteral treatment with beta blockers and the patient became dependent on continuous infusion of somatostatin analogs. At the same time acute deep venous thrombosis of the left leg developed and low-dose anticoagulant was introduced (nadroparin 2,500 ij *sc/day*). Carvedilol therapy was introduced according to Baveno V consensus but rebleeding occurred. At that point surgical treatment was considered to be high risk procedure due to massive thrombosis of mesenterial veins, patient's general condition and high risk of postoperative thrombotic events. Thus, long-acting somatostatin analogue – Sandostatin® LAR was initiated at a dose of 30mg i.m./month. The patient responded to therapy well and variceal bleeding did not occur for the following 3 months.

After 3 months another episode of gastric variceal hemorrhage occurred and surgical treatment was reconsidered. Total gastrectomy was performed in order to prevent repeated bleeding from large gastric varices and the patient recovered successfully (Figures 2 and 3).

Discussion

In non-cirrhotic portal hypertension endoscopic therapy is effective for control of acute variceal bleeding, while for secondary prophylaxis preliminary evidence suggests beta blockers to be as effective as endoscopic ligation. Decompressive surgery or interventional radiological procedures are considered in patients with failure of endoscopic therapy³.

The Baveno V criteria do not provide consensus on the indications for anticoagulant treatment of extra hepatic portal vein thrombosis³, but in our patient it was initiated for acute deep venous thrombosis of the left leg.

Somatostatin analogue octreotide is used for decades in treatment of acute variceal haemorrhage, with the well-known mechanisms of lowering portal pressure. It increases efficacy of endoscopic therapy and decreases rebleeding risk⁴⁻⁷.

In the presented patient after all the other therapeutic options failed we introduced Sandostatin® LAR as an attempt of

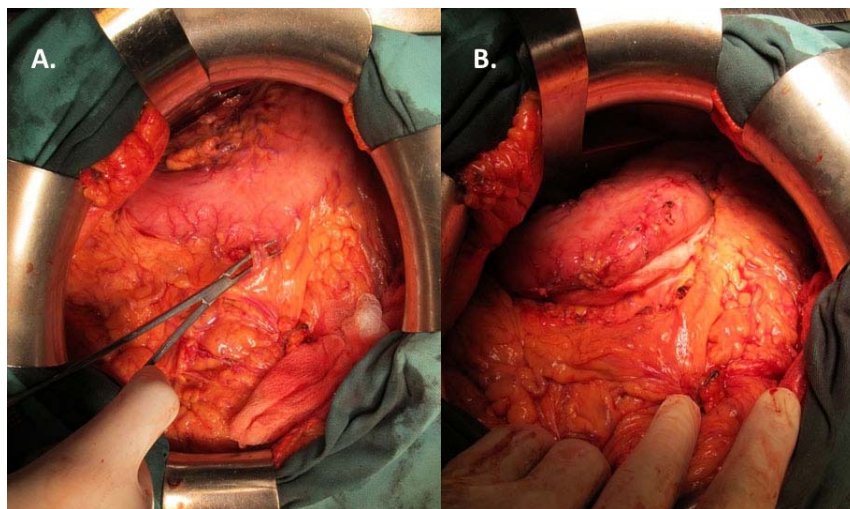


Fig. 2 – Perigastric devascularization – A) Surgical instrument inserted between greater curvature of the stomach, and the epiploic arcade along greater curvature; B) Great curvature of the stomach detached from the epiploic arcade.

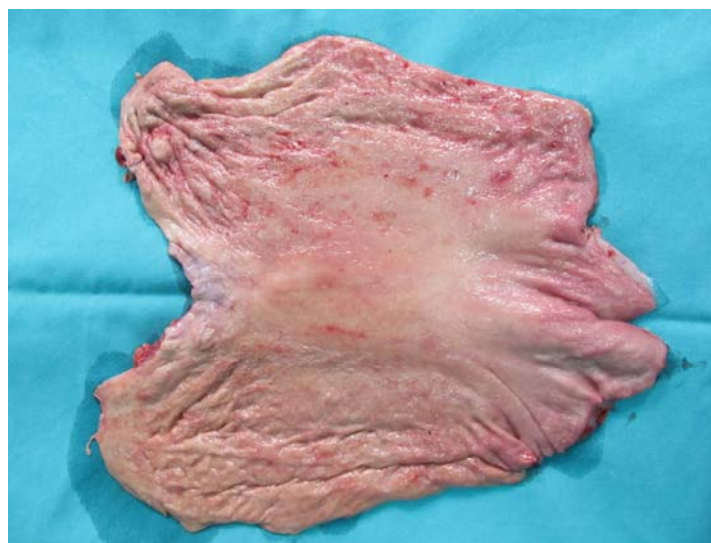

Fig. 3 – Specimen after total gastrectomy – the stomach open along the greater curvature. Macroscopic appearance of hypertensive gastropathy.

rescue therapy. Namely, data published by Spahr et al.⁸ suggested that prolonged administration of a long-acting formulation of octreotide improves significantly portal hypertension in carefully selected cirrhosis patients. Sustained decrease in splanchnic hyperemia was proposed as underlying pharmacological mechanism of octreotide.⁸

Conclusion

Long-lasting somatostatin analogue was used for the first time in treatment of gastroesophageal variceal hemorrhage in the patient with prehepatic portal hypertension. It

was effective as temporary therapeutic option allowing the improvement of the patient's general condition and adequate planning of elective surgical procedure. Further reports are needed in order to compare efficacy in treatment of patients with variceal bleeding, where poor outcome is expected.

Acknowledgement

This work was supported by the Ministry of Education, Science and Technological Development, Republic of Serbia (Grant No. III41004)

R E F E R E N C E S

1. *Chamonard P, Pencreach E, Maloïsel F, Grunebaum L, Ardizzone JF, Meyer A, et al.* Frequent factor II G20210A mutation in idiopathic portal vein thrombosis. *Gastroenterology* 1999; 116(1): 144–8.
2. *Jensen DM.* Endoscopic screening for varices in cirrhosis: findings, implications, and outcomes. *Gastroenterology* 2002; 122(6): 1620–30.
3. *de Franchis R.* Revising consensus in portal hypertension: report of the Baveno V consensus workshop on methodology of diagnosis and therapy in portal hypertension. *J Hepatol* 2010; 53(4): 762–8.
4. *Chatila R, Fenayorni L, Gupta T, Groszmann RJ.* Local arterial vasoconstriction induced by octreotide in patients with cirrhosis. *Hepatology* 2000; 31(3): 572–6.
5. *Wiest R, Tsai MH, Groszmann RJ.* Octreotide potentiates PKC-dependent vasoconstrictors in portal-hypertensive and control rats. *Gastroenterology* 2001; 120(4): 975–83.
6. *Huang H, Lee F, Chan C, Chang F, Wang S, Lin H, et al.* Effects of somatostatin and octreotide on portal-systemic collaterals in portal hypertensive rats. *J Hepatol* 2002; 36(2): 163–8.
7. *Wahren J, Ejfendić S, Luft R, Hagenfeldt L, Björkman O, Felig P.* Influence of somatostatin on splanchnic glucose metabolism in postabsorptive and 60-hour fasted humans. *J Clin Invest* 1977; 59(2): 299–307.
8. *Spahr L, Giostra E, Frossard J, Morard I, Mentha G, Hadengue A.* A 3-month course of long-acting repeatable octreotide (sandostatin LAR) improves portal hypertension in patients with cirrhosis: a randomized controlled study. *Am J Gastroenterol* 2007; 102(7): 1397–405.

Received on September 16, 2013.

Accepted on February 13, 2014.