



## Treatment of a large radicular cyst – enucleation or decompression?

### Lečenje velike radikularne ciste – enukleacija ili dekompresija?

Stevo Matijević\*†, Bojan Jovičić‡, Marija Bubalo§, Smiljka Dukić‡, Tatjana Čutović¶

\*Department of Oral Surgery, ‡Department of Endodontics, Parodontology and Oral Medicine, §Department of Oral Implantology, ¶Department of Orthodontics, Clinic for Dentistry, Military Medical Academy, Belgrade, Serbia; †Faculty of Medicine of the Military Medical Academy, University of Defence, Belgrade, Serbia

#### Abstract

**Introduction.** Radicular cysts treatment involves surgical approach, more or less aggressive. However, treatment of large cystic lesions, including radicular cysts, causes some of dilemmas concerning the choice of the surgical method, especially the degree of radicalism. **Case report.** We presented a 65-year-old male patient with large radicular cyst in the mandible. A large elliptical multilocular radiolucency, located in the left side of the mandible, being in close vicinity to the mandibular canal, was registered at the orthopantomographic radiography. There was a risk of pathological fracture of the mandible. However, the cyst was completely removed by enucleation without intraoperative and postoperative complications. **Conclusion.** The presented case support the opinion that careful enucleation of large mandibular cysts may be done without complications, such as damages of surrounding anatomical structures or mandibular fracture. The authors indicate reasons for strong support of the undertaken surgical approach of treating large radicular cysts in the mandible.

**Key words:** mandible; odontogenic cysts; oral surgical procedures.

#### Apstrakt

**Uvod.** Lečenje radikularnih cista podrazumeva hirurški pristup, manje ili više agresivan. Ipak, lečenje velikih cističnih lezija, uključujući i radikularne ciste, stvara nedoumice u izboru hirurške metode, posebno u stepenu radikalizma. **Prikaz slučaja.** Prikazali smo pacijenta, starog 65 godina sa velikom radikularnom cistom donje vilice. Na ortopantomogramu moglo se uočiti veliko elipsasto multilokularno rasvetljenje na levoj strani tela mandibule, u neposrednoj blizini mandibularnog kanala. Postojao je rizik od nastanka patološke frakture vilice. Ipak, cista je u potpunosti uklonjena enukleacijom bez intraoperativnih i postoperativnih komplikacija. **Zaključak.** Prikazani slučaj podržava stav da pažljivo izvršena enukleacija može da se uradi bez nastanka komplikacija, kao što su oštećenje okolnih anatomskih struktura ili prelom vilice. Autori ukazuju na razloge za snažnu podršku preduzetom hirurškom pristupu u lečenju velikih radikularnih cista u donjoj vilici.

**Ključne reči:** mandibula; ciste, odontogene; hirurgija, oralna, procedure.

#### Introduction

The most common cysts of adult jaws are inflammatory (radicular) cysts<sup>1</sup>, which occur after tooth pulp necrosis or insufficient root canal treatment. In children, however, non-inflammatory (developmental) cystic lesions are much more frequent than inflammatory ones<sup>2</sup>.

Radicular cysts treatment involves more or less aggressive surgical approach. Although enucleation of jaw cysts, the so-called “cystectomy”, and primary closure of the defect still represents the “state of the art procedure”<sup>3</sup>, enabling spontaneous bone healing<sup>4,5</sup>, more conservative approach, comprising just decompression of the cystic cavity as the

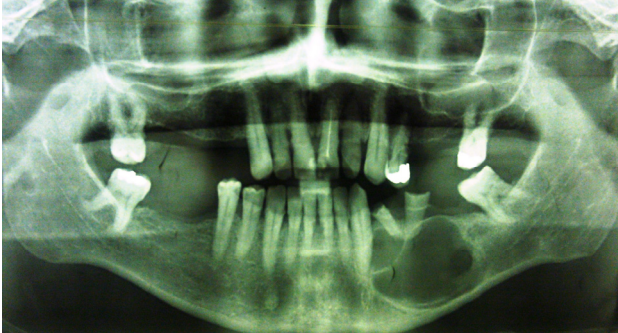primary procedure, has become popular recently, especially in case of large jaw cysts (> 3cm<sup>2</sup>)<sup>6,7</sup>.

The aim of this report was to present an adult patient with a large radicular cyst in the mandible, unusually multilocular, being in the close vicinity of the mandibular canal and with a serious risk of pathological jaw fracture, which is completely removed by enucleation without intraoperative and postoperative complications.

#### Case report

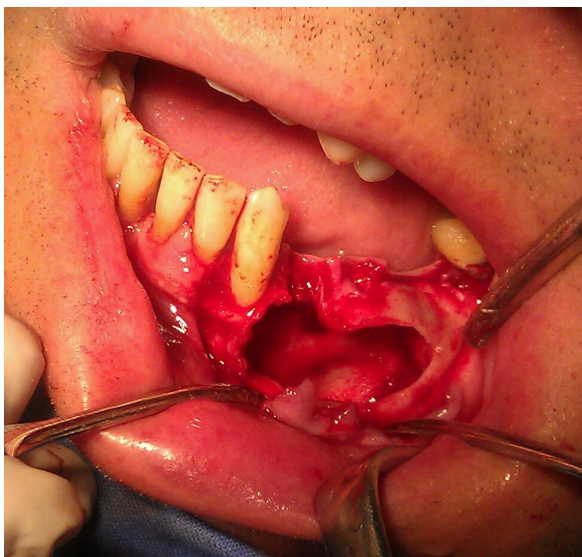A 65-year-old male patient was admitted to the Department of Oral Surgery, Military Medical Academy in Belgra-

de, because of expansion of the mandibular buccal cortex on the left side, as well as a large peri-mandibular soft tissue swelling. Intraoral examination revealed gangrenous roots of the left first and second mandibular premolars. On the panoramic radiography, a large elliptical multilocular radiolucency, located in the left side of the mandibular body, could be noticed (Figure 1).



**Fig. 1 – Orthopantomographic radiography at the time of examination showing large elliptical multilocular radiolucency located in the left side of the mandibular body.**

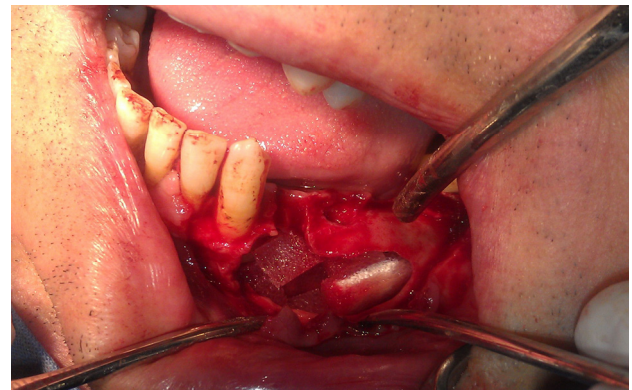Due to the existing infection at the time of examination, we made intraoral incision for drainage and commenced with antibiotic therapy (amoxicillin/clavulanate and metronidazole, orally). Seven days later, the symptoms of infection subsided and the patient underwent an incisional biopsy of the lesion under local anesthesia (4% Articain hydrochloride<sup>TM</sup>, 3M ESPE). As the left mandibular canine was nonvital, endodontic treatment was performed. A few days later, a pathological finding confirmed the diagnosis of radicular cyst.



**Fig. 2 – Bone defect after complete enucleation of the cystic lesion.**

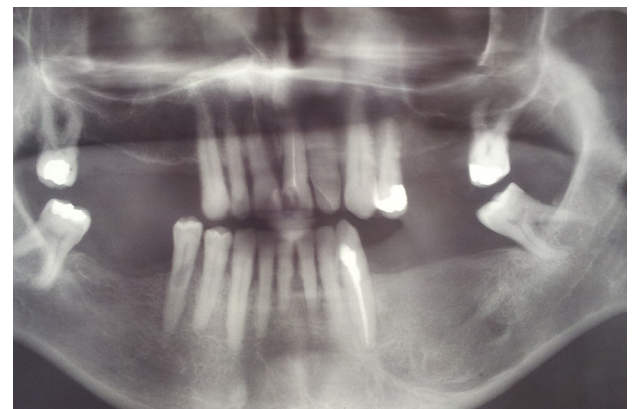
According to the histopathological finding, the patient was advised for surgical treatment (enucleation) of the lesion under local anesthesia. Although radiography pointed out a possible risk of injuring the mandibular canal contents, we decided to enucleate the cyst surgically. The patient was informed about the risks and adopted the surgical plan.

First, we removed gangrenous roots of the left lower premolar teeth. Surgical procedure started with incision along the superior border of the left mandible body, between the left mandibular canine and the second mandibular molar, then around the gingival margin of the left second mandibular incisor, mandibular canine and second mandibular molar, with two relaxing incisions down to the fornix. After uplifting the mucoperiosteal flap, a cortical perforation of the buccal cortex of the mandible body could be seen, as well as the membrane of the radicular cyst. After careful separation of the cystic membrane from surrounding anatomical structures and the mental nerve, lateral transposition of mental nerve was done. Then, the cyst was completely enucleated and the defect rinsed with saline (Figure 2). The filling completely blocked the defect with bone blocks (Osteovit<sup>®</sup>, B. Braun Melsungen AG, Germany) (Figure 3), and the wound was primarily closed with 4–0 silk sutures.



**Fig. 3 – Intraoral reconstruction of the mandibular defect with heterogeneous bone blocks.**

Postoperatively, the patient received antibiotics intramuscularly (ceftriaxon 2 g once daily) and orally (metronidazole 0.4g × 3 daily) for seven days, when sutures were removed. Paresthesia in the innervation area of the inferior alveolar nerve and mental nerve was present for 15 days after surgery, after which period a normal sensation returned. Other postoperative problems were not noticed. The patient was followed-up regularly, and after a 1-year period, the control panoramic radiography showed almost normal mandibular bone structure at the site of the previous defect (Figure 4).



**Fig. 4 – Orthopantomographic radiography 1-year after the surgery showing a successful bone healing on the left side of the mandible.**

## Discussion

Treatment of the large cysts lesions, including radicular cysts, has some of dilemmas concerning the choice of the surgical method, especially the degree of radicalism<sup>8</sup>. Recently, some authors, recommend conservative, less invasive surgical approach even in the treatment of large cysts, especially a method of decompression<sup>6,7</sup>. The crucial point of this approach is a decrease of the intracystic pressure and decrease the level of inflammatory mediators in the wall of cystic lesion<sup>6</sup>. Decompression includes creation of a window osteotomy; insertion of a stent, its fixation to the bone and/or adjacent soft tissue, and permanent irrigation<sup>6</sup>. Some reported that advantages of this method could be low morbidity and low incidence of complications, protection of adjacent anatomical structures (contents the mandibular canal), keeping mandibular continuity if there is a risk of traumatic fracture of the mandible, and in children or elderly patients<sup>6</sup>.

When selecting a method of surgery, one should always assess benefits and risks for any particular patient. However, it seems that the method of decompression has also some disadvantages. A major disadvantage is the fact that pathological tissue of the lesion stays in bone for a long postoperative period, especially if there is a need for subsequent enucleation. Minor disadvantages include dislocation or loss of the stent, the need for permanent irrigation, occlusion of the stent by detritus, discomfort for patients.

Thus, it seems that complete enucleation (cystectomy) of radicular cysts is still "state of the art procedure"<sup>3</sup>. Additionally, we filled the defect with bone substitute, although it is not warrant, as several studies have reported safe and regular bone healing after enucleation and simple closure

of jaw cysts without using bone grafts even in cases of large defects<sup>4,5</sup>. It seemed to us that the use of bone substitute will additionally decrease the possibility of local complications due to shrinkage of blood clot postoperatively.

Although positive clinical results with the use of decompression are recently reported, we believe that it cannot routinely be a definitive method of treatment, especially in cases of large radicular cysts. In the presented case, operated on by cystectomy, damages of vital neighboring anatomical elements, and pathological fracture of mandible, were not noticed. Also, we did not see any symptom of infection postoperatively. Accordingly, the presented case supports the opinion that careful enucleation of large mandibular cysts may be done without complications. Moreover, this approach significantly lowers postoperative discomfort for the patient, including needs for frequent and long-standing postoperative follow-ups, and enables early functional rehabilitation of the patient. In other words, enucleation (immediate and complete removal of pathological tissue) as a surgical approach should be the preferred method of treating large radicular cysts. The only exception could be in younger patients, with the aim of protecting unerupted permanent teeth.

## Conclusion

The presented case supports the opinion that careful enucleation of large mandibular cysts may be done without complications, such as damages of surrounding anatomical structures or mandibular fracture. The authors indicate reasons for strong support of the undertaken surgical approach of treating large radicular cysts in the mandible.

## R E F E R E N C E S

1. *Morgenroth K, Philippon S.* Oralpathologie II: Zahnsystem und Kiefer. Berlin: Springer; 1998. (German)
2. *Iatron I, Theologie-Lygidakis N, Leventis M.* Intraosseous cystic lesions of the jaws in children: a retrospective analysis of 47 consecutive cases. *Oral Surg Oral Med Oral Pathol Oral Radiol Endod* 2009; 107(4): 485–92.
3. *Ettla T, Gosana M, Saderb R, Reicherta ET.* Jaw cysts - Filling or no filling after enucleation?, A review. *J Cranio Maxillofac Surg* 2012; 40(6): 485–93.
4. *Chiapasco M, Rossi A, Motta JJ, Crescentini M.* Spontaneous bone regeneration after enucleation of large mandibular cysts: a radiographic computed analysis of 27 consecutive cases. *J Oral Maxillofac Surg* 2000; 58(9): 942–8.
5. *Iban Hren N, Miljavec M.* Spontaneous bone healing of the large bone defects in the mandible. *Int J Oral Maxillofac Surg* 2008; 37(12): 1111–6.
6. *Swantek JJ, Reyes MI, Grannum RI, Ogle OE.* A technique for long term decompression of large mandibular cysts. *J Oral Maxillofac Surg* 2012; 70(4): 856–9.
7. *Enislidis G, Fock N, Sulzbacher I, Ewers R.* Conservative treatment of large cystic lesions of the mandible: a prospective study of the effect of decompression. *Br J Oral Maxillofac Surg* 2004; 42(6): 546–50.
8. *van Doorn ME.* Enucleation and primary closure of jaw cysts. *Int J Oral Surg* 1972; 1(1): 17–25.

Received on January 4, 2014.  
Revised on January 22, 2014.  
Accepted on January 22, 2014.