



Eagle's syndrome – A report of two cases

Iglov sindrom

Aleksandar Kiralj, Miroslav Ilić, Bojan Pejaković, Borislav Markov,
Saša Mijatov, Ivana Mijatov

Clinic for Oral and Maxillofacial Surgery, Clinical Center of Vojvodina, Novi Sad,
Serbia

Abstract

Introduction. Eagle's syndrome is defined as elongation of the styloid process or the stylohyoid ligament mineralization complex which consist of styloid process, stylohyoid ligament and lesser horn of hyoid bone. It is a rare entity, is not commonly suspected in clinical practice. It is characterized by recurrent facial and throat pain, dysphagia, odynophagia, parapharyngeal foreign body sensation, otalgia and neck pain. Eagle's syndrome can be treated conservatively (lacing local anesthetic into the styloid process and stylomandibular ligament attachment) or surgically. Its pathogenesis and treatment modalities are still being debated while different theories have been presented. **Case report.** The two traditional surgical approaches to styloidectomy (removal of the elongated portion of the styloid process) were presented the intraoral approach and the extraoral approach. We presented two cases (49 years and 34 years old males), with bilateral and unilateral elongated styloid process. The surgical treatment included unilateral right side styloidectomy by intraoral approach in the first case and right styloidectomy by extraoral approach in the second case. In both cases post-operative course passed regularly with no complaints at regular postoperative control. **Conclusion.** Surgical techniques for treatment of Eagle's syndrome have many advantages and disadvantages. We believe that the length of the styloid process or the calcified ligament is a decisive parameter for the selection of techniques and approach.

Key words:

temporomandibular joint disorders; diagnostic techniques and procedures; oral surgical procedures.

Apstrakt

Uvod. Iglov sindrom se definiše kao skup simptoma nastao usled elongacije stiloidnog nastavka ili mineralizacije stilohioidnog kompleksa koji se sastoji od: stiloidnog nastavka, stilohioidnog ligamenta i malog roga hioidne kosti. To je redak entitet koji obično se u kliničkoj praksi slučajno dijagnostikuje. Karakterišu ga simptomi u vidu rekurentnog bola u predelu grla i lica, disfagija, odinofagija, osećaj stranog tela u grlu, otalgija i bol u vratu. Iglov sindrom leči se konzervativno (ubrizgavanje lokalnog anestetika u stiloidni nastavak i stilomandibularni ligament) ili hirurški. Sama patogeneza i lečenje ovog sindroma uzrok su mnogobrojnih debata, i ostavljene su različite teorije. **Prikaz slučaja.** Prikazali smo dva bolesnika sa slučajno dijagnostikovanim Iglovim sindromom. Prikazana su dva tradicionalna hirurška pristupa stiloidektomije (uklanjanja izduženog dela stiloidnog nastavka): intraoralni pristup i ekstraoralni pristup. Bolesnici su bili muškarci, starosti 49 i 34 godine sa bilateralnim i unilateralnim produženim stiloidnim nastavkom. Kod prvog bolesnika urađena je unilateralna desna stiloidektomija intraoralnim pristupom, a kod drugog desna stiloidektomija ekstraoralnim pristupom. U oba slučaja postoperativni tok bio je uredan, bez navođenja tegoba sa redovnim postoperativnim kontrolnim pregledom. **Zaključak.** Obe hirurške tehnike (intraoralnim i ekstraoralnim pristupom) imaju mnogo prednosti i nedostataka. Veruje se da je dužina stiloidnog nastavka ili kalcifikovani stilohioidni ligament odlučujući parametar za izbor tehnike i pristupa.

Ključne reči:

temporomandibularni zglobovi, poremećaji; dijagnostičke tehnike i procedure; hirurgija, oralna, procedure.

Introduction

Eagle's syndrome is a group of symptoms characterized by recurring pain in the region of the pharynx and the face, most often in the retromandibular region. Symptoms occur as a result of an elongated styloid process or ossified stylo-

hyoid ligament. It was first described in the literature in 1937 by Eagle¹ who connected the length of styloid process with atypical facial neuralgia.

Styloid process and stylohyoid ligament are in close contact with parapharyngeal anatomical space in which beside the common carotid artery (CCA) the internal jugular

vein, glossopharyngeal, facial, vagal and hypoglossal nerve are located.

Stylohyoid complex, which is formed by styloid process, stylohyoid ligament and lesser horn of hyoid bone (Figure 1), is embryologically derived from Reichert's cartilage of the second branchial arch.

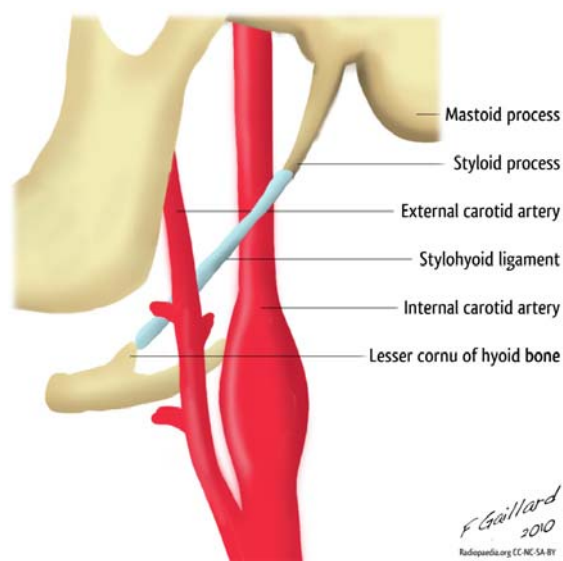


Fig. 1 – Stylohyoid complex anatomy.

Eagle defined physiological length of the styloid process to be 2.5–3.0 cm.

Diagnostic procedures used for the diagnosis of this syndrome are mainly used for the diagnosis of other diseases, and the diagnosis of an enlarged styloid process or calcification of the stylohyoid ligament is mostly the incidental finding. The radiologic diagnosis of the elongated styloid process is usually established during diagnoses of injuries and/or disease of the cervical spine. It is also evident that the styloid process can be clearly shown on the orthopantomography (OPT).

Definite diagnostic is performed with computerized tomography (CT) scan radiography with 3D reconstruction.

Elongated styloid process and/or ossified stylohyoid ligament can be found in only 4% of total population, of which only 4% to 10.3% has clinical symptoms of recurring pain in the region of the pharynx and the face. It is more common in females in the ratio 3 : 1².

Case report

Case 1

A 49-year-old male patient was sent to maxillofacial surgeon after examination of neurologist with symptoms of pain in the neck on the right side and painful swallowing, and pain was intensified during the movements of the neck. The case history noted that he had the same pain several years earlier but it spontaneously stopped and he did not contact the doctor. Using careful clinical examination and analysis of radiography, CT scan and OPT images the existence of elongation of the styloid process bilaterally was established

without involvement of the ligaments, and surgical treatment by intraoral approach was planned. Surgical treatment included entailed resection of elongated styloid process on the right side under general anesthesia. After the usual preoperative preparation unilateral right side styloidectomy by intraoral approach was made (Figure 2). Antibiotic therapy was prescribed. The postoperative period passed regularly, the wound healed without any signs of infection. The patient was discharged on the third postoperative day. Regular postoperative control showed no complaints.

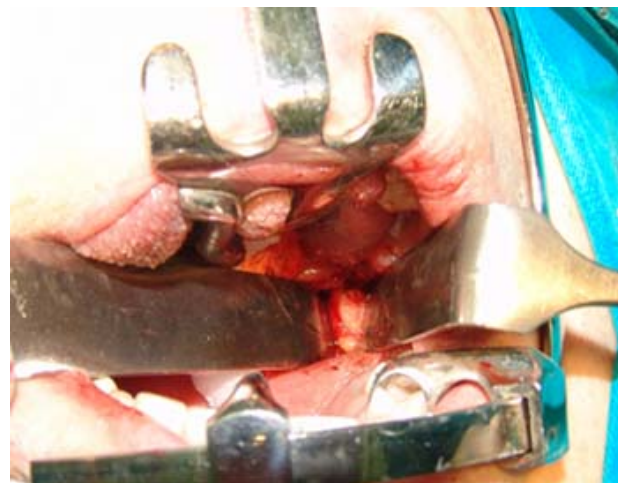

Fig. 2 – Intraoral approach to styloid process.

Case 2

A 34-year-old male patient was sent to the maxillofacial surgeon from the dermatologist. The OPT was made as a part of the dental diagnostics performed during the procedure of finding the causes of alopecia that occurred a few months earlier. OPT showed elongated styloid process on the right side (Figure 3).

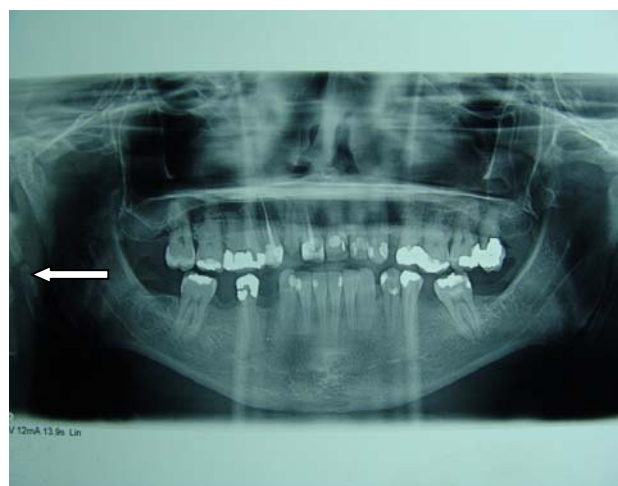


Fig. 3 – Orthopantomography of the patient with Eagle's syndrome.

The patient was sent to the maxillofacial surgeon. The patient complained of pain in the neck on the right side and difficult swallowing, earlier on both sides and at the moment

of examination more on the right. The patient denied earlier surgical intervention. CT scan with 3D reconstruction revealed the elongated right styloid process (62 mm length, 5 mm wide, with slight angulation of 20° right stylohyoid ligament) while the length of the left styloid process was 49 mm and the width of about 4 mm (Figure 4). The treatment plan included right styloidectomy under general anesthesia, and because of the length of the process and involvement of stylohyoid ligament, it was decided to approach it extraorally (Figures 5 and 6). Antibiotic therapy was administered preoperatively. Surgery under general anesthesia and postoperative period passed regularly, and the patient was discharged on the third postoperative day. At regular postoperative examinations the patient was subjectively without complaints.

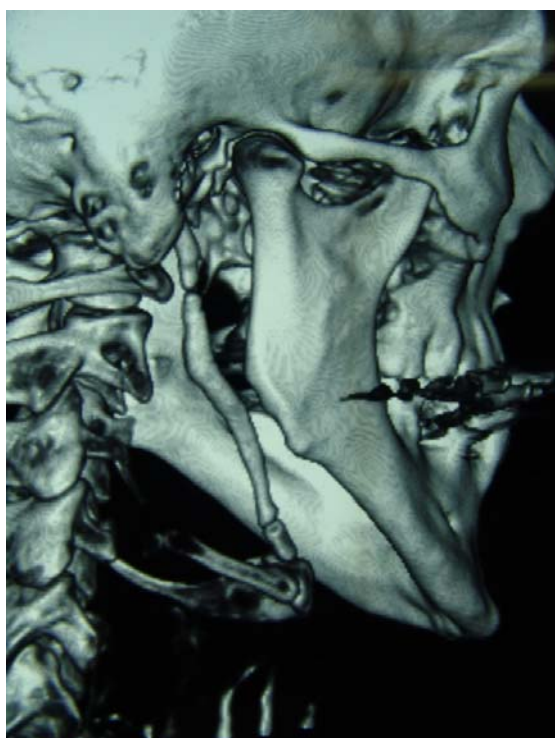

Fig. 4 – Computed tomography scan with 3D reconstruction in Eagle's syndrome.

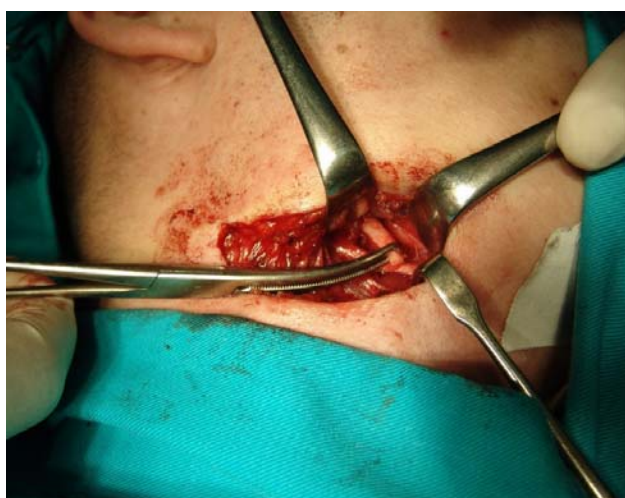

Fig. 5 – Extraoral approach to styloid process.

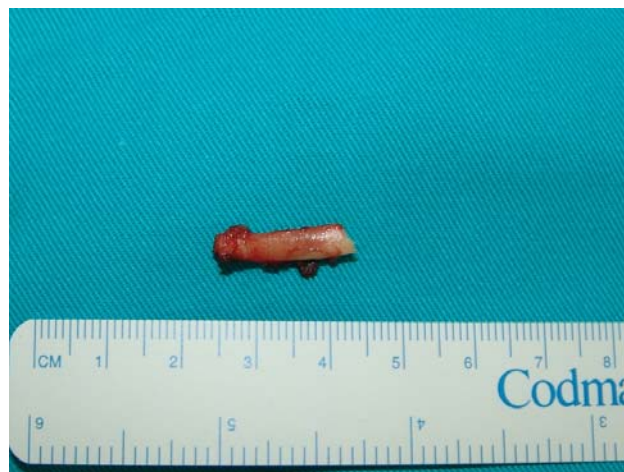

Fig. 6 – The resected styloid process.

Discussion

The styloid process, stylohyoid ligament and lesser horn of hyoid bone make stylohyoid complex, which is embryologically derived from Reichert's cartilage of the second branchial arch. The styloid process is located on the basis of the temporal bone behind the mastoid, it is positioned antero-inferiorly relative to the lower aspect of the temporal bone. It is placed between the parotid gland laterally and the internal jugular vein medially, passes between the external and internal carotid arteries and reaches the lateral wall of the pharynx. Cranial nerves: *n. hypoglossus*, *n. vagus* and *n. glossopharyngeus* are placed medially to the styloid process. On the styloid process *m. stylohyoideus*, *m. styloglossus* and *m. stylopharyngeus*, stylohyoid and stylomandibular ligament are attached³.

The normal length of the styloid process may vary. Eagle⁵ defined normal length of styloid process in the range from 25 to 30 mm. Kaufman et al.⁶ believe that the normal length is up to 30 mm while in some other papers 40 mm was mentioned as the upper limit^{7,8}. From the radiological point of view the normal styloid process length is 25 mm (the length along the posterior aspect of the styloid process from the base to peak is measured)⁹.

Elongated styloid process can be classified into three types according to Langlias et al.¹⁰: uninterrupted styloid process; styloid process with pseudoarthrosis between the styloid process and stylohyoid ligament; segmental interrupted stylohyoid ligament that gives the appearance of multiple pseudoarthrosis.

Eagle's syndrome is most common in the third and fourth decade, slightly more often in women (ratio women : men is 3 : 1) and more often bilateral than unilateral although bilateral symptoms do not necessarily occur. We described a case of bilateral and a case of unilateral elongated styloid process, both patients were men in the fourth and fifth decade with unilateral (right side) symptoms.

Patients can develop different symptoms because of elongation of styloid process or calcification of stylohyoid ligaments, in the form of non-specific neck pain, pain in the

ear and mastoid region that is amplified during the movements of the neck, dysphagia or odynophagia with the feeling of a foreign body in the throat, vertigo and tinnitus. Eagle⁴ described two syndromes which are related to the elongation of the styloid process. Normally, classic Eagle's syndrome, which is seen in patients after pharyngeal injuries during tonsillectomy, followed by constant dull pain, a patient as the epicenter pain alleges the tonsillar region, pain spreads to the ear when patient rotates the head. Pain increases with pressure in tonsillar region. Among other symptoms, there is pain when swallowing, feeling of a foreign body in the mouth (pharynx), ringing in the ears (tinnitus) or pain spreading to the face and neck region. The other form of Eagle's syndrome, also called stylocarotid syndrome, is not associated with pharyngeal injuries, and symptoms such as pain are the result of mechanical irritation and compression of perivascular sympathetic nerve fibers in the wall of the external and internal carotid arteries. Pain spreads along the blood vessel in the neck, during the rotation or pressure in the neck, and extends in the supraorbital region and the parietal region (because of pressure on the internal carotid artery), or to the infraorbital region (because of the pressure on external carotid artery).

The etiology of this syndrome is still causing debate. Eagle^{1,5} believed that surgical injury (tonsillectomy) leads to osteitis, periostitis or tendinitis of stylohyoid complex with subsequent ossification. The presence of mesenchymal elements in the stylohyoid complex (Reichert's cartilage) may under the influence of trauma and mechanical stress lead to metaplasia of the bone. There are different theories of the cause of ossification of stylohyoid ligament (reactive hyperplasia, reactive metaplasia, both based on post-traumatic response of the body, and the theory of anatomical variations, based on anatomical variations without previous injury)¹¹. Bafaqeeh¹² considers that ossification is associated with the endocrine disorders in menopausal women, which lead to ligament ossification. Elevated serum calcium, phosphorus and vitamin D metabolism disorder encountered in end-stage renal disease can lead to calcification of stylohyoid ligament.

Although Eagle⁵ believed that tonsillectomy is responsible for the appearance of ossification of styloid process, Eagle's syndrome occurs in people who had no surgical procedures in the region.

The diagnosis is based on detailed anamnesis, clinical examination and radiological examination (OPT, lateral radiography by Eissler, CT scan with 3D reconstruction). The elongated styloid process and its deviation can be seen clearly on OPT, but for the diagnosis of Eagle's syndrome CT with 3D reconstruction is most significant, because it allows measurement of the length of styloid process and determination of its relationship with other structures of the head and neck, which is most important for surgical planning¹³.

Based on the density of calcification the elongated styloid process can be radiologically classified into: marginally calcified (calcification occurs in the outer part while in the center of process lightening is seen that occurs in most cases); partially calcified; nodular complexes; completely calcified¹⁰.

The differential diagnosis includes: diseases of the temporomandibular joint, hyoid bursitis, glossopharyngeal and sphenopalatine neuralgia, esophageal diverticulum, migraine,

temporomandibular arteritis, myofascial pain syndrome, cervical arthritis, otitis, diseases of the salivary glands, impacted third molar, tumors, etc.¹⁴⁻¹⁶.

Treatment of Eagle's syndrome can be a conservative and surgical.

Our experience presented in this paper is based on the surgical treatment.

Conservative treatment advocated by Evans and Clairmont¹⁷ (symptomatic therapy similar for treatment of trigeminal neuralgia) involves the use of non-steroidal anti-inflammatory drugs, corticosteroids (corticosteroid and anesthetic injection in the region of the lesser horn of hyoid bone or the lower aspect of the tonsillar lodge), anticonvulsants, antidepressants, physical treatments and exercises for the neck.

Surgical treatment involves styloidectomy (removal of elongated styloid process) extraorally or intraorally. The success of both surgical techniques is 93.4%¹³.

Intraoral technique is simpler, takes less time and avoids the surgical scar, but can lead to infection of deep neck spaces, injury of the blood vessels and one of the disadvantage is poor visualization of the operative field. It is not recommended to made styloidectomy for both sides intraorally in the same act due to high postoperative discomfort for the patient^{18,19}.

Extraoral technique involves access through cervical incision. This approach allows better visualization of the surgical field. This technique, however, takes longer time, there is a risk of injury of the facial nerve, the patient postoperatively recovery is longer and the postoperative scar is visible. Extraoral approach is reserved for patients who have extreme ossification, practically the entire ligament – from the styloid process to the hyoid bone. It is considered reasonable in such cases since it avoids the risk of intraoral access and iatrogenic injury to the neurovascular structures²⁰⁻²².

It is estimated that the success of treatment of Eagle's syndrome (both conservative and surgical) is more than 80%. It is believed that treatment failure is associated with the presence of the other factors involved in the pathogenesis of this syndrome.

Conclusion

In patients with orofacial pain, neck pain, dysphagia and pain in the temporomandibular joint area it is needed to pay attention to the existence of elongated styloid process. Careful clinical examination, palpation of the mastoid region and tonsillar fossa and additional imaging methods (orthopantomography and computerized tomography diagnostics) can confirm the agnosis of elongated styloid process.

Surgical techniques for treatment of Eagle's syndrome have many advantages and disadvantages. It is considered that the length of the styloid process or the calcified ligament is a decisive parameter for the selection of techniques and approaches.

If the styloid process is augmented (extended) without involvement of the ligament, it is considered that is better and easier to use intraoral approach. If the stylohyoid ligament is calcified, and it is necessary to remove a structure that extends to the hyoid bone, it is considered that it is safer to use the extraoral approach.

R E F E R E N C E S

1. *Eagle WW*. Elongated styloid process. Report of two cases. *Arch Otolaryngol* 1937; 25: 584–7.
2. *Gaillard F*. Styloid apporatus. 2010. Available at website: www.radiopaedia.org/images410772
3. *Fini G, Gasparini G, Filippini F, Becelli R, Marcotullio D*. The long styloid process syndrome or Eagle's syndrome. *J Cranio Maxillofac Surg* 2000; 28: 123–7.
4. *Moffat DA, Ramsden RT, Shaw HJ*. The styloid process syndrome: aetiological factors and surgical management. *J Laryngol Otol* 1977; 91(4): 279–94.
5. *Eagle WW*. Elongated styloid process; further observations and a new syndrome. *Arch Otolaryngol* 1948; 47(5): 630–40.
6. *Kaufman SM, Elzay RP, Irish EF*. Styloid process variation. Radiologic and clinical study. *Arch Otolaryngol* 1970; 91(5): 460–3.
7. *Monsour PA, Young WG*. Variability of the styloid process and stylohyoid ligament in panoramic radiographs. *Oral Surg Oral Med Pathol* 1986; 61(5): 522–6.
8. *Balcioglu HA, Kilic C, Akyol M, Ozan H, Kokten G*. Length of the styloid process and anatomical implications for Eagle's syndrome. *Folia Morphol (Warsz)* 2009; 68(4): 265–70.
9. *More CB, Asrani MK*. Eagle's syndrome: report of three cases. *Indian J Otolaryngol Head Neck Surg* 2011; 63(4): 396–9.
10. *Langlais RP, Miles DA, van Dis ML*. Elongated and mineralized stylohyoid ligament complex: a proposed classification and report of a case of Eagle's syndrome. *Oral Surg Oral Med Oral Pathol* 1986; 61(5): 527–32.
11. *Gokec C, Sisman Y, Sipahioglu M*. Styloid Process Elongation or Eagle's Syndrome: Is There Any Role for Ectopic Calcification. *Eur J Dent* 2008; 2(3): 224–8.
12. *Bafaqueeb SA*. Eagle syndrome: classic and carotid artery types. *J Otolaryngol* 2000; 29(2): 88–94.
13. *Ceylan A, Köybaşıoğlu A, Celenk F, Yılmaz O, Uslu S*. Surgical treatment of elongated styloid process: experience of 61 cases. *Skull Base* 2008; 18(5): 289–95.
14. *Blythe JN, Matthews NS, Connor S*. Eagle's syndrome after fracture of the elongated styloid process. *Br J Oral Maxillofac Surg* 2009; 47(3): 233–5.
15. *Koivumäki A, Marinescu-Gava M, Järnstedt J, Sándor GK, Wolff J*. Trauma induced eagle syndrome. *Int J Oral Maxillofac Surg* 2012; 41(3): 350–3.
16. *Klécha A, Hafian H, Devauchelle B, Lefèvre B*. A report of post-traumatic Eagle's Syndrome. *Int J Oral Maxillofac Surg* 2008; 37(10): 970–2.
17. *Evans JT, Clairmont AA*. The nonsurgical treatment of Eagle's syndrome. *Eye Ear Nose Throat* 1976; 55(3): 94–5.
18. *Chrcanovic BR, Custódio AL, de Oliveira DR*. An intraoral surgical approach to the styloid process in Eagle's syndrome. *Oral Maxillofac Surg* 2009; 13(3): 145–51.
19. *Raichandbhury R*. The extra-yonsilar approach to the styloid process. *Br J Oral Maxillofac Surg* 2011; 49(6): e40–1.
20. *Chase DC, Zarmen A, Bigelow WC, McCoy JM*. Eagle's syndrome: a comparison of intraoral versus extraoral surgical approaches. *Oral Surg Oral Med Oral Pathol* 1986; 62(6): 625–9.
21. *Martin TJ, Friedland DR, Merati AL*. Transcervical resection of the styloid process in Eagle syndrome. *Ear Nose Throat J* 2008; 87(7): 399–401.
22. *Diamond LH, Cottrell DA, Hunter MJ, Papageorge M*. Eagle's syndrome: a report of 4 patients treated using a modified extraoral approach. *J Oral Maxillofac Surg* 2001; 59(12): 1420–6.

Received on December 18, 2013.

Revised on February 24, 2014.

Accepted on February 27, 2014.