



## Overlooked retained intraocular foreign body

### Previđeno zaostalo intraokularno strano telo

Antoaneta Adžić-Zečević\*, Edita Files-Bradarić†, Mirjana Petrović‡

\*University Eye Clinic, Podgorica, Montenegro; †Optimal Eye Hospital, Podgorica, Montenegro; ‡University Eye Clinic, Kragujevac, Serbia

#### Abstract

**Introduction.** The most common cause for litigation against ophthalmologists in a trauma case is a missed intraocular foreign body (IOFB). IOFBs cause internal eye damage, but some will come to rest in the posterior segment of the eye. **Case report.** We presented a 57-year-old male who was referred to the ophthalmologist due to decreased visual acuity in his left eye. Slit lamp examination of his left eye showed no pathological findings. Goldmann contact lens examination showed IOFB which was lying in the vitreous body in the inferior-temporal region. Retinal rupture was noticed at 7 o'clock. The optical coherence tomography (OCT) examination was performed and it showed atrophic macular area as well as decreased peripapillary retinal fiber layers thickness. Ultrasound showed the IOFB in vitreous body cavity. History revealed that the patient had an accidental trauma, 48 years ago, when an old bomb from World War II (WWII) exploded. Due to the decrease in visual acuity and fibrosis of the vitreous body surgical intervention was performed on his left eye (phacoemulsification with intraocular lens implantation, *pars plana* vitrectomy and instrumental extraction of foreign body). **Conclusion.** The intraocular foreign body (IOFB) was asymptomatic for 48 years. Symptoms depend on material and localization of the foreign body and the type of injury.

#### Key words:

eye foreign bodies; diagnosis; ophthalmologic surgical procedures; treatment outcome.

#### Apstrakt

**Uvod.** Najčešći uzrok sudskih sporova protiv oftalmologa u slučaju traume je previđeno strano telo. Intraokularna strana tela izazivaju unutrašnja očna oštećenja, ali neka od njih mogu da ostanu mirna u zadnjem segmentu oka. **Prikaz bolesnika.** Prikazan je 57-ogodišnji muškarac koji je upućen oftalmologu zbog sniženja vidne oštine na levo oko. Pregled levog oka procepnom lampom nije pokazao patološke nalaze. Pregled Goldmanovom lupom pokazao je intraokularno strano telo, koje je ležalo u staklastom telu u donjetemporalnom segmentu. Ruptura retine, uočena je na 7 časova. Pregled optičkom koherentom tomografijom ukazao je na atrofičnu makularnu oblast i smanjenu debljinu peripapilarnih retinalnih nervnih vlakana. Ultrazvukom levog oka ustanovljeno je strano telo u staklastom telu. Istorija lečenja bolesnika ukazala je na traumu, pre 48 godina, kada je stara bomba iz Drugog svetskog rata eksplodirala. Zbog sniženja vidne oštine i fibroze staklastog tela urađena je hirurška intervencija (fakoemulzifikacija sa ugradnjom intraokularnog sočiva, *pars plana* vitrektomija i instrumentalno odstranjenje stranog tela). **Zaključak.** Intraokularno strano telo bilo je asimptomatsko 48 godina. Simptomi zavise od materijala i lokalizacije stranog tela i od tipa povrede.

#### Ključne reči:

oko, strana tela; dijagnoza; hirurgija, oftalmološka, procedure lečenje, ishod.

#### Introduction

The frequency of ocular traumas varies between 7 and 9.22% in regard to a total number of all body injuries. The most common cause for litigation against ophthalmologists in a trauma case is a missed intraocular foreign body (IOFB). Commonly injured structures include the cornea, the lens and the retina. IOFBs cause internal eye damage, but some will come to rest in the posterior segment of the eye<sup>1</sup>.

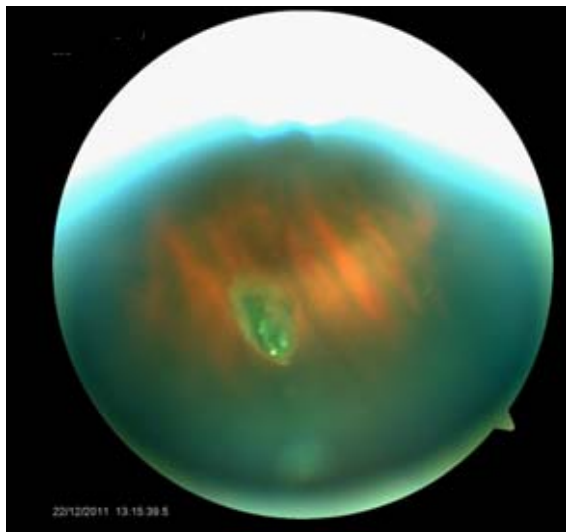
Ocular injuries with foreign body are highly associated with severe ocular damage requiring extensive surgical repair or evisceration/enucleation. IOFB is a common cause of poor anatomical (atrophic eyeball) and visual outcome (amaurosis)<sup>1,2</sup>.

IOFB could be easily overlooked if there are no symptoms such as inflammatory sign, diplopia, pain, etc. The identification of IOFB can be quite challenging clinically.

**Case report**

We presented a 57-year-old male who had an explosive injury in the right side of the body (right eye and right hand) long ago, but at the same time he had an injury in the left eye caused by a metallic foreign body, too. He lived for 48 years with an asymptomatic IOFB in his left eye. History revealed that he had an accidental trauma 48 years ago when an old bomb from World War II (WWII) exploded. In that accident, he got numerous face injuries, including the left eye.

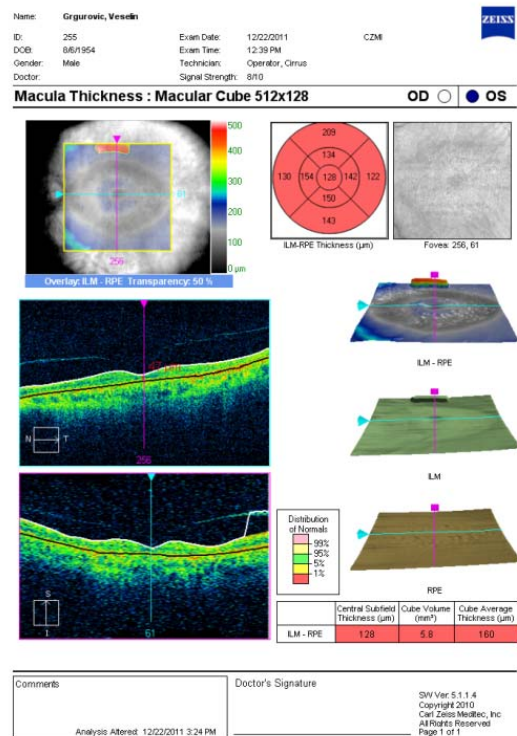
He was referred to ophthalmologist due to decreased visual acuity in the left eye and unpleasant flashing lights. Test results were as follows: visual acuity VOD = amaurosis, VOS = cc 0.3; ocular pressure TOD = N (dig), TOS = 18 mmHg. Slit lamp examination showed that there was a big corneal scar in the anterior segment of the right eye, but deeper areas were unreachable and the right eye was atrophic. Slit lamp examination of his left eye showed no pathological findings. There were no scars in eyelids or in the anterior segment of the left eye. Goldmann examination showed IOFB unnoticed until then in the vitreous body of the left eye. Photo-fundus (45°) of his left eye was normal, but ophthalmoscopic examination showed an IOFB (Figure 1) lying free in the vitreous body in inferior and temporal parts near to optic nerve head (at 7 o'clock).



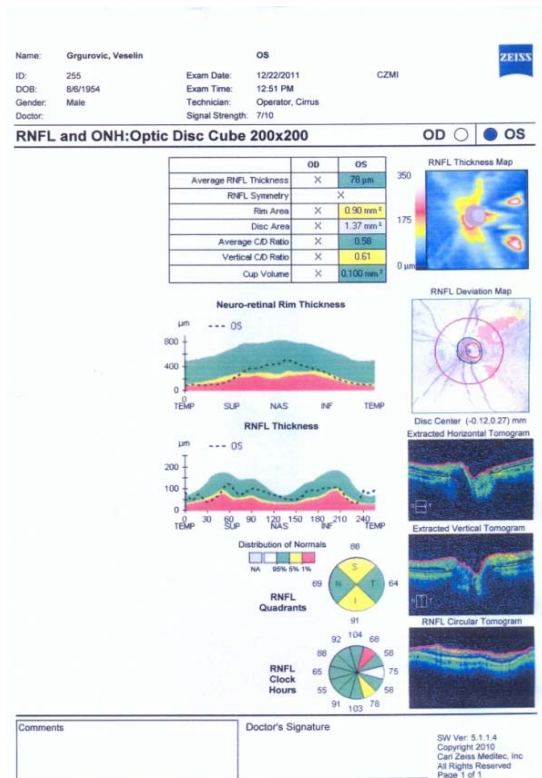
**Fig. 1 – Intraocular foreign body (IOFB) in vitreous body of the left eye.**

Retinal rupture was noticed at 7 o'clock. Optical coherence tomography (OCT) examination was performed and it showed atrophic macular area as well as decreased peripapillary retinal fiber layers thickness (Figures 2 and 3). Ultrasound of the left eye showed the IOFB in vitreous body cavity (Figure 4). The patient had complaints on persistent discomfort in his left eye since then. He was examined several times by ophthalmologists during the past period, but nobody noticed an IOFB. Due to the decrease in visual acuity and fibrosis of the vitreous body surgical intervention was performed on his left eye (phacoemulsification with intraocular lens implantation, *pars plana* vitrectomy and instrumental extraction of IOFB). The extracted foreign body was 1.8 mm

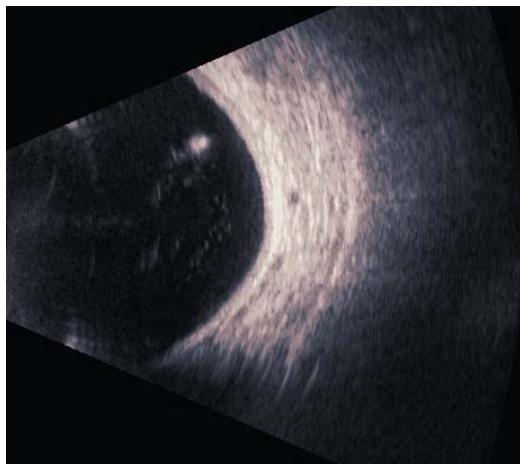
in length. Endolaser photocoagulation was performed for a retinal rupture. Postoperative visual acuity in the left eye was VOS = 0.7.



**Fig. 2 – Optical coherence tomography (OCT) findings of the left eye macula.**



**Fig. 3 – Optical coherence tomography (OCT) finding of the left optic nerve head.**



**Fig. 4 – Ultrasound of the left eye with intraocular foreign body.**

### Discussion

Careful history examination will help in finding asymptomatic IOFB. Symptomatology of IOFB can be various. Symptoms depend on the material a foreign body consists, localization of the body and type of injury. Rarely, when an IOFB completely enters the eye, its presence can be asymptomatic<sup>3</sup>.

It is well-known that computed tomography (CT) scans or X-rays should represent initial imaging tests performed for metallic IOFB because magnetic resonance imaging (MRI) testing on these patients may result in blindness.

Reviewing the literature of diagnosis and management of traumatic IOFBs is presented together with the schematic “flight plan” to assist in clinical decision making when confronted with the IOFB<sup>4</sup>.

There was a study of demographic profile, causes, type of ocular injuries, severity, complications and final visual outcome following the Deepawali festival fireworks in India. Factors associated with poor visual outcome included poor initial visual acuity. Poor visual outcome was associated with poor initial visual acuity and retinal detachment, as in our case, too, if analyzing the state of the right eye<sup>5</sup>.

Many authors reported injury patterns, management strategies and outcomes for eye injuries in British Armed Forces in Iraq and Afghanistan. Primary repair can be safely delayed

beyond 24 hours in patient's best interests, in order to optimize the conditions for treatment, the opinion we also share<sup>6</sup>.

Ranking among the most severe combat damages, war-related open-globe injuries (WROGI) are not uniform, so the treatment approaches are unclear. The essential issue is to define exact indications for time and resource - intensive vitreoretinal surgery (VRS) known to be an effective procedure for severe posterior segment injuries. The authors studied WROGI structure and summarized experience of specialized ophthalmologic care management during local armed conflicts. Treatment should be determined by the diagnosis, because this damage determines only the choice of enucleation/evisceration of the eye<sup>7</sup>.

Eye injuries represent one of the biggest problems in eye surgery throughout the world, including our country. Vitreoretinal operations are the most prevailing in treatment of serious eye injuries. *Pars plana* vitrectomy is the most common method of surgical treatment of eye injuries with IOFB<sup>8</sup>. War eye injuries are a specific group of injuries. A relatively low percentage of posttraumatic endophthalmitis is definitely worth attention, especially in comparison with peacetime eye penetrating injuries with IOFB<sup>9</sup>.

In our case IOFB was asymptomatic (overlooked) for several decades, due to the nature of material, location and shape of the foreign body. Diagnostic capabilities before 48 years were limited to diagnostic X-rays, and today they are facilitated with the use of ultrasound diagnostic for comprehensive and easier localization and verification of IOFBs.

### Conclusion

In the presented case, intraocular foreign body was asymptomatic for 48 years. Nobody had noticed intraocular foreign body when examining the patient because of flashing lights. This symptom was a sign of retinal rupture. In our case, intraocular foreign body was clearly presented in ultrasound and additional imaging tests were unnecessary. Surgical treatment was performed due to the decrease in visual acuity and fibrosis of vitreous body. *Pars plana* vitrectomy is the most common method of surgical treatment of eye injuries with intraocular foreign body.

### R E F E R E N C E S

1. Erdurman FC, Hurmeric V, Gokce G, Durukan AH, Sobaci G, Altinsoy HI. Ocular injuries from improvised explosive devices. *Eye* 2011; 25(11): 1491–8.
2. Luo Z, Gardiner M. The incidence of intraocular foreign bodies and other intraocular findings in patients with corneal metal foreign bodies. *Ophthalmology* 2010; 117(11): 2218–21.
3. Minoda R, Aoyama T, Kumai Y, Murakami D, Hirai T, Yumoto E. An asymptomatic intraorbital foreign body for 30 years. *Auris Nasus Larynx* 2013; 40(4): 417–9.
4. Parke D, Flynn HW, Fisher YL. Management of intraocular foreign bodies: a clinical flight plan. *Can J Ophthalmol* 2013; 48(1): 8–12.
5. Malik A, Bhala S, Arya SK, Sood S, Narang S. Five-year study of ocular injuries due to fireworks in India. *Int Ophthalmol* 2013; 33(4): 381–5.
6. Blanch RJ, Bindra MS, Jacks AS, Scott RA. Ophthalmic injuries in British Armed Forces in Iraq and Afghanistan. *Eye* 2011; 25(2): 218–23.
7. Boiko EV, Churashov SV, Haritonova NN, Budko AA. Vitreoretinal surgery in the management of war-related open-globe injuries. *Graefes Arch Clin Exp Ophthalmol* 2013; 251(3): 637–44.
8. Vukosanljević M. Surgical treatment of eye injuries in five-year survey period. *Srp Arh Celok Lek* 2006; 134(5–6): 187–90. (Serbian)
9. Vukosanljević M. Management of penetrating ocular injuries and endophthalmitis in thirteen-year follow-up period. *Srp Arh Celok Lek* 2006; 134(9–10): 375–9. (Serbian)

Received on February 6, 2014.

Revised on April 8, 2014.

Accepted on April 9, 2014.