



Specificity of treatment is mandatory in very old patients with hairy cell leukemia

Specifičnost lečenja je neophodna kod vrlo starih bolesnika sa leukemijom vlasastih ćelija

Dragomir Marisavljević*†, Olivera Marković*†, Radmila Živković*

*Clinical Hospital Center “Bežanijska kosa”, Belgrade, Serbia; †Faculty of Medicine, University of Belgrade, Belgrade, Serbia

Abstract

Introduction. There are only a few available data about hairy cell leukemia (HCL) in very old patients. We presented three very different cases of HCL in very old patients diagnosed in a single center and discussed some epidemiological and therapeutical issues in such patients. **Case report.** The first patient, 89-year-old, had symptomatic cytopenia and achieved sustained complete remission after cladribine treatment. The second patient, 89-year-old, had asymptomatic disease with stable full blood counts during a 3-year follow-up period in which watch-and-wait policy was adopted. The third patient, 82 years old, had two malignancies (HCL and presumably metastatic colorectal carcinoma) and his only treatment were occasional red blood cell transfusions and symptomatic therapy. **Conclusion.** The presented illustrative examples confirm individualization of treatment is mandatory in very old patients with HCL.

Key words: leukemia, hairy cell; aged, 80 and over; therapeutics; prognosis.

Apstrakt

Uvod. U literaturi postoji vrlo malo podataka o leukemiji vlasastih ćelija (*hairy cell leukemia* – HCL) kod vrlo starih osoba. Prikazali smo tri vrlo stara bolesnika sa vrlo različim tokom HCL dijagnostikovanim u jednom centru i razmotrili epidemiološke i terapijske aspeke ove bolesti u grupi vrlo starih bolesnika. **Prikaz bolesnika.** Prvi bolesnik, star 89 godina, imao je simptomatsku citopeniju i postigao kompletnu remisiju nakon lečenja kladribinom. Drugi bolesnik, star 89 godina, imao je asimptomatsku bolest sa stabilnom krvnom slikom tokom trogodišnjeg perioda praćenja, zbog čega je primenjena “*watch-and-wait*” strategija lečenja. Treći bolesnik, star 82 godine, imao je dva maligniteta (HCL i metastatski kolorektalni karcinom) i njegovo lečenje je uključivalo samo povremenu primenu transfuzija koncentrovanih eritrocita i simptomatsku terapiju. **Zaključak.** Prikazani ilustrativni primeri bolesnika potvrđuju neophodnosti individualnog terapijskog pristupa kod vrlo starih bolesnika sa HCL.

Ključne reči: leukemija vlasastih ćelija; stare osobe, 80 i više godina; lečenje; prognoza.

Introduction

Hairy cell leukaemia (HCL) is an indolent neoplasm of small mature B lymphoid cells with oval nuclei and abundant cytoplasm with irregular projections (hairy) involving peripheral blood and diffusely infiltrating the bone marrow and splenic red pulp¹. HCL is characterized by splenomegaly, pancytopenia, and infiltration of the bone marrow with lymphocytes that have irregular cytoplasmic projections when identified in the peripheral blood¹. At the time of diagnosis, most patients manifested symptoms related to anemia, neutropenia, throm-

bocytopenia, or splenomegaly. Approximately 25% of patients manifested fatigue or weakness, 25% manifested infection, and 25% were present because of the incidental discovery of splenomegaly or an abnormal peripheral blood count². Blood film and bone marrow examination are essential for the diagnosis of HCL. Immunohistochemistry of the marrow trephine specimens should include CD20 and DBA44³.

There are no available data about the incidence of HCL in very old patients. We presented three very different cases of HCL in very old patients and discussed some epidemiological and therapeutical issues in such patients.

Case report

The first 89-year-old patient had the right neck femur fracture in January 2011 and was treated surgically. After the surgery, there were no complaints. Physical examination showed cardiac arrhythmia and arterial hypertension. His complete blood counts (CBC) showed pancytopenia: hemoglobin 121 g/L (normal range 130–180 g/L), white blood cells (WBC) $1.1 \times 10^9/L$ (normal range $4\text{--}10 \times 10^9/L$), absolute neutrophil count (ANC) $0.6 \times 10^9/L$ and platelets $37 \times 10^9/L$ (normal range $1.6\text{--}7.2 \times 10^9/L$). Biochemistry findings were normal. Ultrasonography of the abdomen revealed enlarged spleen (165×61 mm). He was admitted to the Hematology Department and trephine bone marrow biopsy was performed. Bone marrow examination revealed diffuse/interstitial infiltration with lymphoid cells (Figure 1). The cells were CD20+, with oval, round nuclei with small nucleolus and abundant light-grey cytoplasm. The marrow reticular fibrosis was gradus III. Morphologically, the diagnosis of HCL was established. The patient was treated in March 2011 with 2-chlorodeoxyadenosin (cladribine 0.14 mg/kg/day) *iv* infusion over two hours for 5 consecutive days. During and after the treatment period he had no infections, nor other complications. The complete remission was achieved. On the occasion of his last follow-up (January 2013), the patient felt well, without any complains and with normal hematological findings.

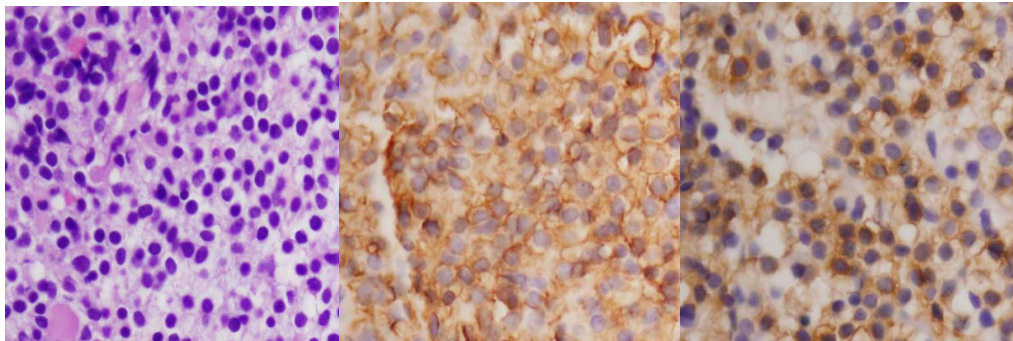


Fig. 1 – Histopathological finding of hairy cell leukemia in the bone marrow: hematoxyllin-eosin, $\times 400$ (left); CD20, $\times 400$ (center); DBA, $\times 400$ (right).

The second 89-year-old patient showed up in March, 2011, with the one year history of pancytopenia. He had been suffered from diabetes mellitus type II for 10 years, without complications. His complete blood counts showed: hemoglobin 102 g/L, WBC $4.0 \times 10^9/L$, ANC $1.1 \times 10^9/L$ and platelets $109 \times 10^9/L$. Other laboratory findings revealed elevated blood glucose (8.2 mmol/L – normal range 3.3–6.1 mmol/L). Ultrasonography of the abdomen showed enlarged spleen, 190 mm in diameter. Morphological examination of the bone marrow specimen led to the diagnosis of HCL, with the following immunophenotype: CD20+, CD79alfa+, CD3, CD5-, CD43+, CD23-, cyclin D1-, DBA44+, CD34-, CD117-, CD10-, BCL2+, BCL6-, MUM1-. Ki-67 was positive in 20% of the cells. The marrow reticular fibrosis was gradus II-III. Bearing in mind that the patient's CBC remained almost unchanged in the course of a 3-year follow-

up, we opted for the watch-and-wait approach. On the occasion of his last follow-up (January 2013), the patient was in a very good condition, without any complaints, still requiring no therapy.

The third 82-year-old patient was admitted to the Hematology Department in November 2011 with the history of pancytopenia in his blood count from February 2011 when he had a surgical intervention due to acute appendicitis. He complained of weight loss, malaise and dizziness. He also suffers from hypertension and cardiomyopathy. Laboratory evaluation showed bycytopenia (hemoglobin 64 g/L, WBC $1.4 \times 10^9/L$, ANC $0.3 \times 10^9/L$, platelets $154 \times 10^9/L$) and elevated sedimentation rate (120 mm/h; normal range $< 30/h$). The trephine marrow biopsy showed infiltration with hairy cells with following immunophenotype: TdT-, CD34-, CD117-, MPO-, lysosime-, glycophorine A-, PAX5+, CD20+, CD3-, BCL2+, DBA.44 +, CD43-, IgD-, CD68-. Biochemistry findings were normal. Ultrasonography of the abdomen showed the enlarged spleen (180 mm in diameter) and the enlarged liver (180 mm in diameter) with numerous secondary deposits (about 25 mm in average diameter). These findings were confirmed by computed tomography (CT) scan. CT scan also showed the thickness of the right colon wall. The patient refused colonoscopy and biopsy of the liver tumor. Regarding such decision of the patient, we decided not to treat him with specific anti-HCL therapy. He occasionally received red blood cell transfusions. On the oc-

casation of his last follow-up (December 2012), the patient was still alive.

Discussion

HCL is one of the rarest types of leukemia. The overall incidence is around 3 cases in million people *per* year, with a marked male preponderance (4 : 1)⁴. Over the past 30 years the incidence of this disease has not changed according to the largest population based study carried out on 3,104 HCL patients identified from 1973 through 2002 through the National Cancer Institute's Surveillance, Epidemiology and End Results (SEER) Program⁵. The median age at diagnosis is about 50 years³, although some national HCL registries reported higher median age value for onset of the disease^{6,7}. However, there are no precise literature data about incidence

of HCL in elderly persons. In the largest study of HCL in Serbia so far⁸, which included 46 patients, there were no patients older than 60 years. According to the report of Population Division DESA, United Nations, the patients older than 80 years belong to the so-called "oldest old" population, which is now about 1% of the total human population⁹.

Therefore, we were very surprised when diagnosed three patients older than 80 years in our hospital in the last few years. We believe that this was only a coincidence, not a change in epidemiological pattern of the disease in our country. Beside older age, clinical presentation of HCL in our patients was common: men with pancytopenia, splenomegaly and infiltration of the bone marrow with CD20+/DBA.44+ lymphocytes.

There is no widely agreed system for staging HCL, as well as for assessing prognostic factors. Heavy bone marrow infiltration and a large spleen will result in maximal degrees of cytopenia. Anemia (hemoglobin < 100 g/L), neutropenia (ANC < $1.0 \times 10^9/L$) and thrombocytopenia (platelets < $100 \times 10^9/L$) in any combination are associated with a relatively poor prognosis^{10,11}. An assessment of prognosis should include response to purine analogue therapy³. The main indications for treatment are symptomatic cytopenias or painful splenomegaly. If a patient is asymptomatic and cytopenia is minimal, it is reasonable to adopt watch-and-wait policy³. In our three patients we strictly followed current

guidelines for the HCL management³. The first patient with symptomatic cytopenia received specific therapy (cladribine) and achieved complete remission. In contrast, since the second patient appeared to be quite stable CBC during a 3-year follow-up period, we decided that active monitoring is the most appropriate clinical approach. In addition, this patient was currently 92 years old. The third patient had two malignancies (HCL and presumably metastatic colorectal carcinoma) and, therefore, his treatment was only supportive (occasional red blood cells transfusions) and symptomatic therapy. HCL has an increased risk of second tumors⁵. The relative risk of second cancers reported in various series of HCL patients ranged from 0.95 to 4.33, but simultaneous presentation of HCL and solid malignancies is very rare. Simultaneous presentation of HCL and solid malignancy is exceptional and only a few cases have been described¹²⁻¹⁴. It has been described synchronous occurrence of HCL with neuroendocrine colon carcinoma, HIV-negative Kaposi's sarcoma and signet ring carcinoma of the stomach¹²⁻¹⁴.

Conclusion

The presented cases are illustrative examples that individualization of treatment is mandatory in very old patients with hairy cell leukaemia.

R E F E R E N C E S

1. Golomb HM, Catovsky D, Golde DW. Hairy cell leukemia: A clinical review based on 71 cases. *Ann Intern Med* 1978; 89(5 Pt 1): 677-83.
2. Flandrin G, Sigaux F, Sebahoun G, Bouffette P. Hairy cell leukemia: clinical presentation and follow-up of 211 patients. *Semin Oncol* 1984; 11(4 Suppl 2): 458-71.
3. Jones G, Parry-Jones N, Wilkins B, Else M, Catovsky D. Revised guidelines for the diagnosis and management of hairy cell leukaemia and hairy cell leukaemia variant. *Br J Haematol* 2012; 156(2): 186-95.
4. Staines A, Cartwright RA. Hairy cell leukaemia: descriptive epidemiology and a case-control study. *Br J Haematol* 1993; 85(4): 714-7.
5. Hisada M, Chen BE, Jaffe ES, Travis LB. Second cancer incidence and cause-specific mortality among 3104 patients with hairy cell leukemia: a population-based study. *J Natl Cancer Inst* 2007; 99(3): 215-22.
6. Juliusson G, Samuelsson H. Swedish Lymphoma Registry. Hairy cell leukemia: epidemiology, pharmacokinetics of cladribine, and long-term follow-up of subcutaneous therapy. *Leuk Lymphoma* 2011; 2(Suppl 2): 46-9.
7. Kristinsson SY, Vidarsson B, Agnarsson BA, Haraldsdottir V, Olafsson O, Johannesson GM, et al. Epidemiology of hairy cell leukemia in Iceland. *Hematol J* 2002; 3(3): 145-7.
8. Gotić M. The importance of the immune phenotype of leukemic cells in patients with hairy cell leukemia [thesis]. Belgrade: Faculty of Medicine, University of Belgrade; 1998. (Serbian)
9. Department of Economic and Social Affairs population Division. World Population ageing: 1950-2050. New York: United Nations; 2001.
10. Maloisel F, Benboubker L, Gardembas M, Coiffier B, Divine M, Sebban C, et al. Long-term outcome with pentostatin treatment in hairy cell leukemia patients. A French retrospective study of 238 patients. *Leukemia* 2003; 17(1): 45-51.
11. Else M, Dearden CE, Matutes E, Garcia-Talavera J, Robotiner AZ, Johnson SA, et al. Long-term follow-up of 233 patients with hairy cell leukaemia, treated initially with pentostatin or cladribine, at a median of 16 years from diagnosis. *Br J Haematol* 2009; 145(6): 733-40.
12. Salemis NS, Piniadis D, Tsiambas E, Gakis C, Nakos G, Sambažiotis D, et al. Synchronous occurrence of neuroendocrine colon carcinoma and hairy cell leukemia. *J Gastrointest Cancer* 2011; 42(3): 131-6.
13. Perunicic-Jovanovic M, Djunic I, Tomin D, Terzić T, Jakovic L, Sokic A, et al. Simultaneous Presentation of Hairy Cell Leukemia and Metastatic Signet Ring Carcinoma of the Stomach Diagnosed by Bone Marrow Biopsy. *Appl Immunohistochem Mol Morphol* 2011; 19(3): 279-82.
14. Aydin SO, Eskazan AE, Aki H, Ozguroglu M, Baslar Z, Soysal T. Synchronous Detection of Hairy Cell Leukemia and HIV-Negative Kaposi's Sarcoma of the Lymph Node: A Diagnostic Challenge and a Rare Coincidence. *Case Rep Oncol* 2011; 4(3): 439-44.

Received on February 28, 2014.

Revised on April 20, 2014.

Accepted on May 6, 2014.