



## Hemangioma of uterine cervix associated with high-grade squamous intraepithelial lesion

Hemangiom grlića materice udružen sa skvamoznom intraepitelnom lezijom visokog stepena

Matilda Djolai<sup>\*†</sup>, Tamara Bošković<sup>\*†</sup>, Srdjan Djurdjević<sup>\*\*‡</sup>, Sandra Trivunić Dajko<sup>\*§</sup>, Bojana Andrejić Višnjic<sup>†</sup>, Ranko Rajović<sup>||</sup>

<sup>\*</sup>Clinical Center of Vojvodina, Novi Sad, Serbia; <sup>†</sup>Department of Histology and Embryology, <sup>‡</sup>Department of Gynecology and Obstetrics, <sup>§</sup>Department of Pathology, Medical Faculty, Novi Sad, University of Novi Sad, Novi Sad, Serbia; <sup>||</sup>Department of Science, Mensa Serbia, Center for Education NTC, Novi Sad, Serbia

### Abstract

**Introduction.** Benign, especially polypoid, lesions of the cervix are common in everyday work. Rare tumors of this region are vascular ones, particularly capillary and/or cavernous hemangiomas. Cervical hemangiomas are especially rare, usually asymptomatic and only one third of the cases is clinically manifested as vaginal bleeding, polyps, etc. **Case report.** We reported a 54-year-old postmenopausal female patient who had undergone conization due to high-grade squamous intraepithelial lesion (H-SIL). Microscopic analysis of slices confirmed the existence of dysplastic changes in the endocervical epithelium and in small part in the epithelium of the gland of H-SIL type. In 2 of 15 slices, within the walls of the cervix, dilated, amplified and abnormal blood vessels lined with endothelium were observed, vaguely limited by the surrounding connective tissue of lamina propria and smooth muscle wall of the cervix. According to the pathological characteristics, the change corresponded to the hemangioma. Both changes were completely removed. **Conclusion.** In comparison with the available literature data, the presented case is the first to describe the association of hemangioma and dysplastic changes in the endocervical epithelium. Hemangioma was incidentally discovered in the histological sections of the material after the conization in a postmenopausal women.

**Key words:** cervix uteri; hemangioma; uterine cervical dysplasia; comorbidity.

### Apstrakt

**Uvod.** Benigne, posebno polipoidne, lezije grlića materice česte su u svakodnevnom radu. Ređi tumori ove regije su vaskularni tumori, i to kapilarni i/ili kavernozi hemangiomi. Hemangiomi grlića materice posebno su retki, obično su asimptomatski, a tek u trećini slučajeva klinički se mogu manifestovati kao vaginalna krvarenja, polipi i dr. **Prikaz bolesnika.** Prikazana je bolesnica, stara 54 godine, kojoj je zbog skvamozne intraepitelne displazije visokog stepena (H-SIL) urađena konizacija. Mikroskopskom analizom isečaka potvrđeno je postojanje displastičnih promena u endocervikalnom epitelu i malim delom u epitelu žlezda tipa H-SIL. U 2 od 15 isečaka unutar zida grlića materice, uočeni su dilatirani, umnoženi i nepravilni krvni sudovi obloženi endotelom, nejasno ograničeni od okolnog veziva lamine proprije i glatke muskulature zida grlića materice. Prema patohistološkim karakteristikama promena je odgovarala hemangiomu. Obe promene su uklonjene u celosti. **Zaključak.** Prema nama dostupnoj literaturi, naš prikaz slučaja je prvi opisani slučaj udruženosti hemangioma i displastičnih promena endocervikalnog epitela. Hemangiom je slučajno ustanovljen na patohistološkim isečcima materijala dobijenog konizacijom kod žene u postmenopauzi.

**Ključne reči:** grlić materice; hemangiom; grlić materice, displazija; komorbiditet.

### Introduction

Benign vascular tumors and tumor-like lesions include a broad spectrum of clinical and pathological entities. There are

numerous histological classifications of hemangiomas according to the histological type of vascular spaces (capillary, cavernous, venous), localization (cutaneous, intramuscular, etc.), the dominant view of cells (epithelial, spindle cells, etc.), the patient's age

(juvenile, senile) and the biological behavior (true neoplasms, malformations, telangiectasia, reactive changes)<sup>1</sup>. This group of tumors does not include neoplasms with prominent vascular components (e.g. vascular leiomyoma).

Hemangiomas, along with lipomas, are the most common tumors of the skin and soft tissues. In the pediatric age, hemangiomas make more than 7% of all soft tissue tumors<sup>2</sup>. The tumors of the vascular origin in the female genital system are rare. Cavernous hemangioma of the cervix are extremely rare, benign lesions. To date, fewer than 50 cases have been reported<sup>3</sup>. Hemangioma of the uterine body in comparing of the cervix is more often and until 1988, 88 such cases had been described in professional literature<sup>4</sup>.

Typically, the histological picture of hemangiomas shows that they are composed of proliferated, irregularly shaped and well-differentiated blood vessels lined by the endothelium and surrounded by pericytic cells<sup>1,2,4</sup>.

### Case report

We presented a 54-year-old postmenopausal women with cervical hemangioma incidentally discovered after conisation provided by high grade squamous intraepithelial lesion (H-SIL).

On routine systematic examination, conducted one year before conization, the patient was inspected by the gynecologist. At the time of examination, the patient denied the existence of any symptoms. According to the patient's medical history she had two vaginal deliveries, two miscarriages and at that moment she was postmenopausal. After gynecological examination and colposcopy, suspected changes in the cervix was only observed which were iodine negative. For these fields, the gynecologist took a biopsy and endocervical curettage was done. Pathological analysis of the first material confirmed the existence of mild and moderate dysplasia of the endocervical epithelium and accompanying inflammation.

The bioptic material and curettage did not reveal another histopathological changes. In the upcoming period the patient was on control twice with repeated cytological analysis.

After the last gynecological examination the biopsy of cervical portion and endocervical curettage were performed again, at that moment the patient was 54-year-old, and the histopathological analysis pointed to a dysplasia, H-SIL of the surface epithelium of endocervix. Four months later, a cone biopsy was done and the material was sent to histopathological analysis.

It consisted of a cone clip from the wall of the cervix, 2 cm high and 2.8 cm in the diameter of the vaginal portion. The entire material was taken and divided into 15 slices. In the serial sections, the cervical wall had the usual macroscopic characteristics.

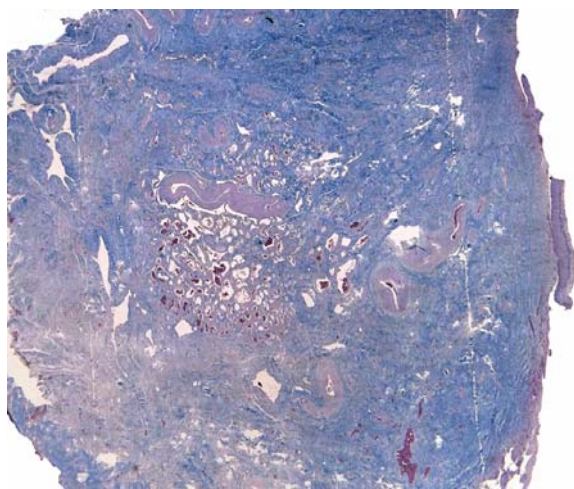
After the routine processing of the material [fixed in 10% formalin, cut to the thickness of 5 microns and stained with the hematoxylin-eosin (HE) method], it was histopathologically analyzed.

In just 2 from 15 specimens, there was a lesion unclearly distinguishable from the surrounding tissue and situated in the middle part of the cervical wall and with any contact by surface area and margins (Figure 1).

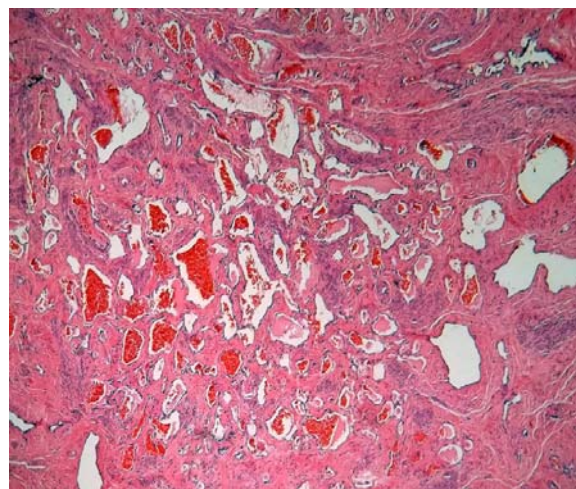
The lesion was made of proliferated and dilated blood vessels with a thin wall of a cavernous shape and by the erythrocytes into the lumen. The blood vessels covered by endothelial cells without atypical elements (Figure 2). Around the blood vessels, there was a proliferated and partly hyalinized connective tissue. After the analysis of the HE-stained histological sections, staining after the periodic acid schiff (PAS) and Mason methods was performed, which additionally visualized abnormal vessels and clearly defined their shape and size (Figure 3). Based on the described histological features, the diagnosis of cavernous hemangioma was made.

Each of the described changes, dysplastic epithelium and hemangioma, completely removed by conization.

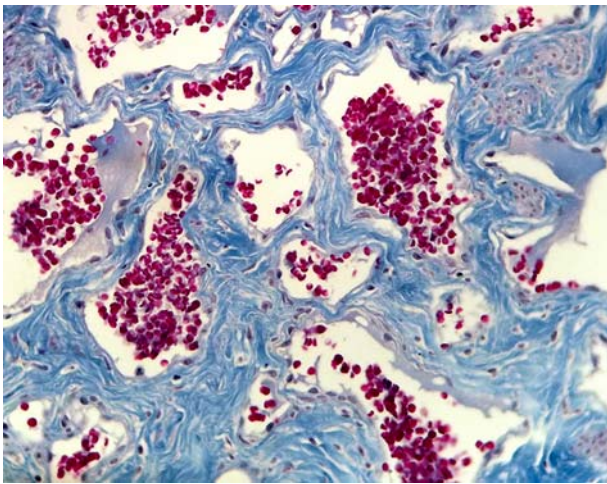
In the surface epithelium of the endocervical epithelium and glands, there was a stratified squamous epithelium with moderate and severe dysplasia (H-SIL) (Figure 4). A part of the surface endocervical epithelium was eroded.



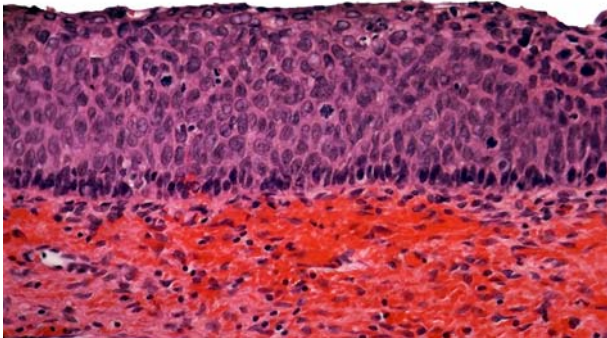
**Fig. 1 – Overview of the cervical wall and hemangioma (Masson, x20).**



**Fig. 2 – Abnormal blood vessels in the cavernous shape (HE, x40).**



**Fig. 3 – Abnormal blood vessels in the cavernous shape (Masson, ×40).**



**Fig. 4 – Dysplastic stratified squamous epithelium (HE, ×40).**

### Discussion

Hemangioma could involve either the uterine corpus and/or the cervix. The uterine body appears to be the more favored site<sup>5</sup>.

In the retrospective study of Gupta et al.<sup>6</sup> they presented 10 cases of vascular tumors of the female genital tract, and just one of them was cervical cavernous hemangioma which clinically have been presented as endocervical polyp. In another study, Andola and Andola<sup>7</sup> presented very similar results.

The first case of diffuse uterine hemangioma was described in 1897 as an incidental finding in a young woman after the delivery of twins<sup>8</sup>.

Compared with the hemangiomas of the uterine body, the isolated hemangioma of the cervix are even more uncommon<sup>9-12</sup> and were first described by Weed in 1948.

The traditional hemangiomas, including those of the female genital tract, are divided after their morphological characteristics into: capillary, cavernous and venous. Capillary hemangiomas are composed of numerous intertwining capillary sized vessels lined by the endothelium. When in lesions vascular channels are considerably engorged, then term cavernous hemangioma has been used. They differ from capillary hemangioma in that it is

less well circumscribed, is larger and is usually deeper in submucosal tissues, and because asymptomatic do not cause any deformation of the cervix (as in the presented case). Histologically, according to the literature, the cervical hemangiomas are usually of the cavernous type, as in our case<sup>13</sup>.

Hemangioma of the uterus is an mesenchymal tumor<sup>14</sup>. The origin of uterine hemangioma cells possibly represent pluripotent, embryonic mesodermal cells within the uterus<sup>8</sup>.

Hemangioma is also classified into congenital and acquired<sup>15,16</sup>. Kasznica and Nisar<sup>17</sup> in their paper showed a case of congenital vascular malformation of the uterus in autopsy of stillborn<sup>17</sup>. It was noted that approximately 73% vascular lesion are detectable at the birth and 85% are present in first year of life<sup>18</sup>.

Congenital hemangioma can be associated with hereditary diseases: Kippel-Trenaunay syndrome, hereditary hemorrhagic telangiectasia, tuberous sclerosis, blue rubber bleb nevus syndrome, Maffucci syndrome and Kasabach-Merritt syndrome<sup>15</sup>. There is a higher incidence of some vascular tumors caused by hereditary or genetic disorders, but in some hemangiomas their genetic basis cannot be determined<sup>10,18</sup>.

The cause of the development of acquired vascular tumors is still unclear. Some authors believe that hemangiomas of the female genital tract occur under the influence of hormonal contraceptives or due to pregnancy<sup>10</sup>.

Jung et al.<sup>14</sup> described a case of hemangioma of the cervix with focal nodular hyperplasia of the liver supported the view that uterine hemangioma is associated with exogenous hormone use that causes congenital vascular tumor. In another study, Boneti et al.<sup>12</sup> reported that the presence of estrogen receptors on the endothelial cells was related to the development of hemangioma. Typical acquired cases of uterine hemangioma are associated with previous pelvic surgery, endometrial curettage, trophoblastic disease, endometrial carcinoma and maternal ingestion of diethylstilbestrol<sup>8,14</sup>.

All hemangiomas have a limited power of proliferation<sup>1,2</sup>. Chou and Chang<sup>15</sup> have suggested that different immunophenotypic profiles may also be used to classify a hemangioma in different phases. Congenital hemangioma is usually in the proliferative phase. In this stage the endothelium is immature, plumper and SKI (v-ski sarcoma oncogene homolog) perinuclear positive. In acquired hemangioma, the endothelium is in the involuted phase.

The majority of hemangiomas of the uterine cervix are small and asymptomatic, so they are mostly discovered incidentally, during routine histopathological examination of the organ removed surgically, in the absence of gross lesion (such as in the case reported), or when this lesion is traumatized and/or ulcerated leading to clinical symptoms such as bleeding<sup>6</sup>.

Just in about 35% of the published papers, the cervical hemangiomas have clinical manifestations, such as: intermenstrual spotting, menometrorrhagia, post-menopausal metrorrhagia, postcoital metrorrhagia, dyspareunia – gynecological symptoms or obstetrical complications: premature rupture of membrane, the fetal death *in utero*, the postpartal haemorrhage and disseminated intravascular coagulation<sup>19</sup>.

Clinically, most cases have been reported in young pregnant women and the condition is very rare in postmenopausal pa-

tients, such is the reported case<sup>10,14</sup>. Mostly, symptomatic hemangioma was discovered in young and pregnant women, probably quick growth of the lesion in pregnancy may generate complications and symptoms<sup>20</sup>.

The differential diagnosis of hemangioma includes a cervical malignanat and benign tumors and tumor-like lesions.

Appropriate treatment form of hemangioma of the female genital tract remains unclear. Few cases in literature described conservative treatments, such as carbon dioxide laser excision, knife excision, cryotherapy, radiotherapy, electrocauterization, and uterine artery embolization, having been tried<sup>11</sup>.

Treatment of most hemanagioma is generally surgical: hysterectomy in 38% of cases was done or conservative therapy and local excision<sup>15,21</sup>.

### Conclusion

In comparison with the available literature data, the presented case is the first to describe the association of hemangioma and dysplastic changes in the endocervical epithelium. Hemangioma was incidentally discovered in the histological sections of the material after the conization in a postmenopausal women.

### R E F E R E N C E S

1. *Nucci MR, Oliva E.* Gynecologic Pathology. London: Churchill Livingstone Elsevier; 2009.
2. *Tavassoli FA, Devilee P.* WHO Pathology and Genetics. Tumors of the Breast and Female Genital Organ. Lyon: IARC Press; 2003.
3. *Ozyer S, Uzunlar O, Gocmen M, Bal S, Srvan L, Mollamahmutoglu L.* Cavernous hemangioma of the cervix: a rare cause of vaginal bleeding. *J Low Genit Tract Dis* 2006; 10(2): 107–8.
4. *Mastilović K, Rajović J, Žikić D, Stojiljković B.* Hemangioma of the uterus. *Arch Oncol* 2005; 13(3–4): 148–9.
5. *Virk RK, Zhong J, Lu D.* Diffuse cavernous hemangioma of the uterus in a pregnant woman: report of a rare case and review of literature. *Arch Gynecol Obstet* 2009; 279(4): 603–5.
6. *Gupta R, Singh S, Nigam S, Khurana N.* Benign vascular tumors of female genital tract. *Int J Gynecol Cancer* 2006; 16(3): 1195–200.
7. *Andola US, Andola SK.* Vascular tumours of the female genital tract: A clinicopathologic Study of 11 cases. *J Clin Diagnostic Res* 2011; 5(6): 1241–6.
8. *Johnson C, Reid-Nicholson M, Deligdisch L, Grinblat S, Natarajan S.* Capillary hemangioma of the endometrium: a case report and review of the literature. *Arch Pathol Lab Med* 2005; 129(10): 1326–9.
9. *Weed JC.* Hemangioma of the cervix. *AJOG* 1948; 56(5): 991–3.
10. *Gan AM, Durdi GS, Sherigar B, Patted SS, Malur PR.* Hemangioma of the cervix: a rare cause of postcoital bleeding. *South Afr J Gynecol Oncol* 2011; 3(1): 43–5.
11. *Benjamin MA, Yaakub H, Telesinghe P, Kafel G.* A rare case of abnormal uterine bleeding caused by cavernous hemangioma: a case report. *J Med Case Rep* 2010; 4(1): 136.
12. *Boneti LR, Boselli F, Lupi M, Bettelli S, Schirosi L, Bigiani N, et al.* Expression of estrogen receptor in hemangioma of the uterine cervix: reports of three cases and review of the literature. *Arch Gynecol Obstet* 2009; 280(3): 469–72.
13. *Dahiya N, Dahiya P, Kalra R, Marnab N, Jain S.* Cavernous hemangioma of uterine cervix - a rare cause of postcoital bleeding. *IJPSR* 2011; 2(5): 1209–11.
14. *Jung HR, Cho CH, Kwon SH, Kwon SY.* Cavernous hemangioma of the uterus in a postmenopausal woman - a case report. *Korean J Pathol* 2011; 45(5): 520–2.
15. *Chou WY, Chang HW.* Uterine hemangioma. *Arch Pathol Lab Med* 2012; 136(5): 567–71.
16. *Djunic I, Elezovic I, Ljubic A, Markovic O, Tomin D, Tadic J.* Diffuse cavernous hemangioma of the left leg, vulva, uterus, and placenta of a pregnant woman. *Int J Gynaecol Obstet* 2009; 107(3): 250–1.
17. *Kasznica J, Nisar N.* Congenital vascular malformation of the uterus in a stillborn: a case report. *Hum Pathol* 1995; 26(2): 240–1.
18. *Shanberge JN.* Hemangioma of the uterus associated with hereditary hemorrhagic telangiectasia. *Obstet Gynecol* 1994; 84(4 Pt 2): 708–10.
19. *Elkhabteb S, Idrissi MA, Laabadi K, Chbani L, Chaara H, Melbouf A.* Cavernous hemangioma of the uterine cervix and pregnancy: a case report. *Open J Obstet Gynecol* 2011; 1: 221–4.
20. *Mahapatra S, Das R, Sethy S.* A cavernous hemangioma of the uterine cervix during pregnancy. *Soth Afr J Gynecol Oncol* 2012; 4(2): 63–5.
21. *Mahapatra S, Das BP, Kar A, Das R, Hazra K, Sethy S.* Cavernous hemangioma of uterine cervix in pregnancy mimicking cervical fibroid. *J Obstet Gynaecol India* 2013; 63(4): 288–90.

Received on November 14, 2013.

Revised on May 4, 2014.

Accepted on May 9, 2014.