

## CONGENITAL HEPATIC FIBROSIS

Zorica Raskovic, Biljana Vuletic, Zoran Igrutinovic, Slavica Markovic  
Clinical Centre Kragujevac, Pediatric Clinic

## KONGENITALNA FIBROZA JETRE

Zorica Rasković, Biljana Vuletić, Zoran Igrutinović, Slavica Marković  
Klinički Centar Kragujevac, Pedijatrijska klinika

Received / Priljen: 19.08.2013.

Accepted / Prihvaćen: 06.11.2013.

## ABSTRACT

*Congenital hepatic fibrosis (CHF) is a rare developmental disorder of the portobiliary system and most commonly associated with polycystic kidney disease. The pattern of inheritance of this disorder is autosomal recessive. The exact prevalence of CHF is unknown (estimated from 1:10000 to 1:20000). Sequelae of CHF and portal hypertension have been found in less than half of the all CHF patients and were associated with age.*

*We present a case study of a boy with CHF complicated by portal hypertension, splenomegaly and hypersplenism. This patient was diagnosed with cholestatic syndrome as a neonate. A transcutaneous liver biopsy was performed and repeated at the age of 9 months. Diagnosis of cholestatic syndrome was made based on the findings of a histopathological examination. The ultrasound examination showed polycystic kidneys; however, global renal function remained normal. At the age of 8 years and 6 months, portal hypertension was confirmed by Doppler ultrasonography, and endoscopic examination revealed oesophageal varices of second and third grade, which was also observed in the splenic portography. Thrombocytopenia due to hypersplenism was identified by a platelet count of  $75.2 \times 10^3$ . To prevent variceal bleeding, a splenorenal shunt and a partial spleen resection were performed. The differential of cholestatic syndrome in infants should include CHF. This type of disease may suggest early developing complications of CHF, such as portal hypertension and hypersplenism. Portosystemic shunt surgical treatment is justified in CHF cases with cholestatic syndrome.*

**Keywords:** portal hypertension, hypersplenism, splenorenal shunt

## SAŽETAK

*Kongenitalna fibroza jetre (KFJ) je redak autozomno-recesivni poremećaj razvoja portobilijarnog sistema često udružen sa policističnim promjenama na bubregu. Tačna prevalenca poremećaja nije poznata (procenjuje se na 1: 10 000 do 1: 20 000). Sekvele KFJ i portne hipertenzije se razvijaju u manje od polovine bolesnika tokom vremena.*

*Prikazujemo dečaka sa KFJ komplikovanom portnom hipertenzijom, splenomegalijom i hipersplenizmom. Bolest je prepoznata pod slikomolestaznog sindroma, a dijagnoza bazirana na karakterističnom patohistološkom nalazu pri pregledu tkiva jetre dobijenog perkutanom biopsijom u devetom mesecu po rođenju. Pored toga, ultrasonografskim pregledom nadjene su i policistične promene na bubrezima. Globalna renalna funkcija je bila normalna. Dijagnoza portne hipertenzije je potvrđena Doppler ultrasonografijom, splenoportografijom i endoskopskim nalazom varikoziteta drugog i trećeg stepena u području kardije a hipersplenizma na osnovu trombocitopenije ( $Tr 75,2 \times 10^9$ ). U cilju prevencije krvarenja učinjen je splenorenalni šansa parcijalnom splenektomijom. U diferencijalnoj dijagnoziolestaznog sindroma u dojenačkoj dobi treba razmotriti i KFJ. Ovakav oblik bolesti može karakterisati rana pojava portne hipertenzije i hipersplenizma kao komplikacije. Hirurško lečenje izvođenjem portosistemskog šanta opravdano je u ovim slučajevima.*

**Cljučne reči:** portna hipertenzija, hipersplenizam, splenorenalni šant



## ABBREVIATIONS:

**CHF** - congenital hepatic fibrosis

**KFJ** - kongenitalna fibroza jetre

UDK: 616.36-002.17-053.2 / Ser J Exp Clin Res 2013; 14 (4): 175-179  
DOI: 10.5937/SJECR4339

**Correspondence:** Dr Zorica Raskovic; At work: Pediatric clinic, Clinical Centre "Kragujevac", Zmaj Jovina 30, 34000 Kragujevac, Serbia  
At home: Lepenički bulevar 11/19, 34000 Kragujevac, Serbia  
Tel. at clinic +38134 505174, +38134505175, Fax: +38134370213, Mob. Tel. +381643173246, E-mail: zorica.raskovic0@gmail.com



## INTRODUCTION

Congenital hepatic fibrosis (CHF) is a rare, inherited, autosomal-recessive disease that is characterised by periportal fibrosis with irregularly shaped biliary duct proliferation resulting in intrahepatic portal hypertension and oesophageal varices. The disease is sometimes associated with impaired renal function. Hepatic manifestations of the disease were first described in 1856, and the term “congenital liver fibrosis” was adopted in 1961 [1]. The literature describes a small number of cases; therefore, the incidence and prevalence of CHF are unknown (estimated from 1:10000 to 1:20000) [2]. One quarter of newborns and young infants born with predominant renal disease die [1]. Mortality is attributed to cholangitis [1]. Symptoms of the disease include renal and/or hepatic manifestations. When renal manifestations are dominant, patients develop renal failure that is often fatal. If the lesions of the liver are dominant, the disease manifests as portal hypertension, gastrointestinal bleeding of different intensity and splenomegaly with more or less severe signs of hypersplenism. Haemodynamic consequences of impaired blood flow in the portal vein system include oesophageal varices and varices of the stomach veins proximal to the cardia.

## CASE REPORT

A boy, eight years and 6 months of age with a body height 130 cm (P25) and weight of 27.2 kg (-0.5 kg, - 1.9%), presented with icteric discoloration of the skin and visible mucous membranes and few telangiectatic changes on the face. The sharp, low edge of his liver was palpable approximately 2 cm below the right rib cage and was enormously enlarged. The patient’s spleen was hard and palpable up to 7 cm below the left rib cage. Other physical findings were normal.

Personal anamnesis showed the patient was the first child from a normal, controlled pregnancy, with a birth weight of 3750 g, length of 56 cm and an APGAR score of 10. The patient was regularly vaccinated and fed adapted milk formula from birth. Due to the unclear etiology of conjugated hyperbilirubinemia in the neonatal age, a percutaneous liver biopsy was performed. Histopathological examination showed gigantocellular transformation of hepatocytes and an initial fibrous process with signs of centrilobular cholestasis. Echosonography findings of the extrahepatic biliary tract were normal, while left kidney cystic changes were noted. A percutaneous liver biopsy was repeated at the age of 9 months because of persistent cholestasis. Histopathological examination of the percutaneous liver biopsy confirmed diffuse fibrosis with proliferation of irregular and branched bile capillaries (ductal plate malformation). Abdominal ultrasound and CT examination showed an easily enlarged liver and hyperechoic parenchyma with periodic beaches of normal tissue transonicity. Gallbladder and bile ducts appeared normal.

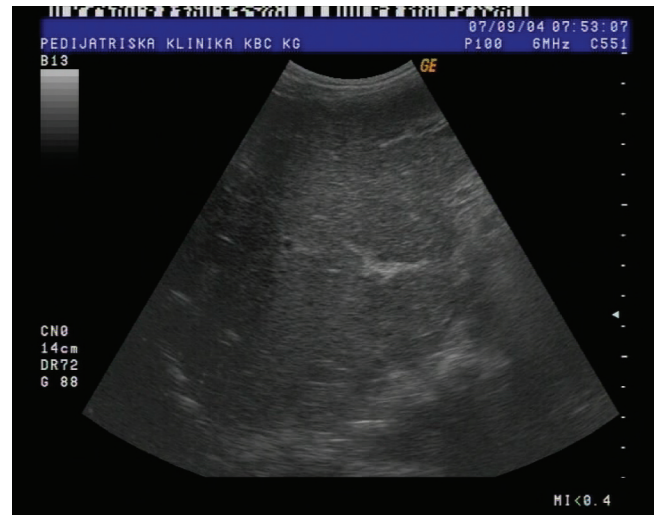

Figure 1. Ultrasound of irregular hepatic structure.

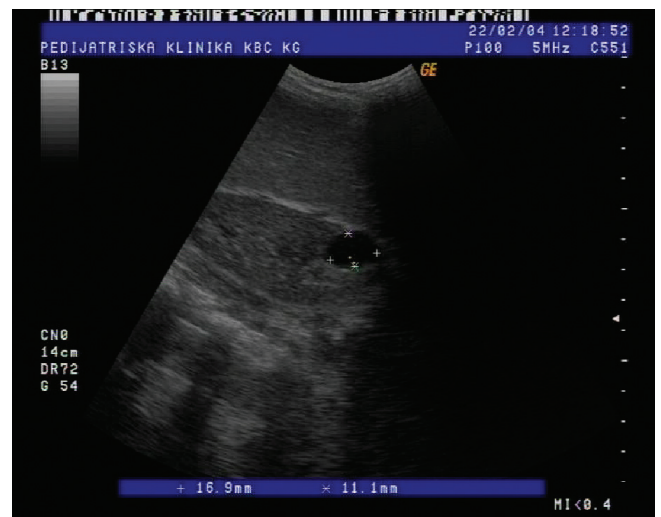


Figure 2. Ultrasound of the left kidney with cysts and large spleen.

Cystic formation was observed in the lower third of the left kidney. Renal function was preserved. In accordance with these findings, and based on the clinical course of the disease, the diagnosis of congenital liver fibrosis was made.

At the time of this visit, laboratory testing found normal levels of ESR and other inflammation markers, normal morphology of red blood cells, a reduced number of platelets ( $75.2 \times 10^3/\text{ml}$ ), proper homeostasis, normal renal function and preserved synthetic and homeostatic liver function. Hepatic lesions were associated with permanent cholestasis confirmed by biochemical markers, including increased levels of liver enzymes AST 204 u/l, ALT 262 u/l,  $\gamma$ GT 513 u/l and alkaline phosphatase 171.1 u/l and a total bilirubin count of 66 mol/l with a conjugated component of 41 mol/l. Based on these findings proximal endoscopy was performed. We found numerous oesophageal varices in the distal third of the oesophagus and cardia inconsistent with signs of reflux esophagitis. Abdominal ultrasound identified an enlarged liver with a pronounced periportal binder and ligaments in echo structure (Figure 1).



Biliary ponds up to 100 mm in the form of cysts were observed peripherally in the liver, and Doppler sonography found the portal vein trunk diameter to be 9.5 mm with a slower hepatofugal blood flow of 10-12 mm/s. The spleen vein was also modified (trunk diameter 8 mm) with multiple tortuous collaterals in the region of the cardia and slower blood flow up to 12 mm/s. The spleen longitudinal diameter was approximately 16 cm (the lower edge reaching almost to the iliac bone). The kidneys were in the correct position without dilatation of the pyelocaliceal system and with cysts of 16.9 x 11.1 mm in diameter on the upper pole of the right kidney (Figure 2).

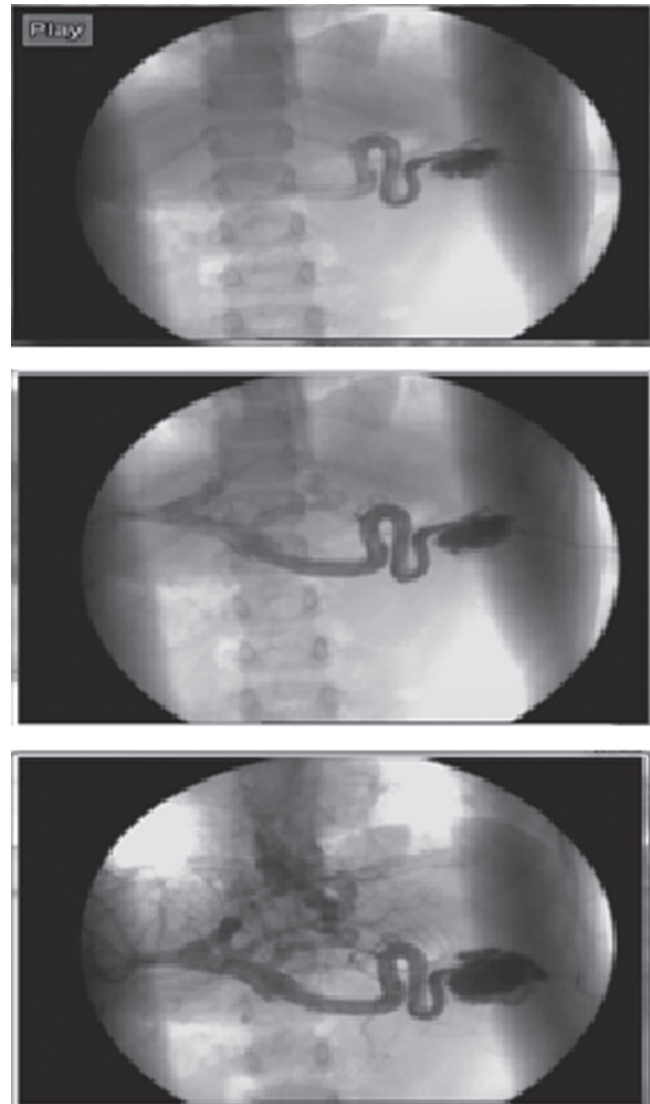
Splenic portography was proposed and confirmed an enlarged spleen and portal vein and displayed retrograde coronary veins with second and third degree varicose changes (Figure 3).

To relieve difficulties in blood flow caused by portal vein hypertension and to reduce the risk of bleeding from oesophageal varicose veins, a splenorenal shunt with partial splenectomy was performed (using the method of Warren (T-L)). The patient was haemodynamically and haemostatic stable. The postoperative course was uneventful. Doppler ultrasonic diagnostic method confirmed normal functioning of the shunt. Two weeks after surgery, platelets showed a significant increase of  $107 \times 10^9/\text{ml}$ , while the laboratory findings were without significant changes compared with previous findings. Throughout the course of the disease, the function of the kidney was preserved. The child was discharged from the hospital in good condition.

## DISCUSSION

Symptoms of congenital liver fibrosis can be manifested in the early infant period, later in childhood and in adolescence. Similarity with other diseases can lead to a delayed or incorrect diagnosis of CLF congenital liver fibrosis. In the initial stage of the disease, a liver biopsy showing diffuse periportal fibrosis and the presence of less than or greater dilation of bile ducts thick bands of fibrous connective tissue are indicative of indicate CLFcongenital liver fibrosis. Although histopathological findings are the gold standard for diagnosis, abnormal hepatic echogenicity and splenomegaly cannot be detected at an early age because the portal fibrosis and portal hypertension develop and progress with age. Hepatomegaly is present in almost all patients presenting with CLFcongenital liver fibrosis[3]. Upon palpation of the liver, the organ is hard; its surface rough and nodular. Ultrasonography greatly aids in diagnosis; finding that echogenicity of the liver tissue is changed, or cystic formation is visible with or without changes in the parenchyma.

Sonographic evaluation includes the Doppler method, with a focus on portal circulation and portal hypertension. With the progression of portal hypertension, the spleen increases and the platelet count decreases due to hypersplenism, developing portosystemic collateral circulation



**Figure 3.** Splenic portography revealed second and third grade oesophageal varices and third grade.

and creating oesophageal and gastric varices. The risk of bleeding increases with the increase in varice size [4, 5, 6]. Variceal bleeding can occur at any age, but is more common in older children and adults. Consequently, endoscopy is indicated in all patients with CHF, especially in those with baseline anaemia and hematemesis. Endoscopic findings confirm the existence of varices, erosions and ulcerations, and facilitate sclerotherapy. Jung and Brancateli use magnetic resonance, i.e., MRCP or magnetic cholecystopancreatography, in the diagnosis of congenital fibrosis of the liver with typical findings of cystic and fusiform dilations of an irregular intrahepatic biliary duct, an abnormally enlarged liver with dilatation of the extrahepatic bile ducts, gall bladder enlargement, and a markedly enlarged spleen with fibrocystic changes in the kidney [7, 8]. Because renal disease is often associated with CHF, many patients are subjected to a renal evaluation. Fonk et al believe that in patients with primary renal failure, liver biopsy is not necessary; therefore, and that diagnosis





can be based entirely on clinical findings [6]. Congenital fibrosis of the liver often causes great differential diagnostic dilemmas. Confusion often causes suspicion of cirrhosis of the liver because it is present in CHF due to extensive hepatic fibrosis and portal hypertension. Non-cirrhotic portal hypertension is more difficult to distinguish from CHF compared with cirrhotic hypertension. Proper diagnosis is based on medical history, clinical findings, laboratory tests and imaging techniques. The most essential difference between CHF and non-cirrhotic portal hypertension is preserved synthetic liver function [9]. Diseases of the bile ducts (primary biliary cirrhosis and primary sclerosing cholangitis) that evolve to liver cirrhosis are extremely rare in children. Both are followed by the significant increase of liver enzymes, alkaline phosphatase and  $\gamma$ GT, which are significantly higher compared with those found in CHF patients and do not have the same visualisation techniques for extra testing [10]. Cystic changes in the liver and in primary biliary cirrhosis antimitochondrial antibodies were not found in any of these diseases. The similarity of CHF with primary sclerosing cholangitis is a phenomenon ascending cholangitis, and sometimes biliary strictures and dilatation, which is seen in primary sclerosing cholangitis, may be misinterpreted and represent the dilated extrahepatic bile ducts or even intrahepatic cysts in CHF. Other causes of cirrhosis, such as viral hepatitis, autoimmune hepatitis, alpha 1 antitrypsin deficiency and Wilson's disease are excluded on the basis of history and laboratory tests. Special attention in the examination of patients may identify liver cysts, which can create further differential diagnostic dilemmas. If liver cysts are observed in autosomal dominant polycystic liver disease, the cysts can lead to portal hypertension but are not typical of CHF, as they vary across a range of time and occupy a substantial part of the liver parenchyma [11,12]. Macroscopic cysts of the liver, in continuity with the biliary ducts, are a typical and very common finding among patients with CHF and are indicative of Caroli's Syndrome. Almost all rare cases of isolated forms of CHF occur without Caroli's Syndrome. The genes responsible for these isolated forms of CHF are unknown. The results of genetic engineering have shown that most infants with the severe perinatal form of diseased CHF associated with Caroli's Syndrome have two mutations in the PKHD1 gene, and the majority of survivors in the neonatal period have at least one mild mutation [13]. This syndromic phenomenon certainly should be distinguished from congenital liver disease (Caroli's Syndrome), which is characterised by cystic dilatation of only the intrahepatic bile ducts [14]. Congenital hepatic fibrosis is a disease for which there is no specific therapy to repair the primary ductal plate malformation or to recover fibrotic changes and abnormalities of the biliary tree. Pharmacological treatment with antibiotics is indicated only in cases of cholangitis. Portal hypertension and oesophageal varices require a special type of treatment. Primary prevention (before the onset of bleeding) includes giving non-selective beta-blockers, in accordance with the measured

pulse and blood pressure. Secondary prevention of bleeding varices (in case the bleeding has already happened) requires banded ligation and sclerotherapy. A portosystemic shunt surgical intervention has the least side effects and contraindications [15,16]. Alvares et al describe a population of 27 children with CFL in which a portosystemic shunt was performed in 16 patients aged 3-16 years [17]. During a 3 month to 12 year follow-up, liver functioning did not worsen, and signs of hepatic encephalopathy were absent. Prognosis is, in fact, considerably better in the infantile form of the disease [18]. Consideration of the need for surgery (portal system shunt) in a patient who has never had bleeding from varices may be reasonable if the portal hypertension gets progressively weaker and threatens the liver synthetic function. The use of a surgical shunt may also be considered for patients who did not have episodes of bleeding when there is no possibility of emergency response and safe, secure care if bleeding occurs. Our patient had never bled from oesophageal varices, although they were third degree. In line with potential risk, and to prevent serious complications, the splenorenal shunt method was selected with a minimum of contraindications. Therefore, the increase in the degree of varices was prevented, and the possibility of bleeding was reduced to a minimum. Further monitoring of the patient involved the analysis of synthetic, homeostatic and haemostatic liver function, cholestasis and renal function control as well as oesophageal varices condition.

## ACKNOWLEDGMENTS

The authors would like to thank Prof Dr Nedeljko Radlovic for significant assistance. The authors would also like to thank the University Children's Hospital of Belgrade surgical team, including Prof Dr Zoran Krstic, Ass Dr Aleksandar Sretenovic, and the radiologists Prof. Ddr Dragan Sagic, Dr Zeljko Smoljanic, and the clinicians from the Institute for Mother and Child's Health in Belgrade who performed the initial liver biopsy.

## REFERENCES

1. Nazer H. Nazer, D. Congenital Hepatic Fibrosis. Available on <http://www.eMedicine.com/ped/topic459.htm>, taken 23.01.2010.
2. Meral Gunaz-Aygin, William A. Gahi, Theo Heller. Congenital Hepatic Fibrosis Overview. Gene Reviews; 2008. Available on : <http://www.ncbi.nlm.nih.gov/bookself/book=gene&part=hepatic-fibrosis>, taken 27.01.2010.
3. Vuletic B, Radlovic N, Lekovic Z, Sretenovic A, Krstic Z, Smoljanic Z, Raskovic Z. Congenital Fibrosis of the Liver. Pediatric days in Serbia and Montenegro; September 2004. ; Nis; 172-177 (in Serbian)
4. Kerr DN, Okonkwo S, Choa RG. Congenital hepatic fibrosis: the long-term prognosis. Gut 1978;19 :514-20.



5. Summerfield JA, Nagafuchi Y, Sherlocks S, Canafalch J, Schaefer PJ. Hepatobiliary fibropolycystic disease: a clinical and histological review of 51 patients. *J Hepatol.* 1986;2:141-156.
6. Fonk C, Chauveau D, Gagnadoux MF, Pirson Y, Grunfeld JP. Autosomal recessive polycystic kidney disease in adulthood. *Nephrol Dial Transplant.* 2001;16:1648-52.
7. Jung G, Benz-Bohm G, Kuge IH, Keller KM, Querfeld U. MR cholangiography in children with autosomal recessive polycystic kidney disease. *Pediatr Radiol.* 1999;29:463-6.
8. Brancatelli G, Federie MP, Vilgrain V, Vullierme MP, Marin D, Lagalla R. Fibropolycystic liver disease; CT and MR imaging findings. *Radiographics.* 2005;25:659-70.
9. Sarin SK, Kumar A. Noncirrhotic portal hypertension. *Clin Liver Dis.* 2006; 10:627-51.
10. Kumagait, Alswat K, Hirschfeld GM, Heathcote J. New insights into autoimmune liver diseases. *Hepatol Res.* 2008;38:745-61.
11. Demetrio Tamiolakis, Panagiotis Prassopoulos, Athanasia Kotini, Kiriaki Avgidou, Constatine Simopoulos and Nikola Papadopoulos. Intrahepatic cystic disease with congenital fibrosis (Caroli's complex disease). A case report and review of the literature. *Acta Clin Croat.* 2003;42:233-236.
12. Drenth JP, Martina JA, Van de Kerkhof R, Bonifacino JS, Jansen JB. Polycystic liver disease is a disorder of contralateral protein processing. *Trends Mol Med.* 2005;11:37-42.
13. Bergmann C, Flegauf M, Bruchie NO, Frank V, Olbrich H, Kirchner J et al. Loss of nephrocystin-3 function can cause embryonic lethality, Meckel-Gruber like syndrome, situs inversus, and renal-hepatic-pancreatic dysplasia. *J Am Soc Nephrol.* 2003;14:76-89.
14. Caroli J. Diseases of the intrahepatic biliary tree. *Clin Gastroenterol.* 1973;2:147-161.
15. Bosh J, Berzigotti A, Garcia-Pagan Abraldes JG. The management of portal hypertension: rational basis, available treatments and further options. *J Hepatol.* 2008;48:S68-9.
16. Schneider BL, Magid MS. Liver diseases in autosomal recessive polycystic kidney disease. *Pediatr. Transplant.* 2005;9:634-9.
17. Alvarez F, Bernard O, Brunelle R et al. Congenital hepatic fibrosis in children. *J Pediatr.* 1981;99:370.
18. Riviero MJ, Roman E, Cilleruel ML, Sanchez E, Barrio. Caroli's syndrome. Report of case beginning in childhood with favorable course. *An Esp Pediatr.* 2000;53:59-61 JC.